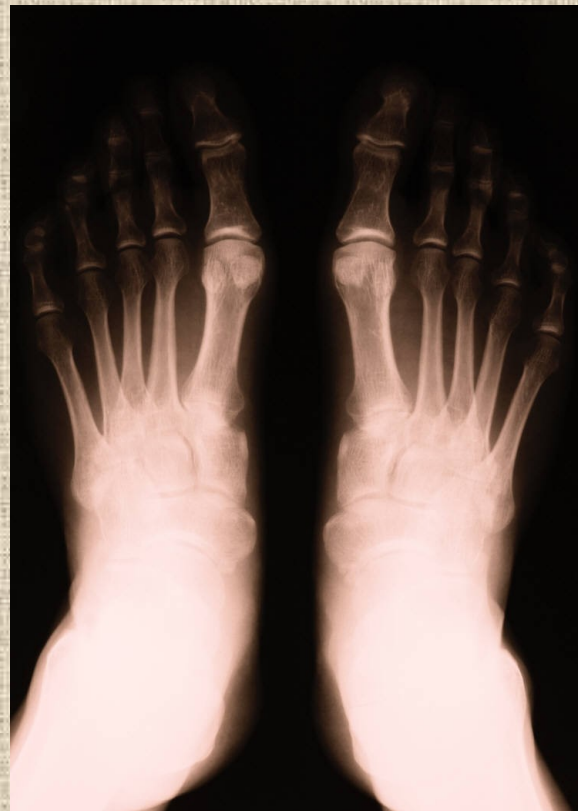

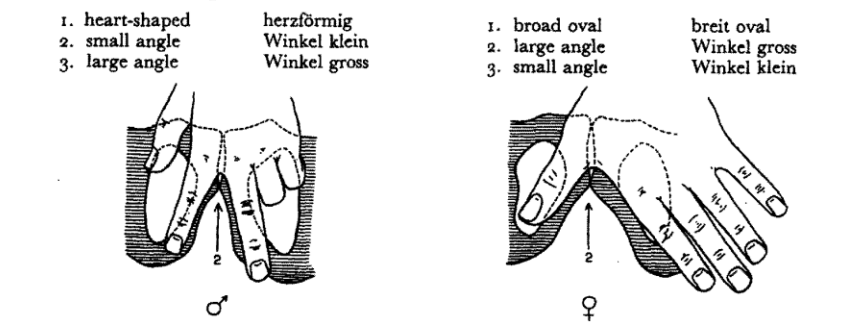
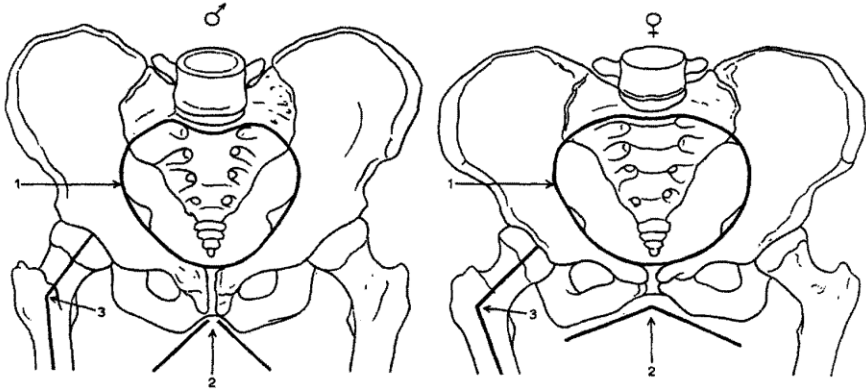
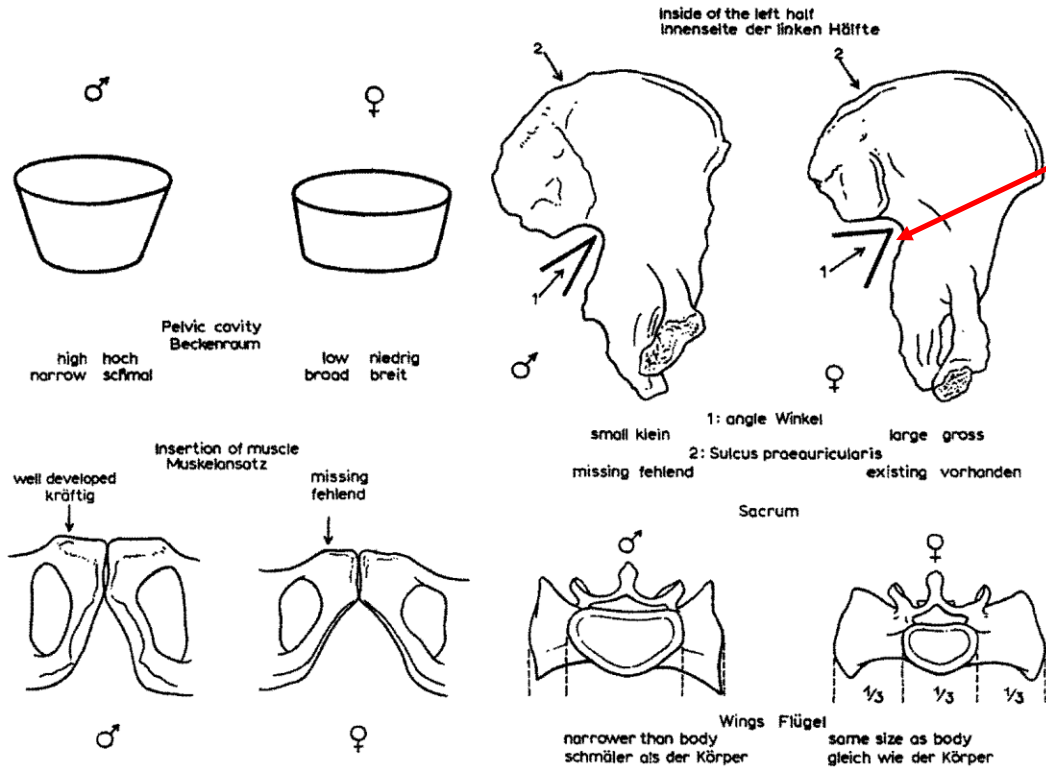
# Základy osteologie

Pánev a kosti zadní končetiny

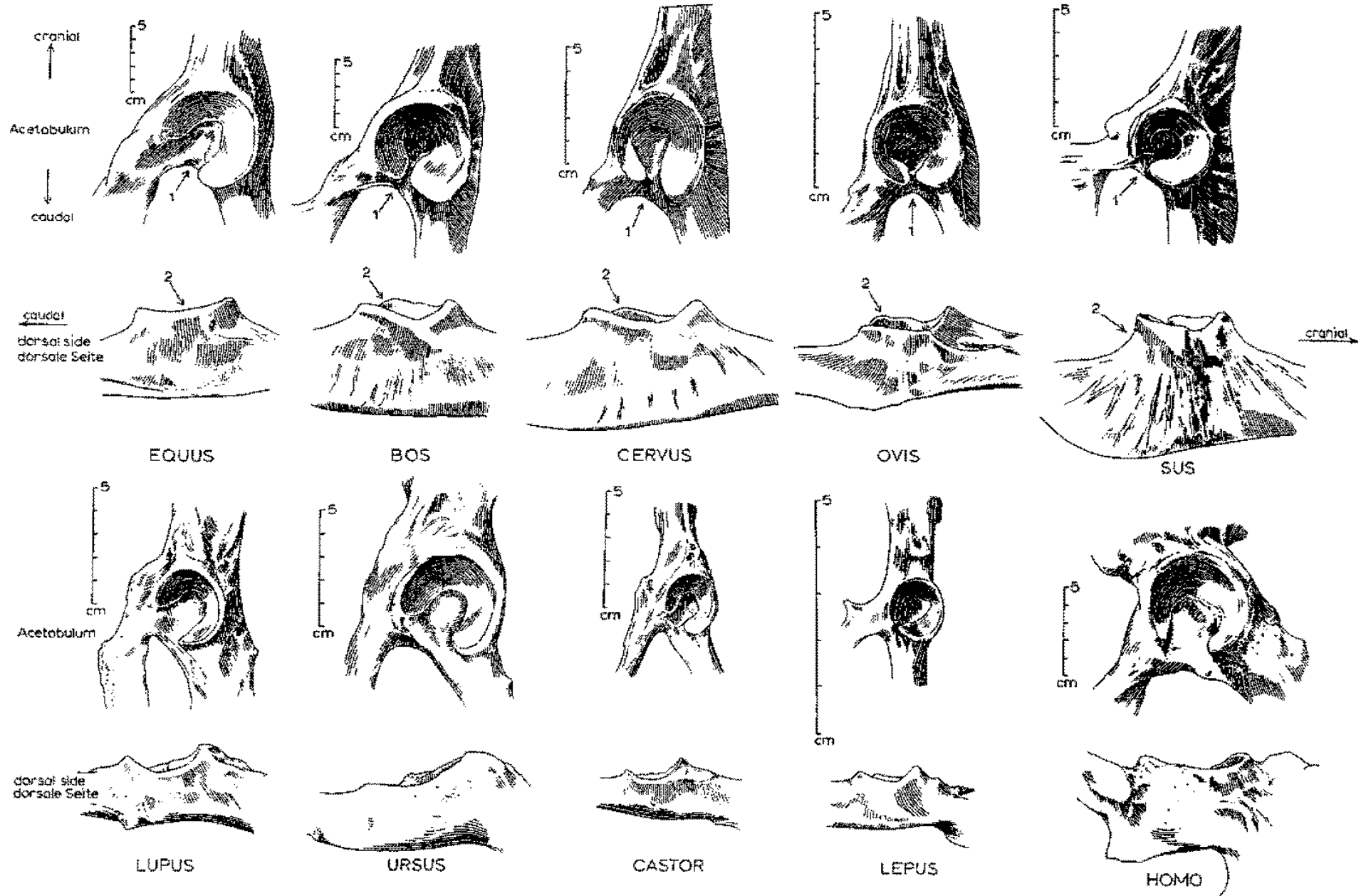


*Incisura ischiadica major*

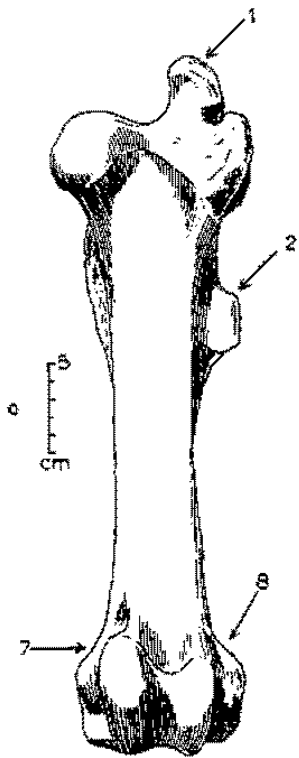
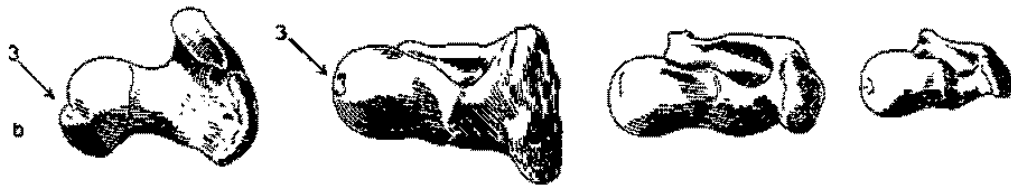
**Pohlavní rozdíly na pánvi člověka**



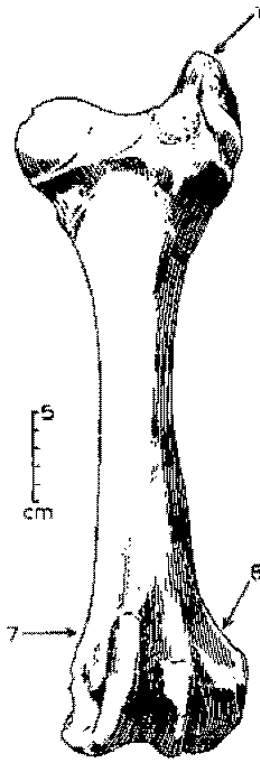
# Pánve



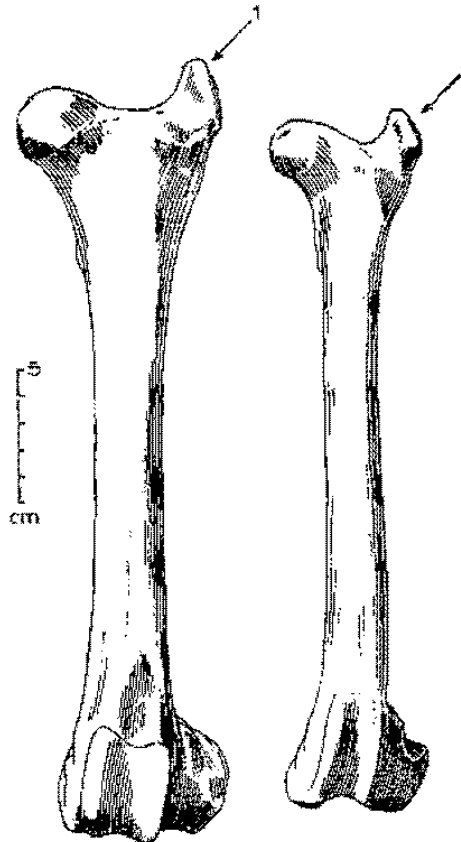
# Stehenní kosti (*femur*)




EQUUS



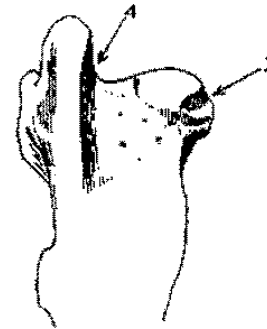
BOS



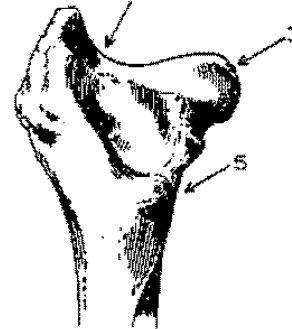
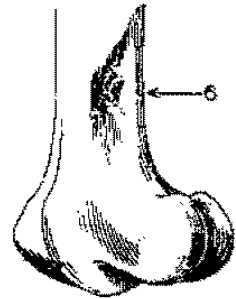
CERVUS



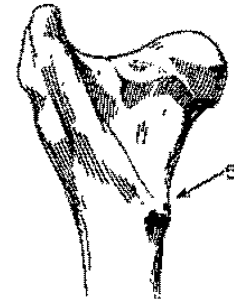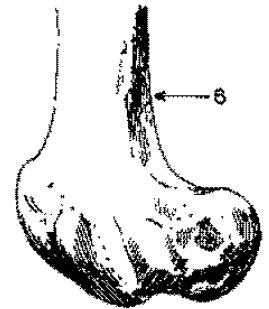
OVIS



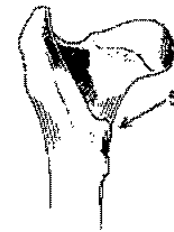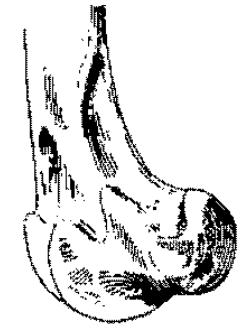
EQUUS



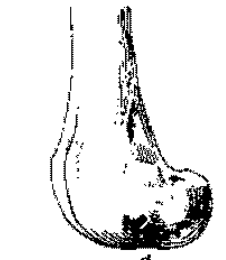
BOS



CERVUS



cm



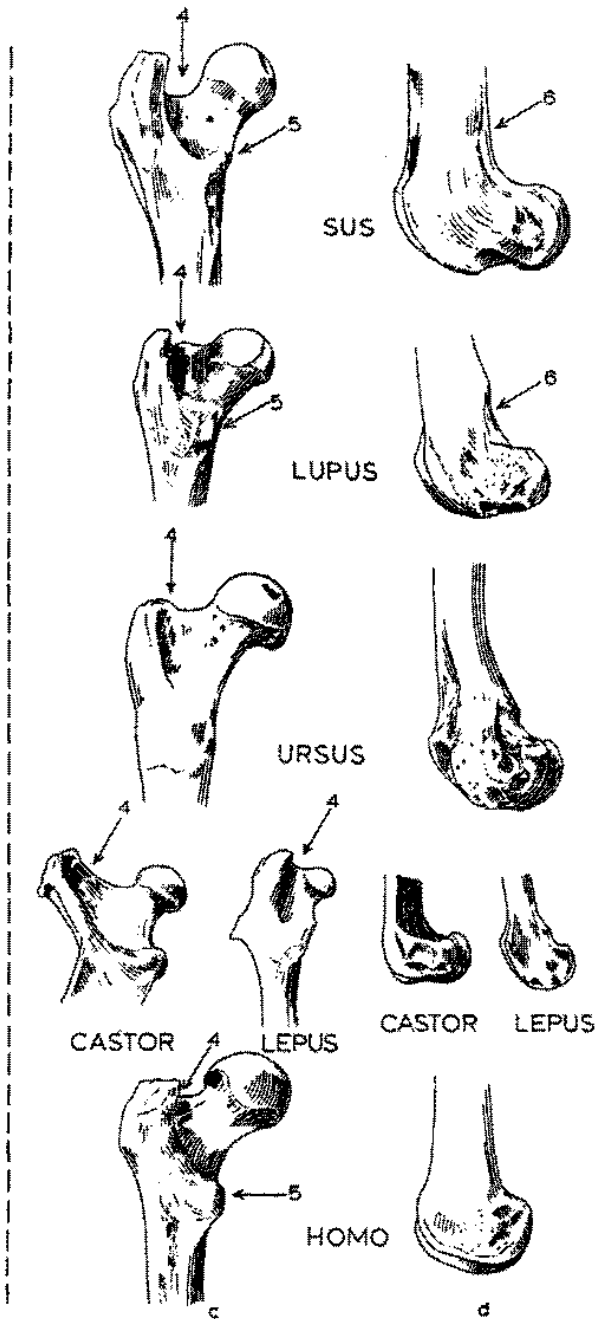
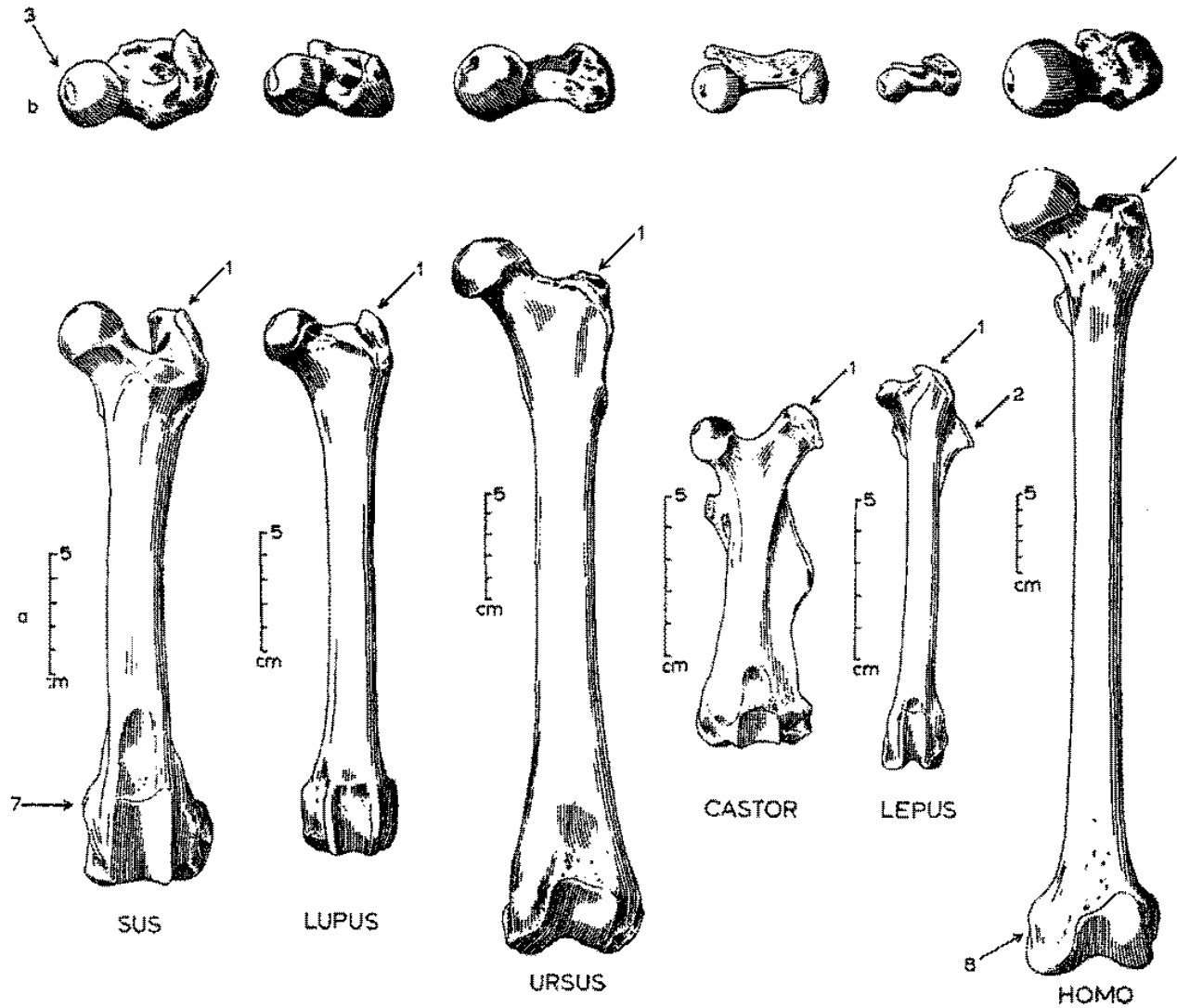
OVIS

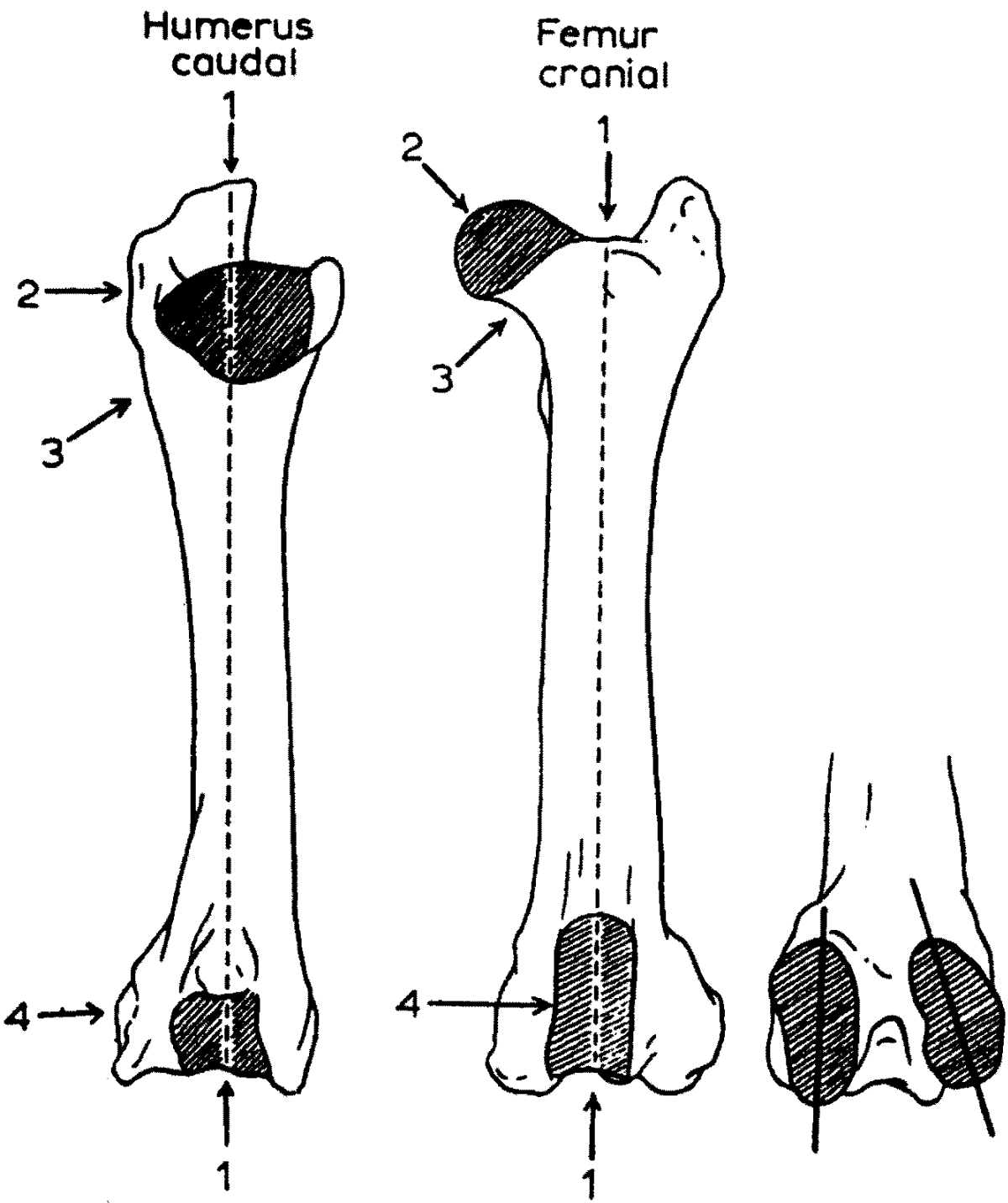
c

d



# Stehenní kosti (femur)

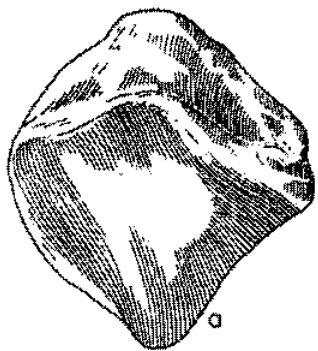




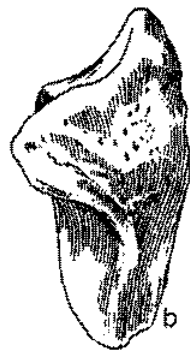**Jak rozeznat stehenní**  
**a pažní kost**




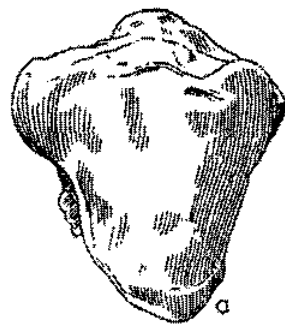
# Češka (*patella*)



EQUUS



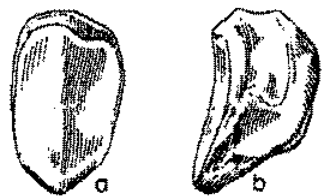
BOS



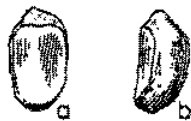CERVUS



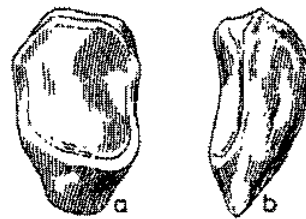
OVIS



SUS



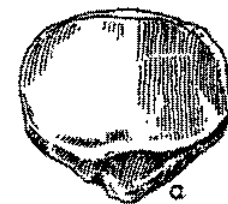
LUPUS



URSUS



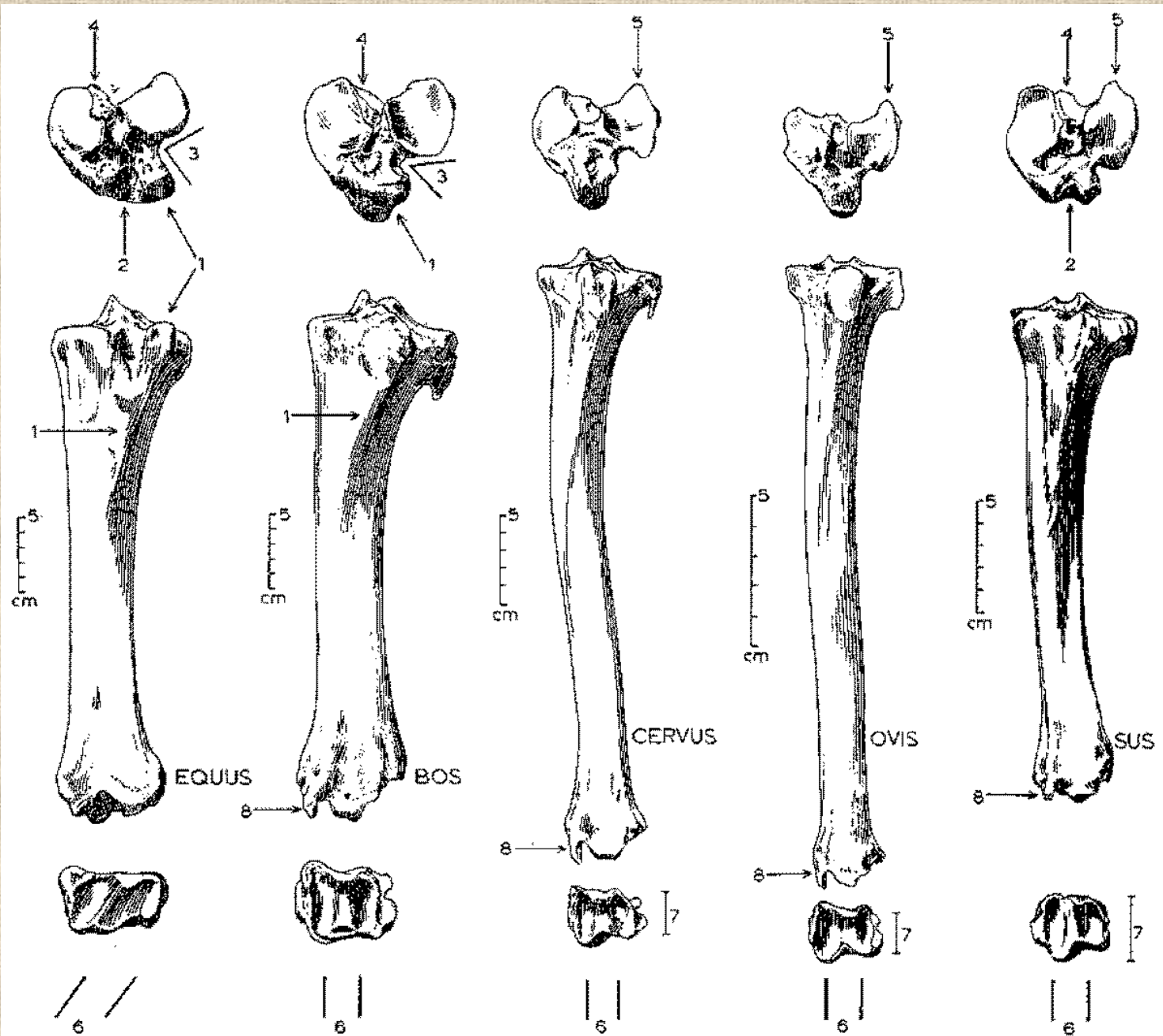
CASTOR



HOMO

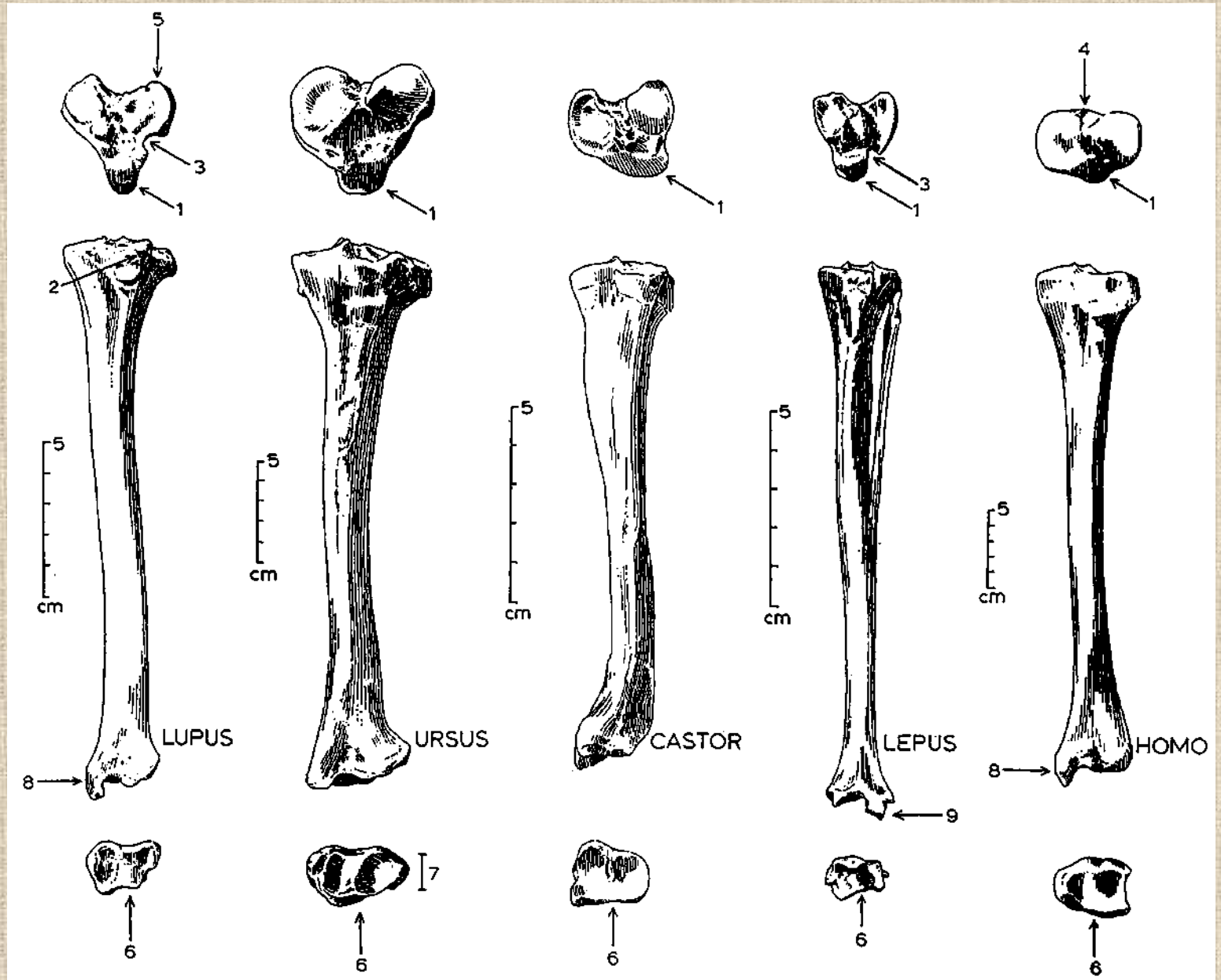


# Holenní kosti (*tibiae*)

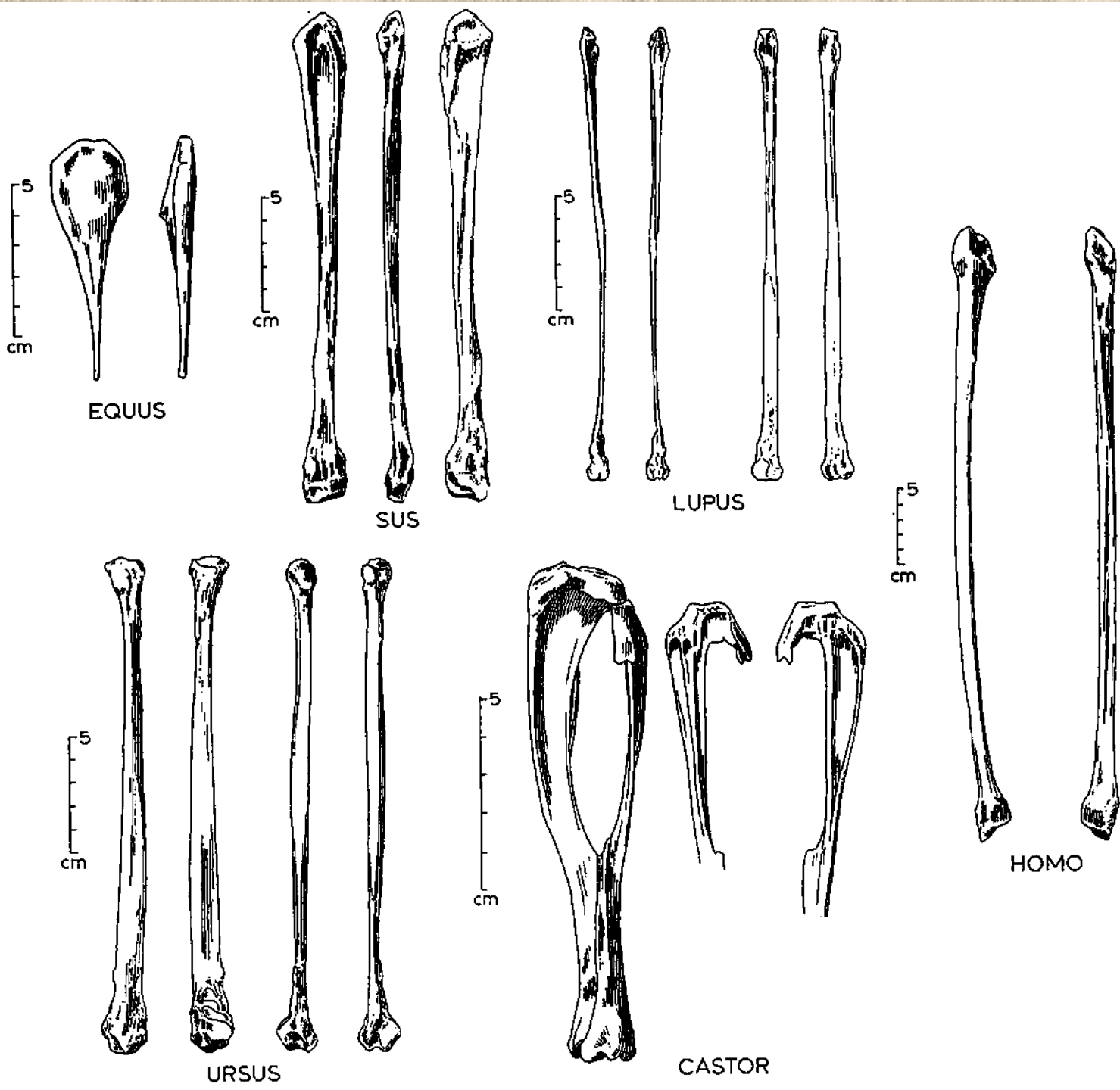




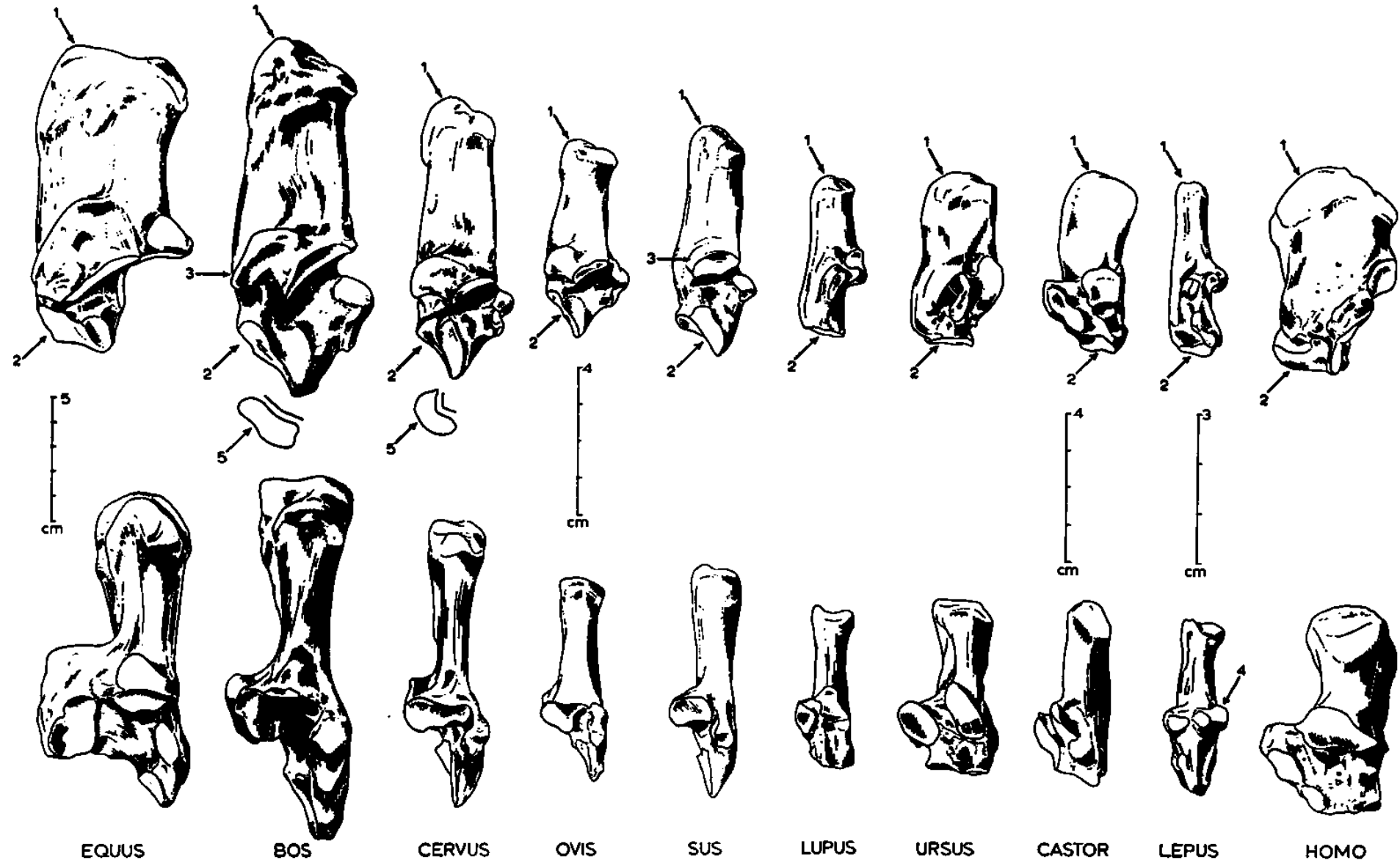
# Holenní kosti (*tibie*)

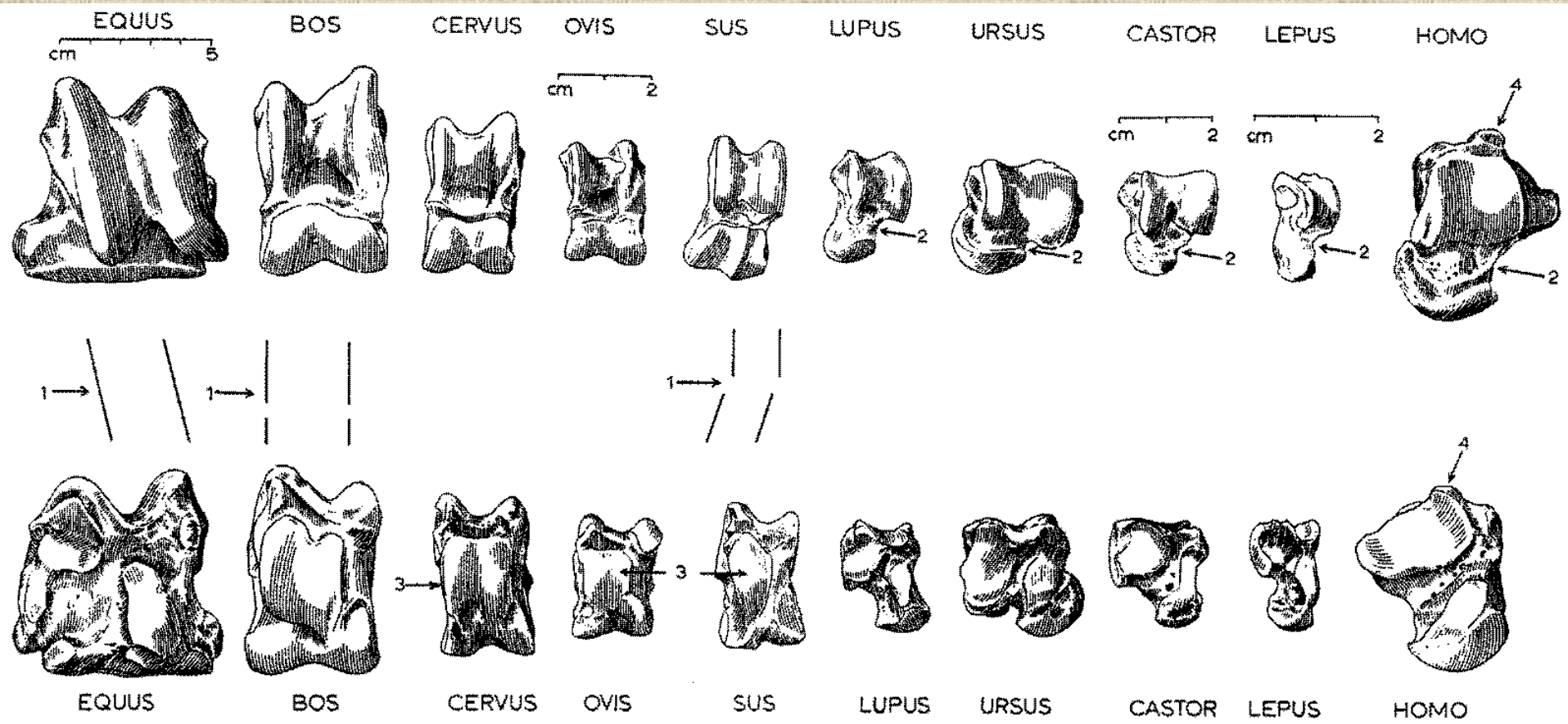


Lýtkové  
kosti  
(fibula)



# Kost patní (*calcaneus*)

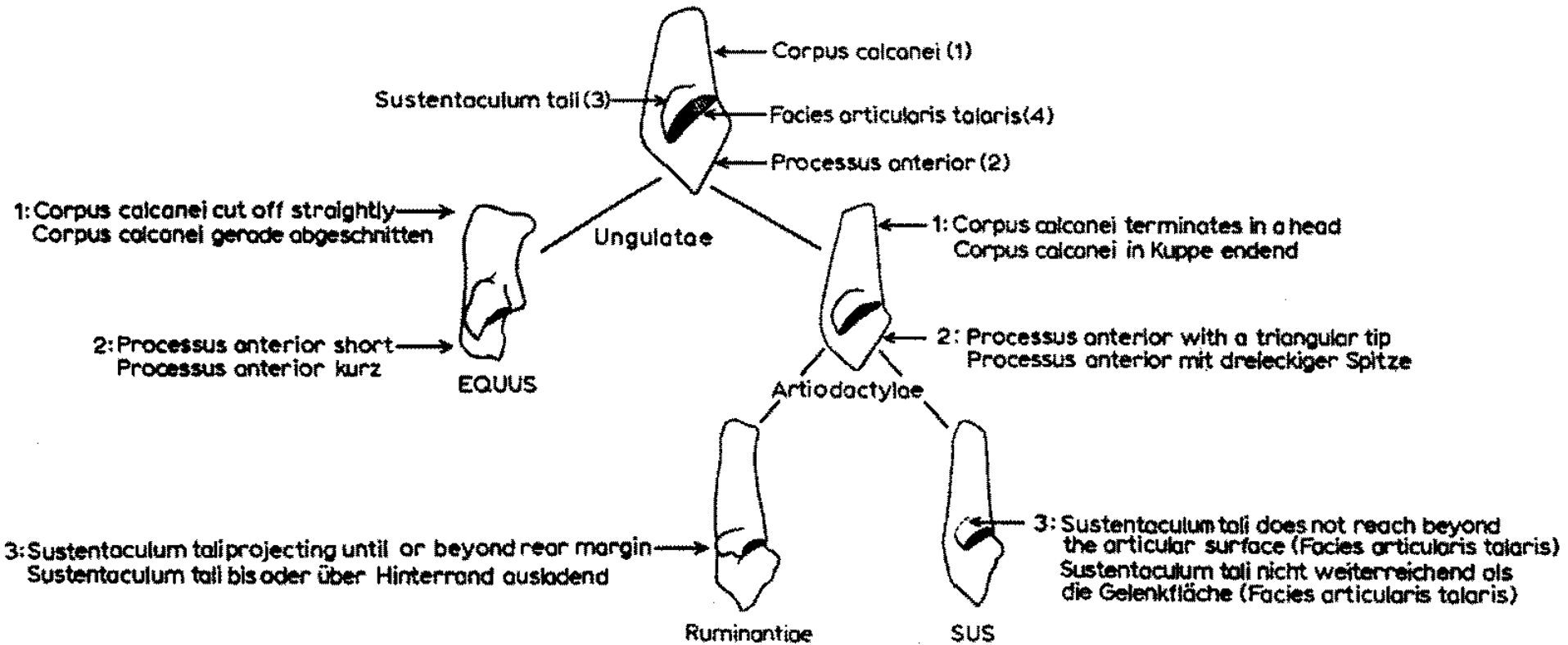




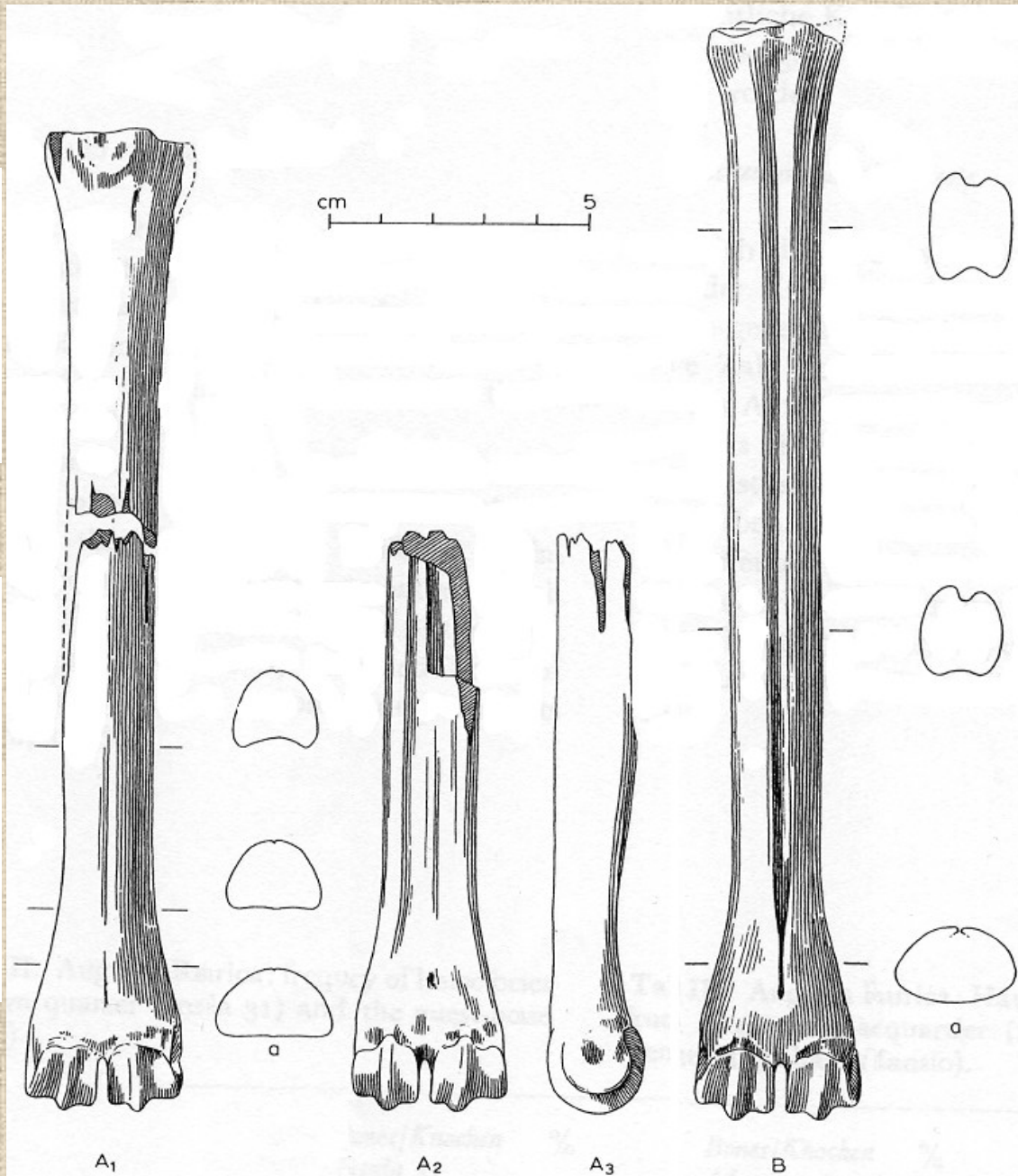
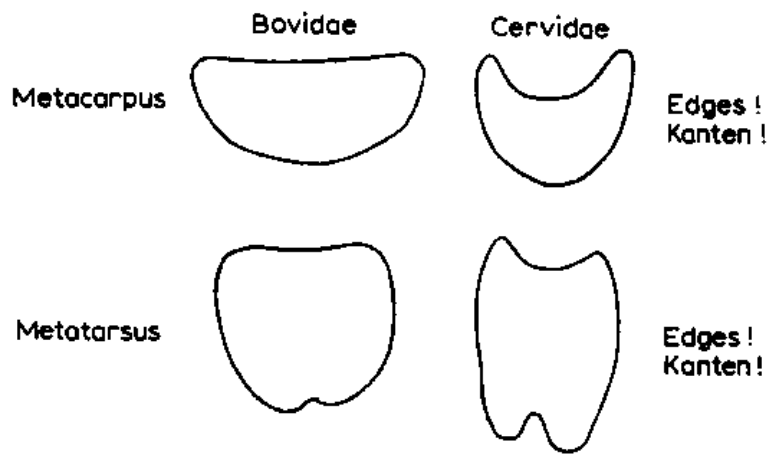
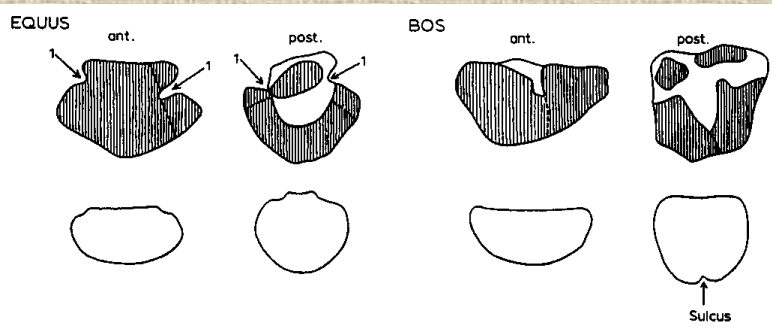
## Kost hlezenní (*astragalus*)



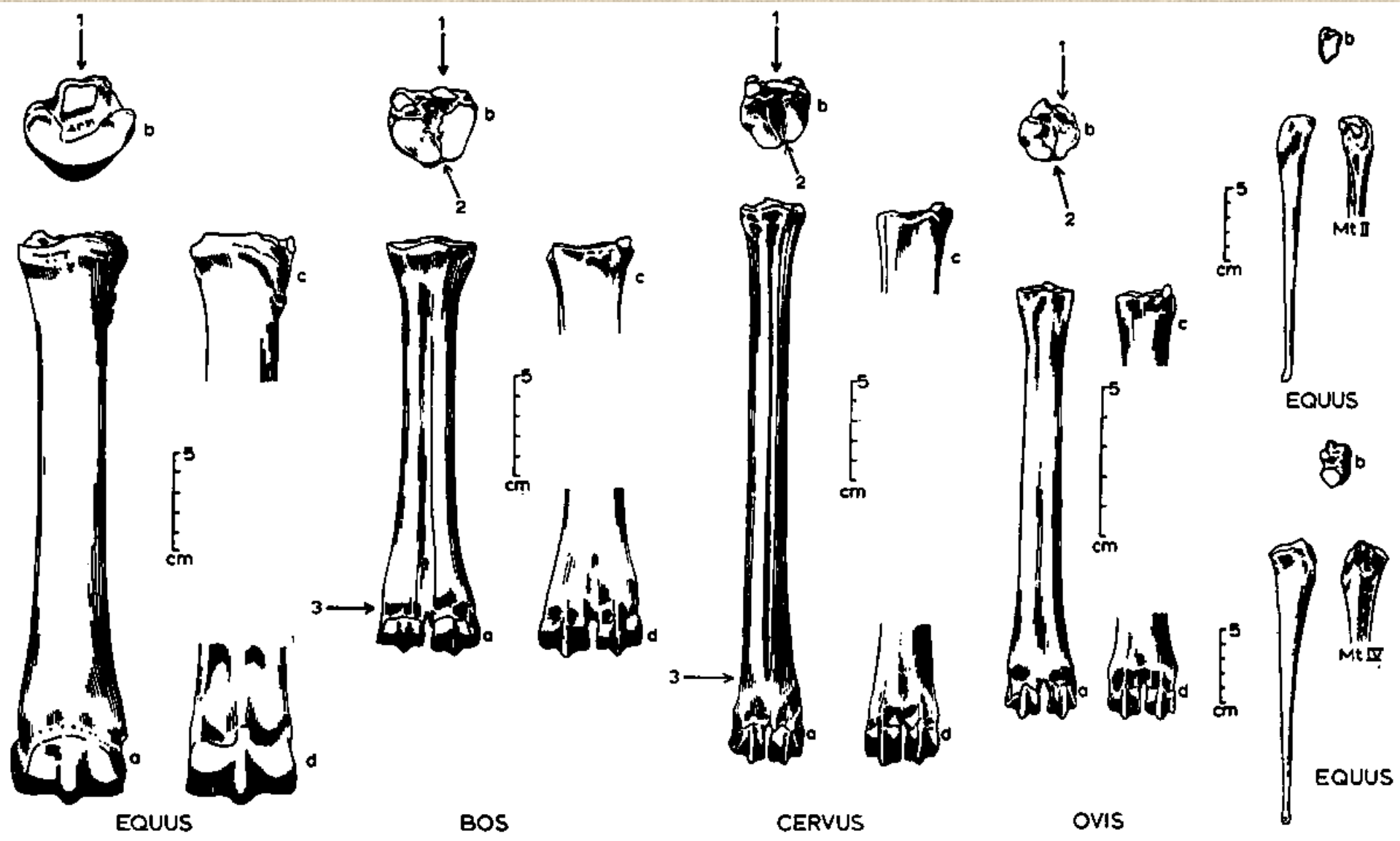
# Rozdíly mezi kostmi patními býložravců a masožravců



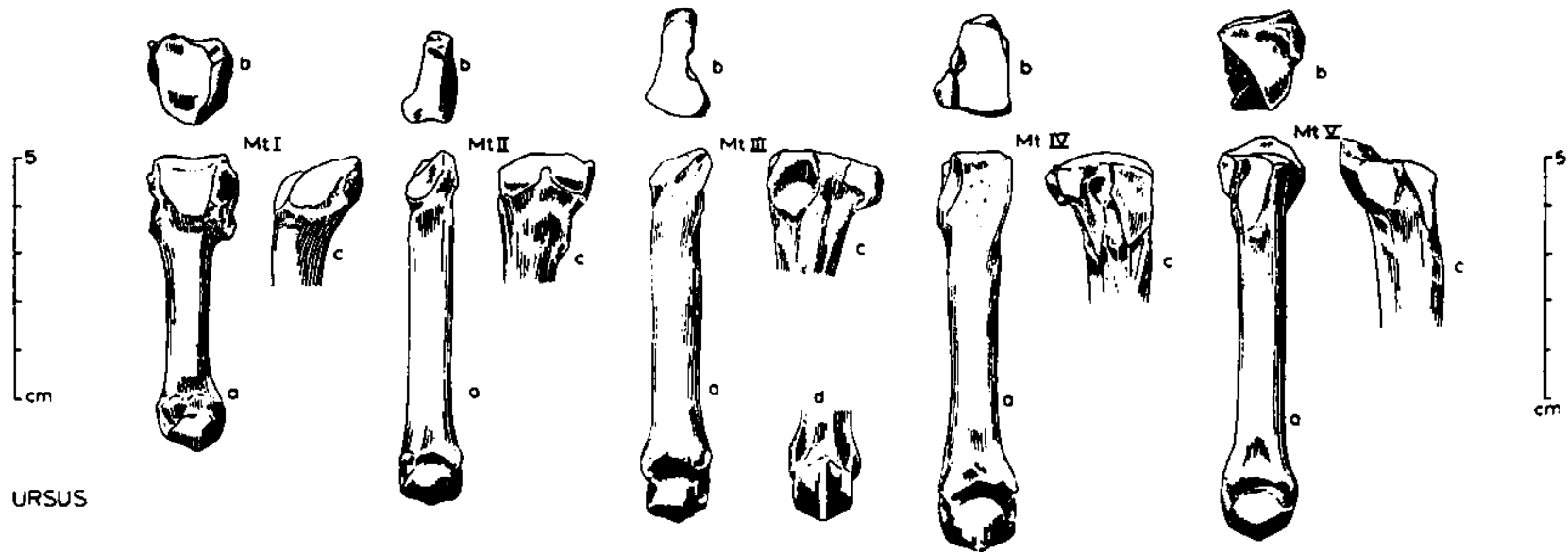
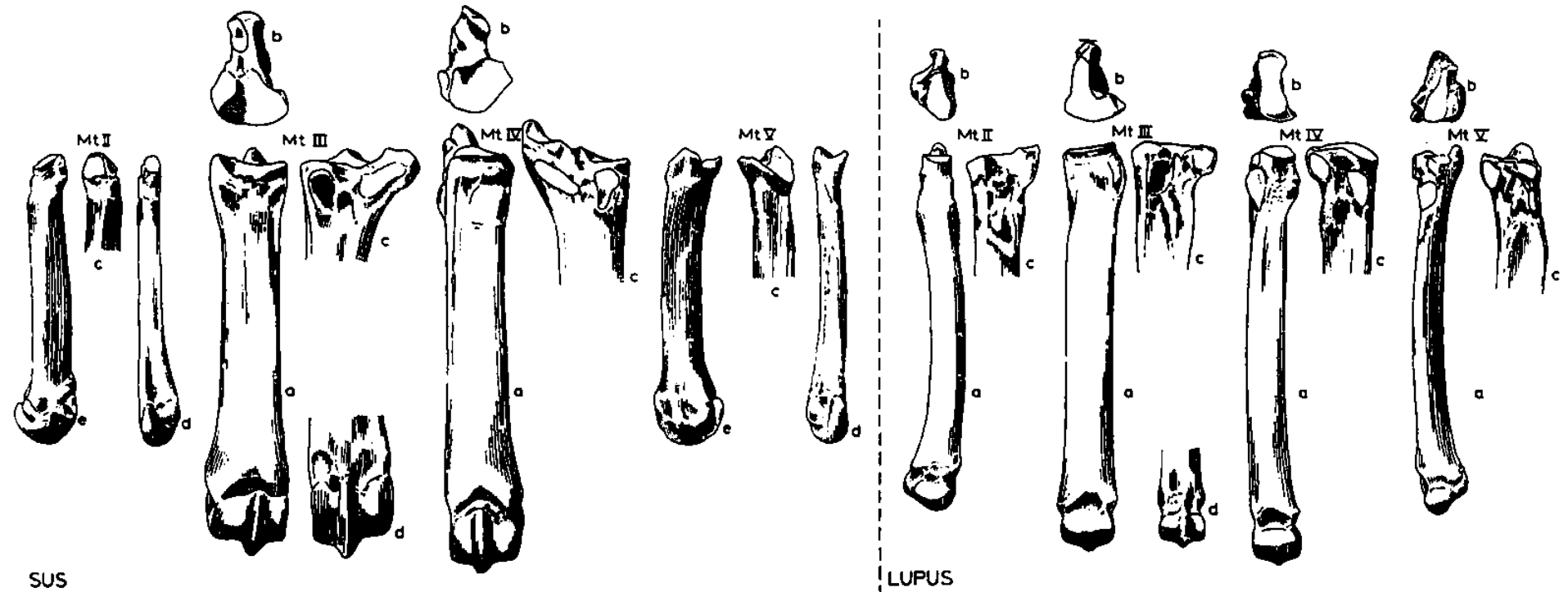
# Rozdíl mezi záprstními a nártními kostmi



# Nártní kost (*metatarsus*)

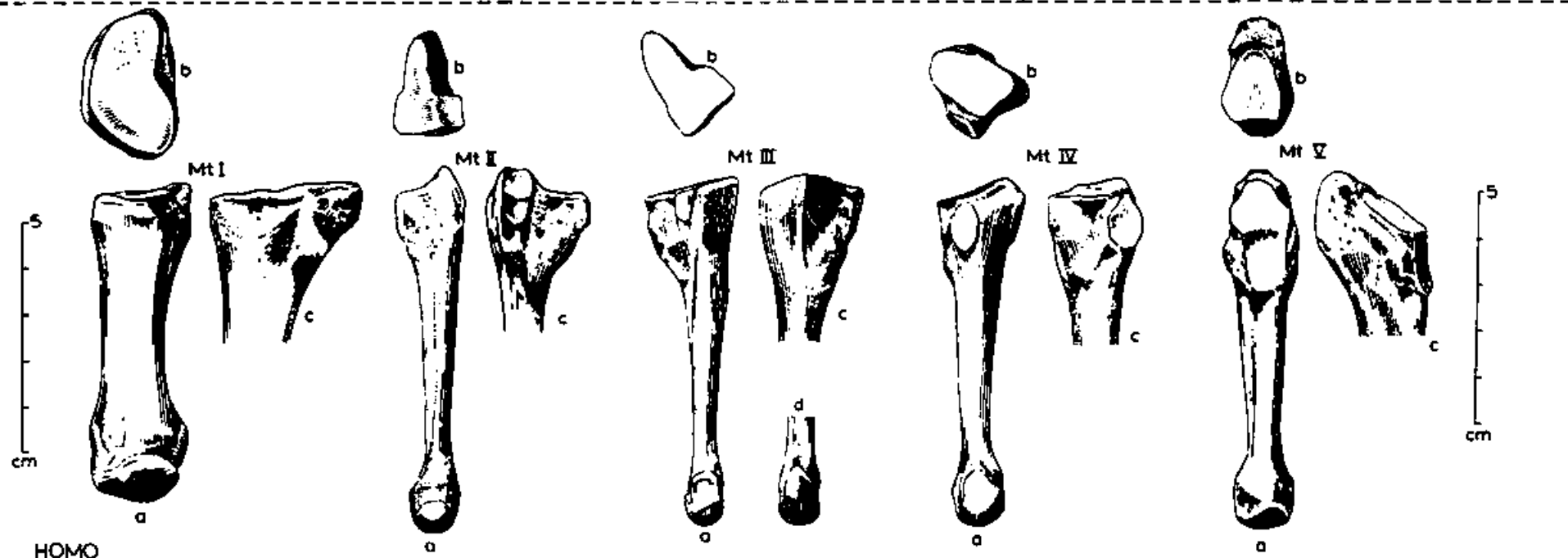
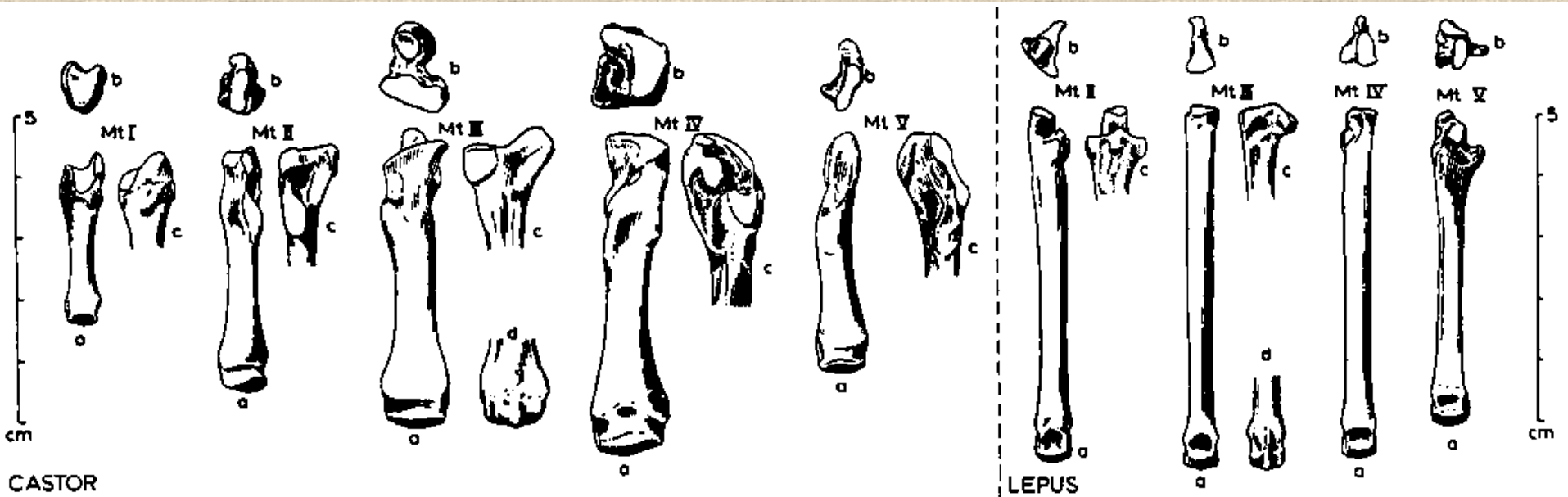


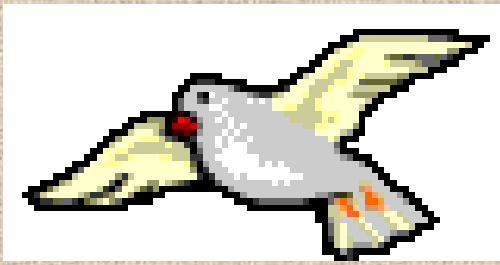# Nártní kost (*metatarsus*)



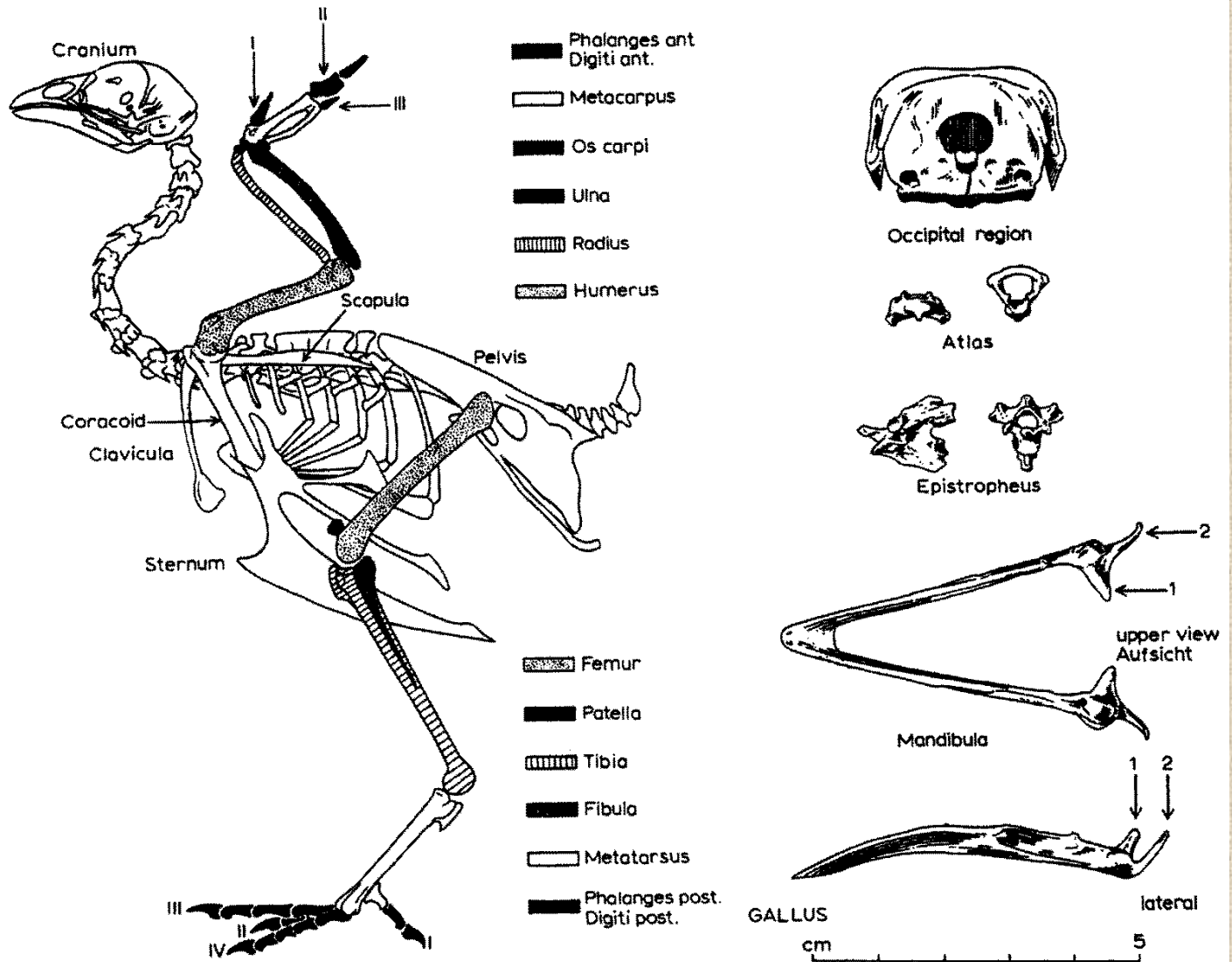


# Nártní kost (*metatarsus*)

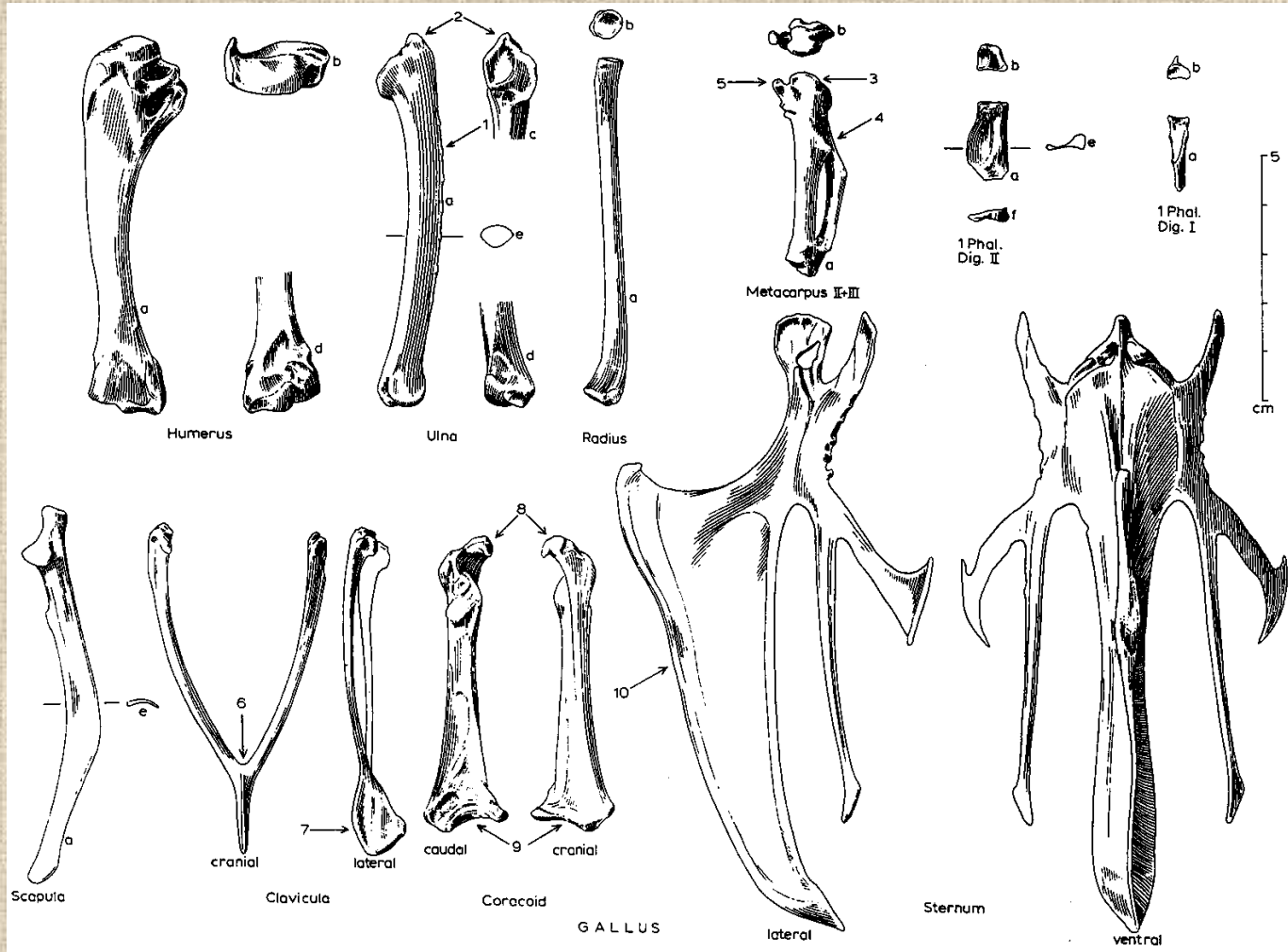




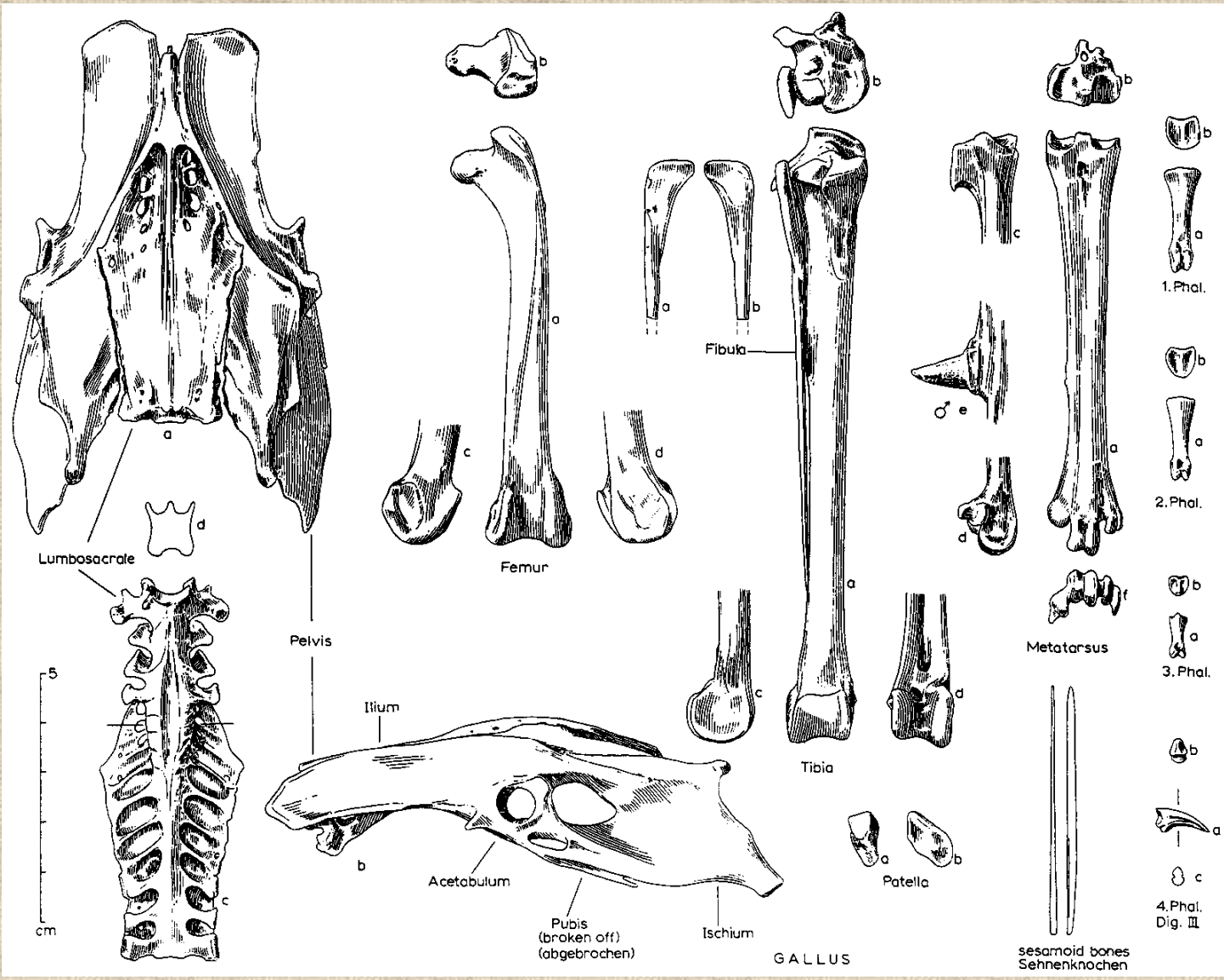
# Ptačí kostra



# Kostra přední končetiny ptáka

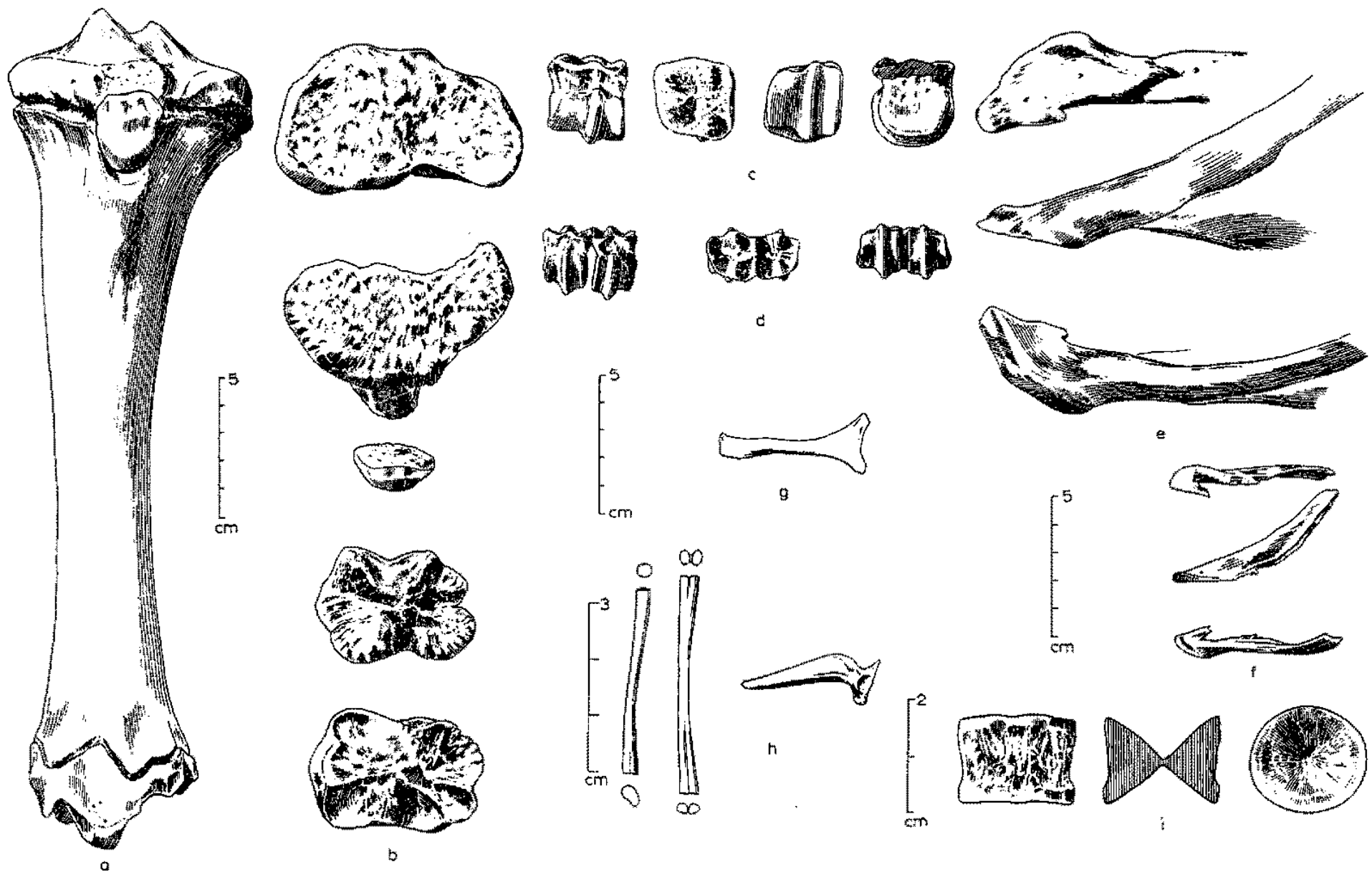


# Kostra zadní končetiny ptáka





# Rozdílná morfologie kostí různých druhů zvířat





**Děkuji za pozornost!**