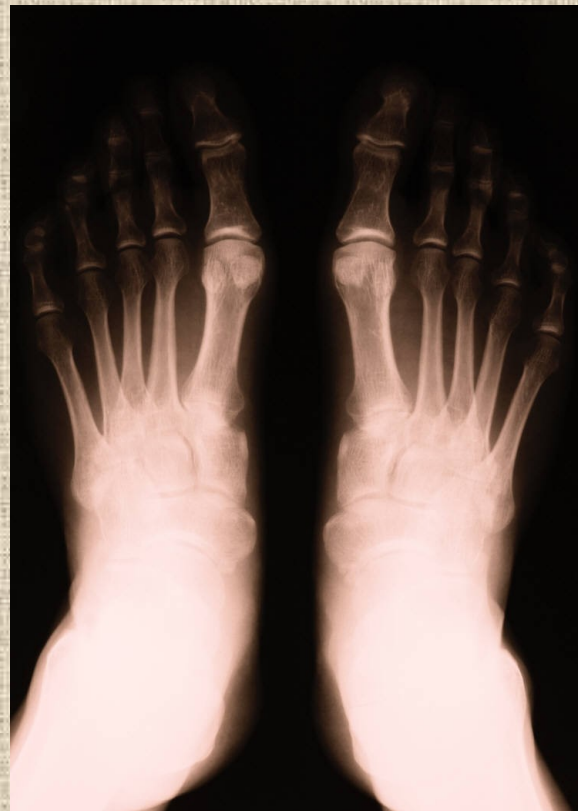

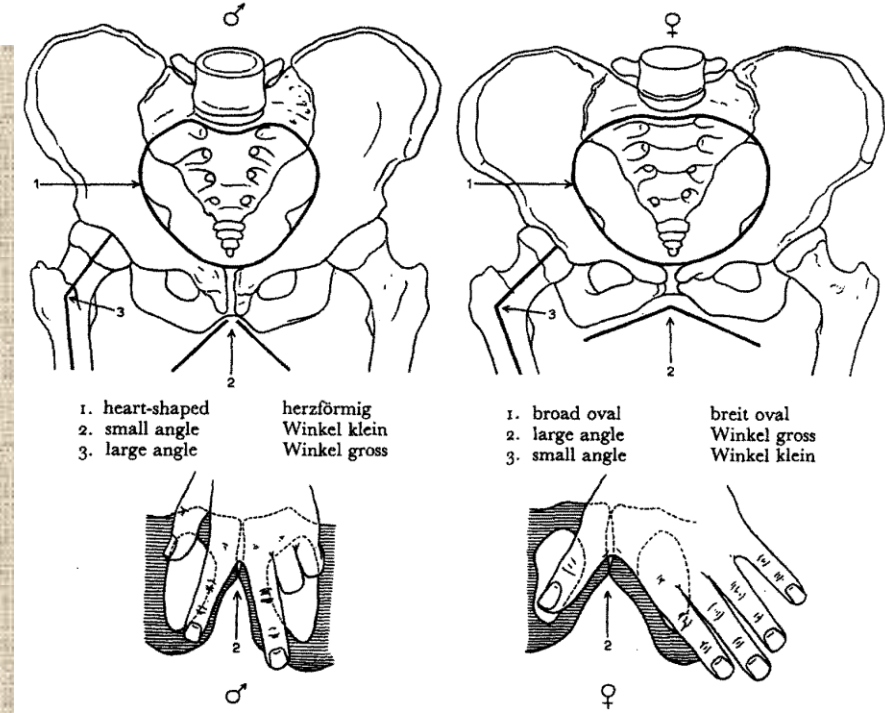
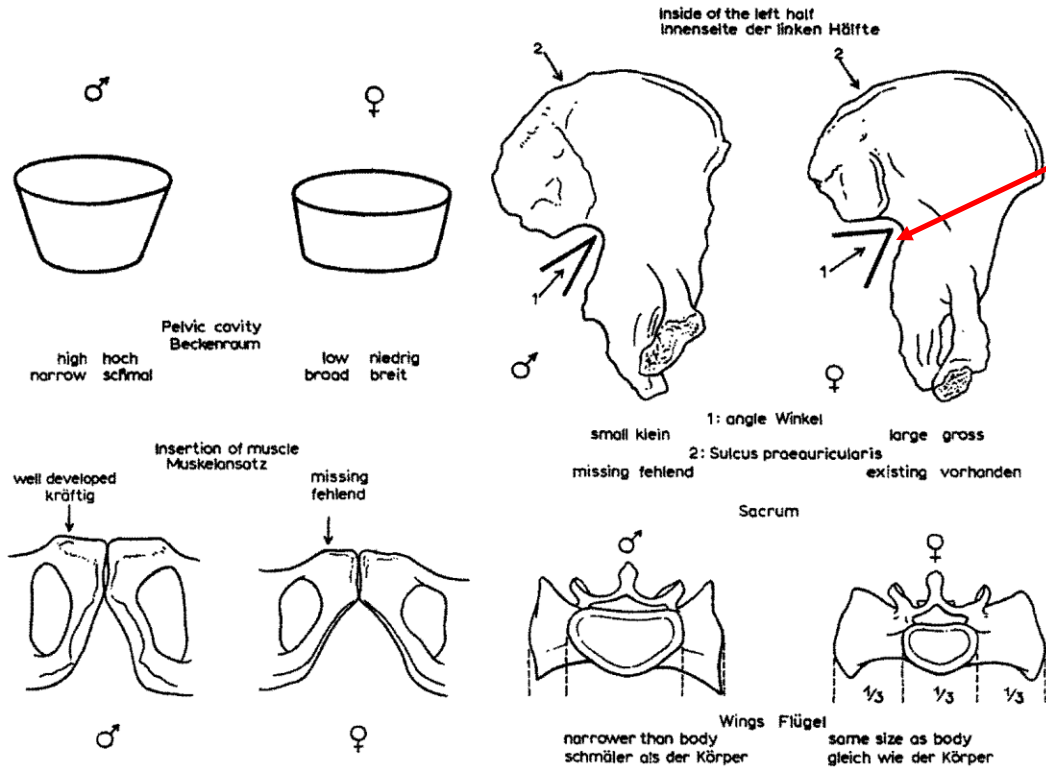
Základy osteologie

Pánev a kosti zadní končetiny

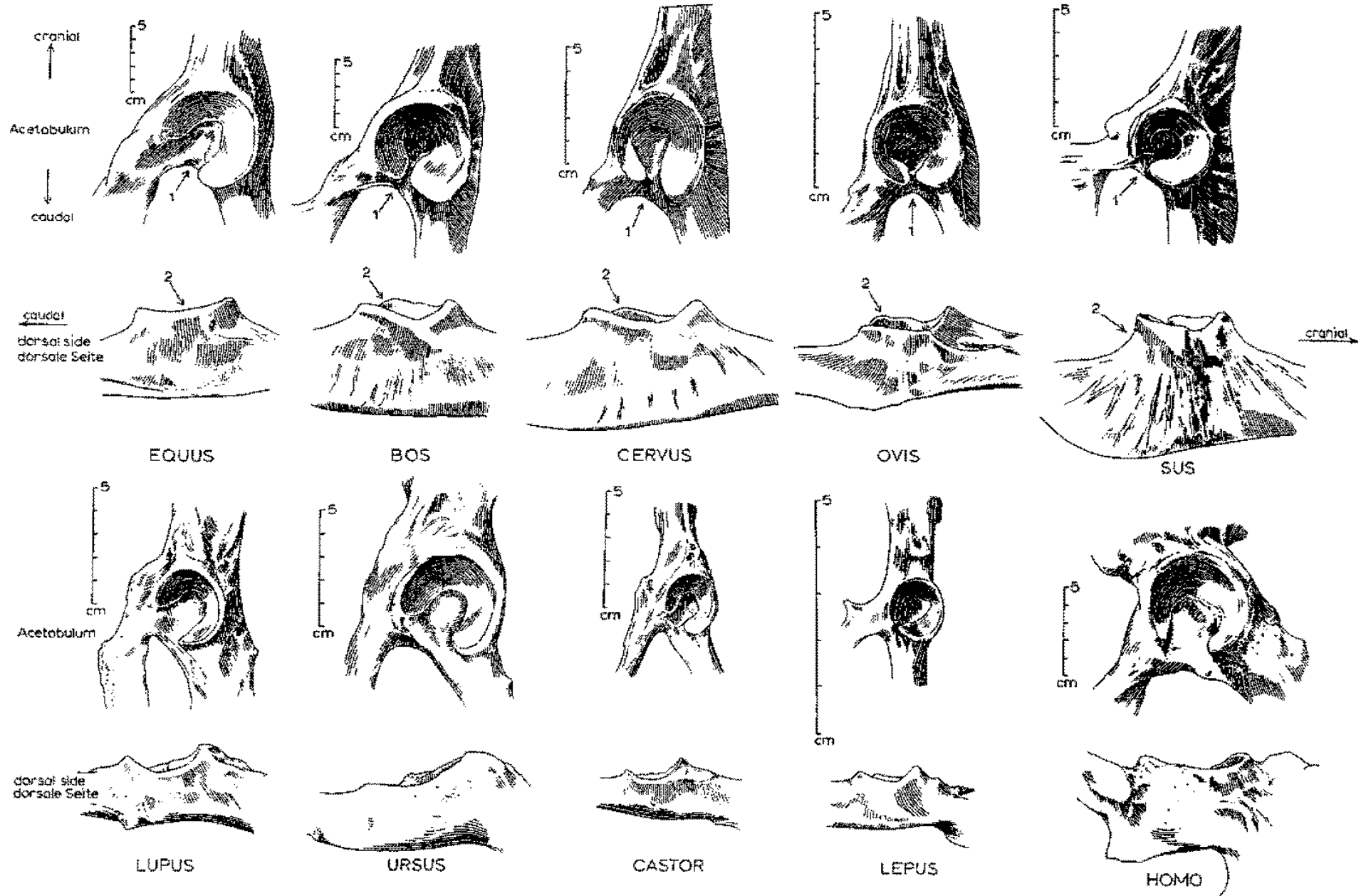


Incisura ischiadica major

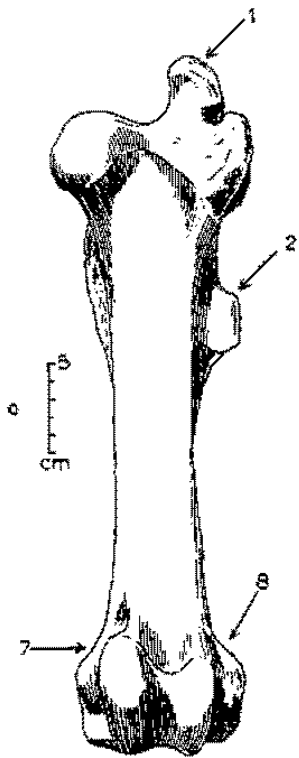
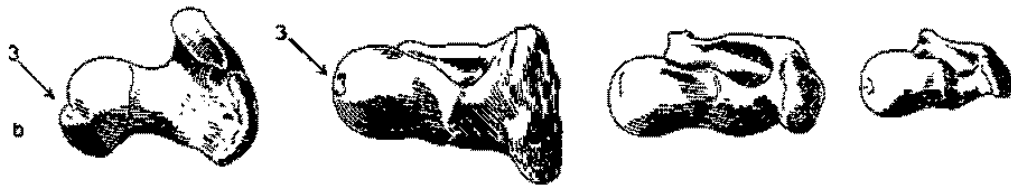
Pohlavní rozdíly na pánvi člověka



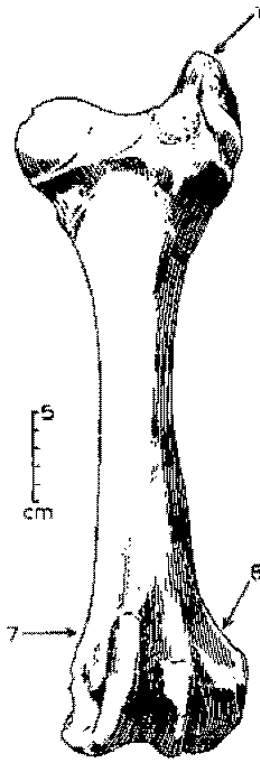
Pánve



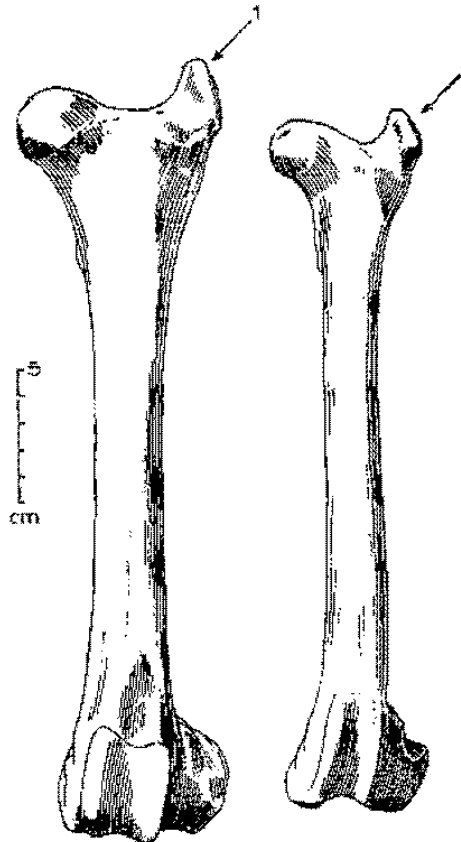
Stehenní kosti (*femur*)




EQUUS



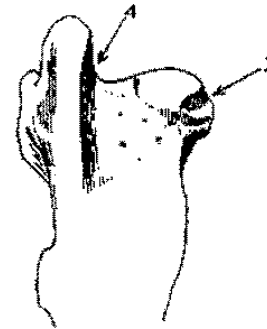
BOS



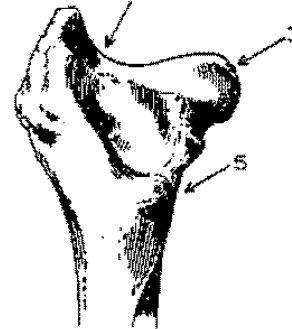
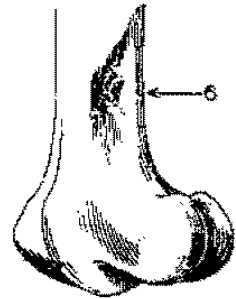
CERVUS



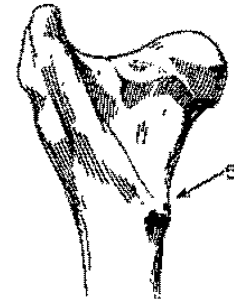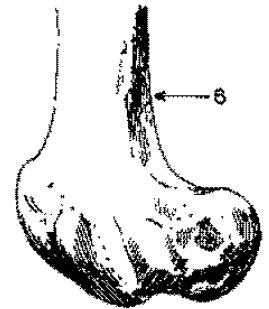
OVIS



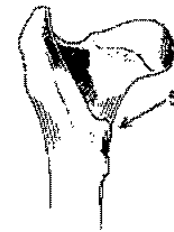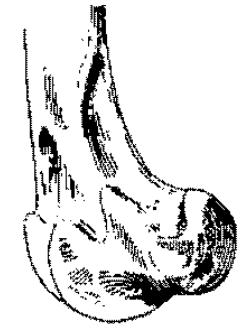
EQUUS



BOS

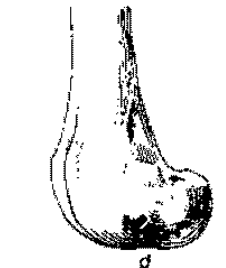


CERVUS



5
cm

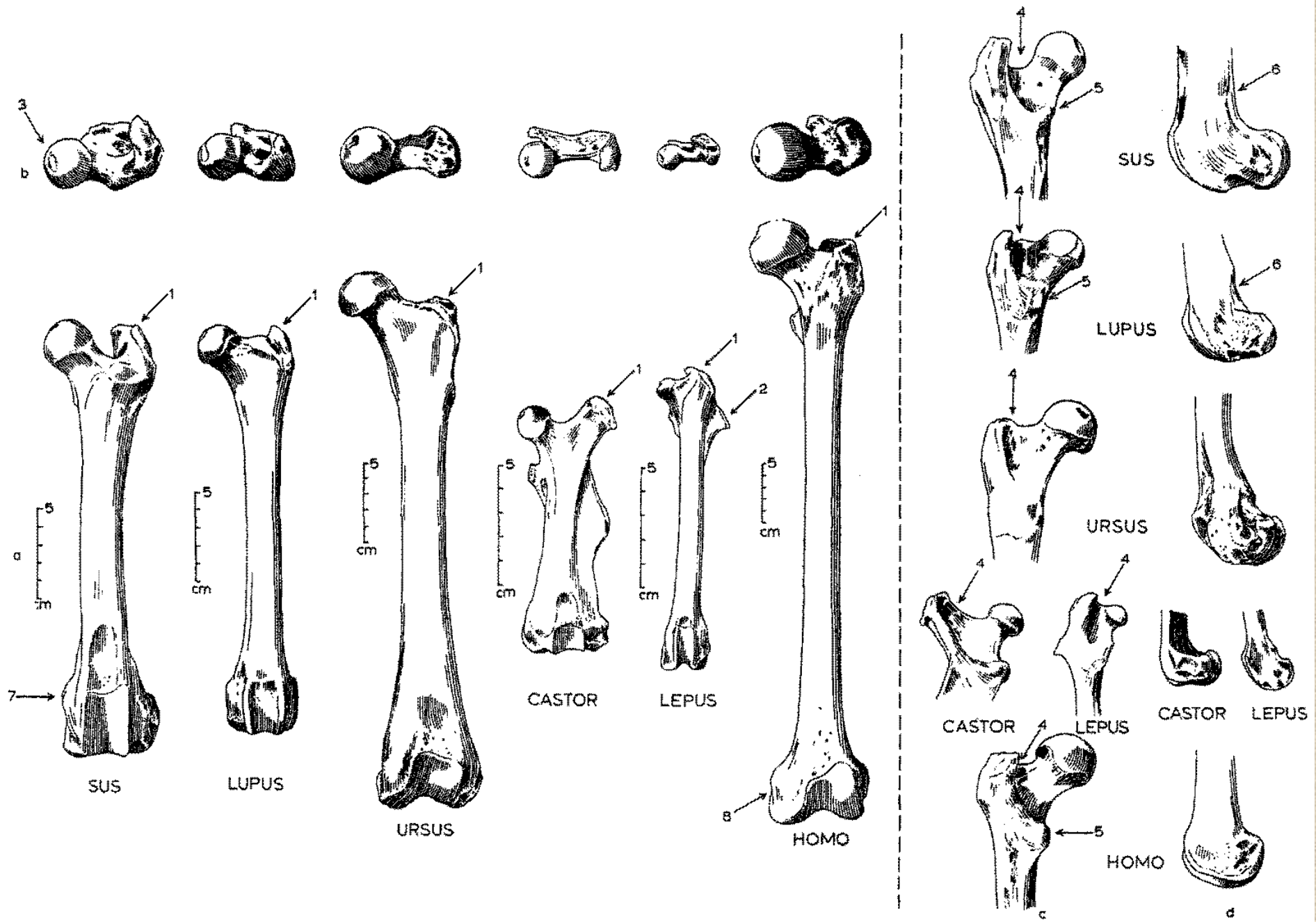
OVIS

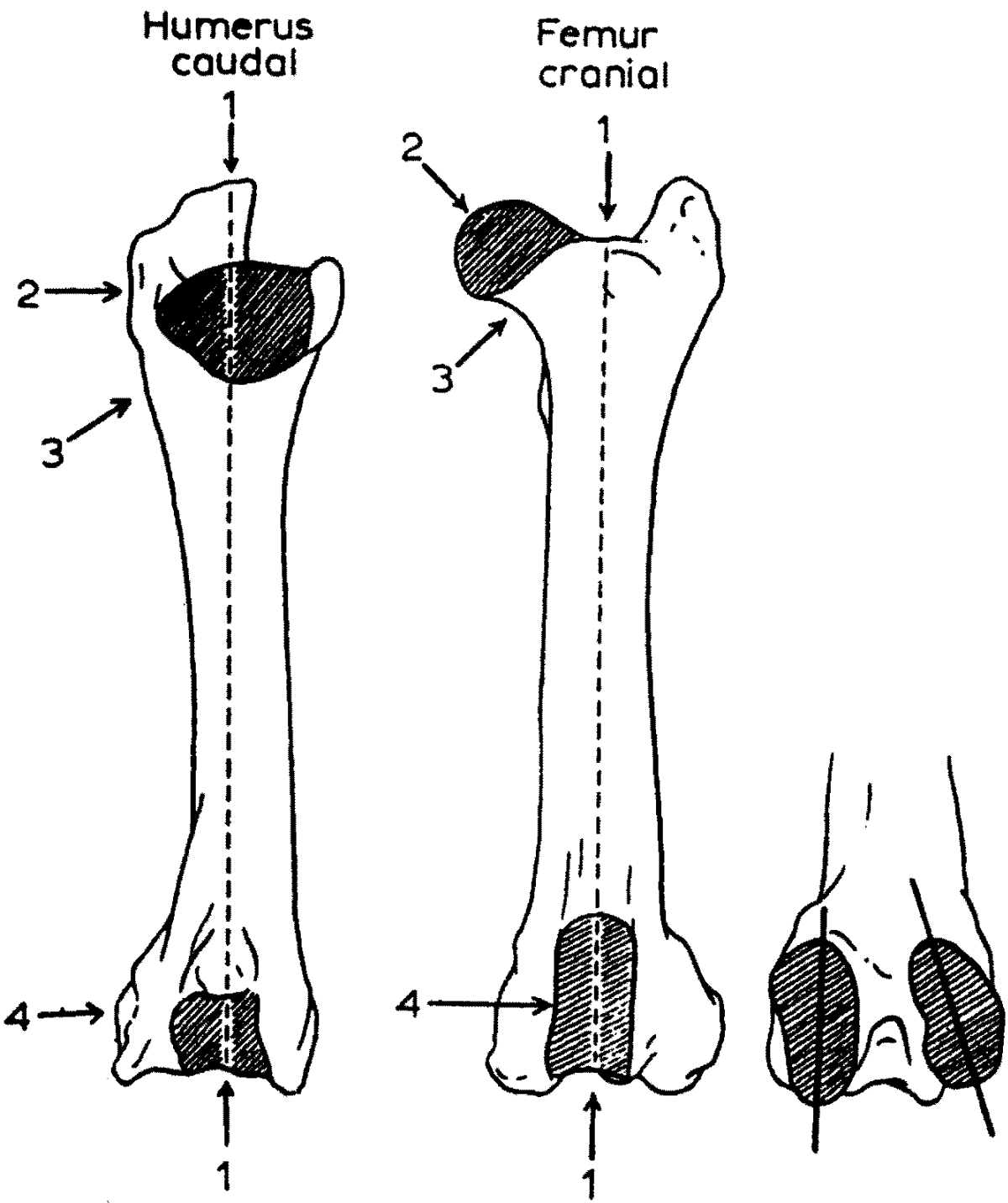


c

d

Stehenní kosti (femur)

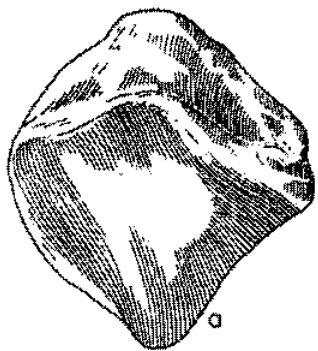




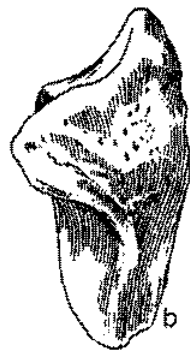Jak rozeznat stehenní a pažní kost



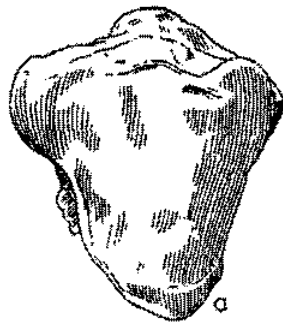
Češka (*patella*)



EQUUS



BOS



CERVUS



OVIS



SUS



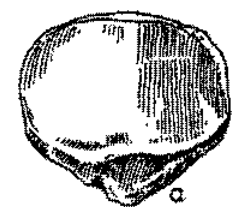

LUPUS



URSUS

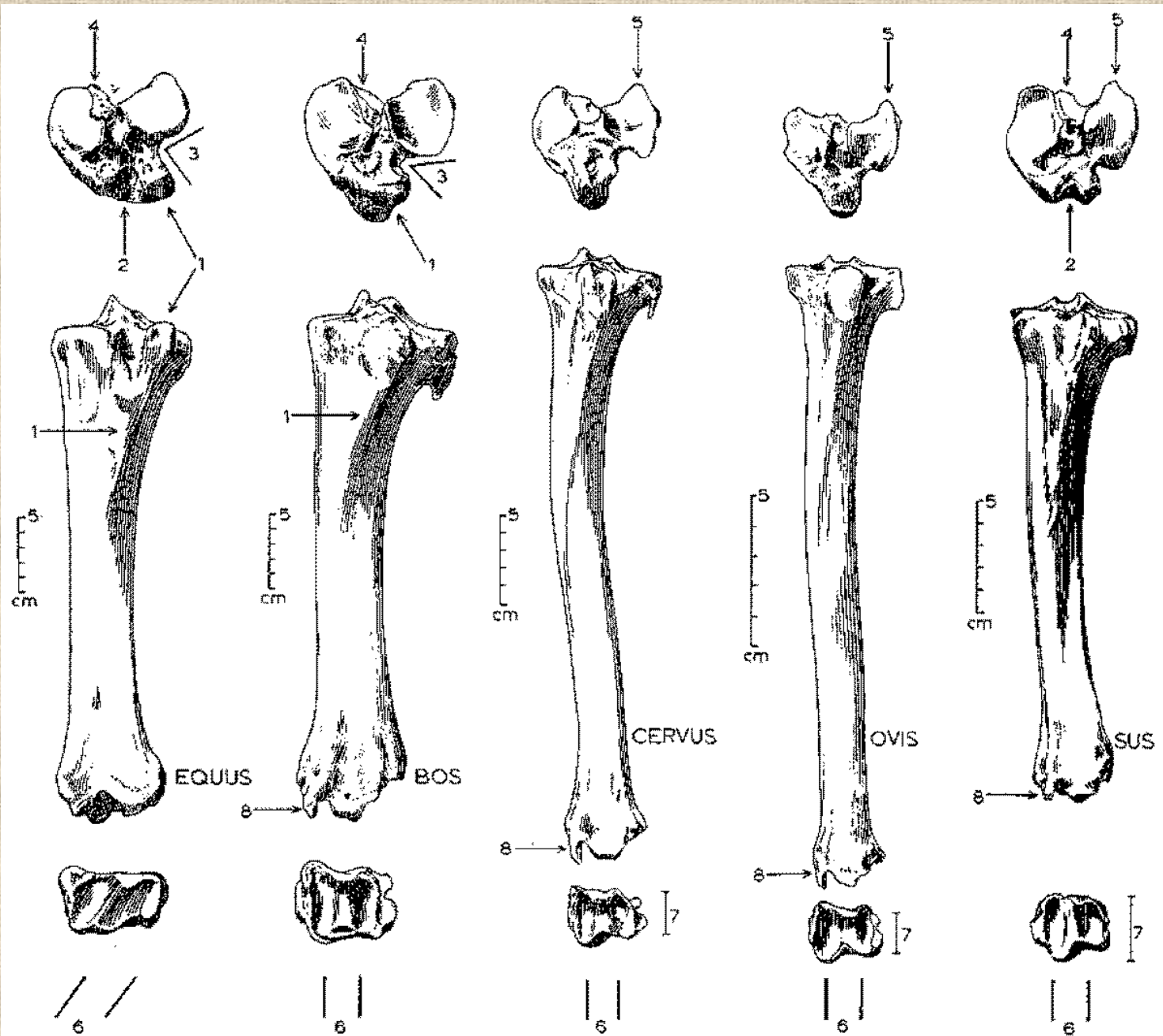


CASTOR

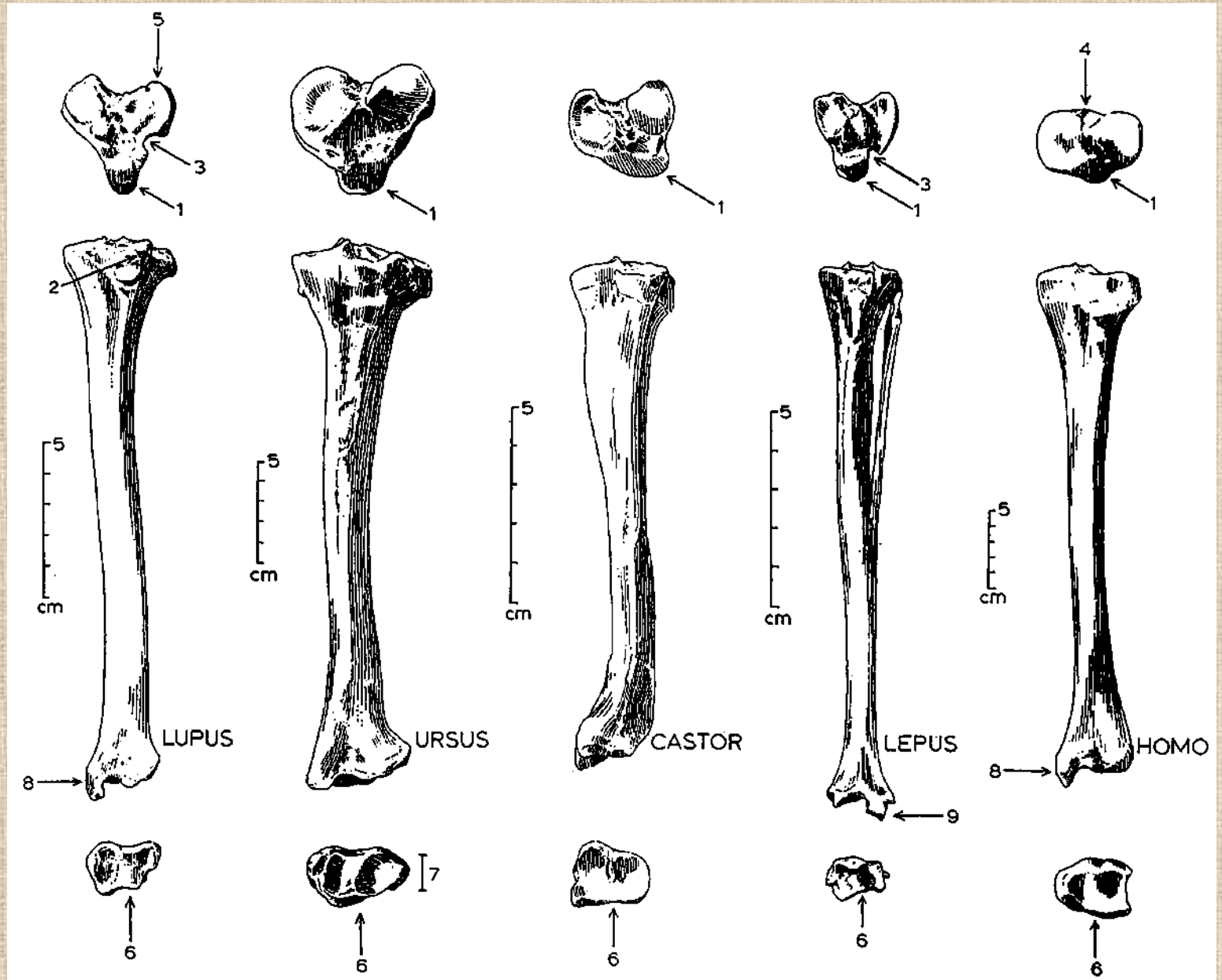


HOMO

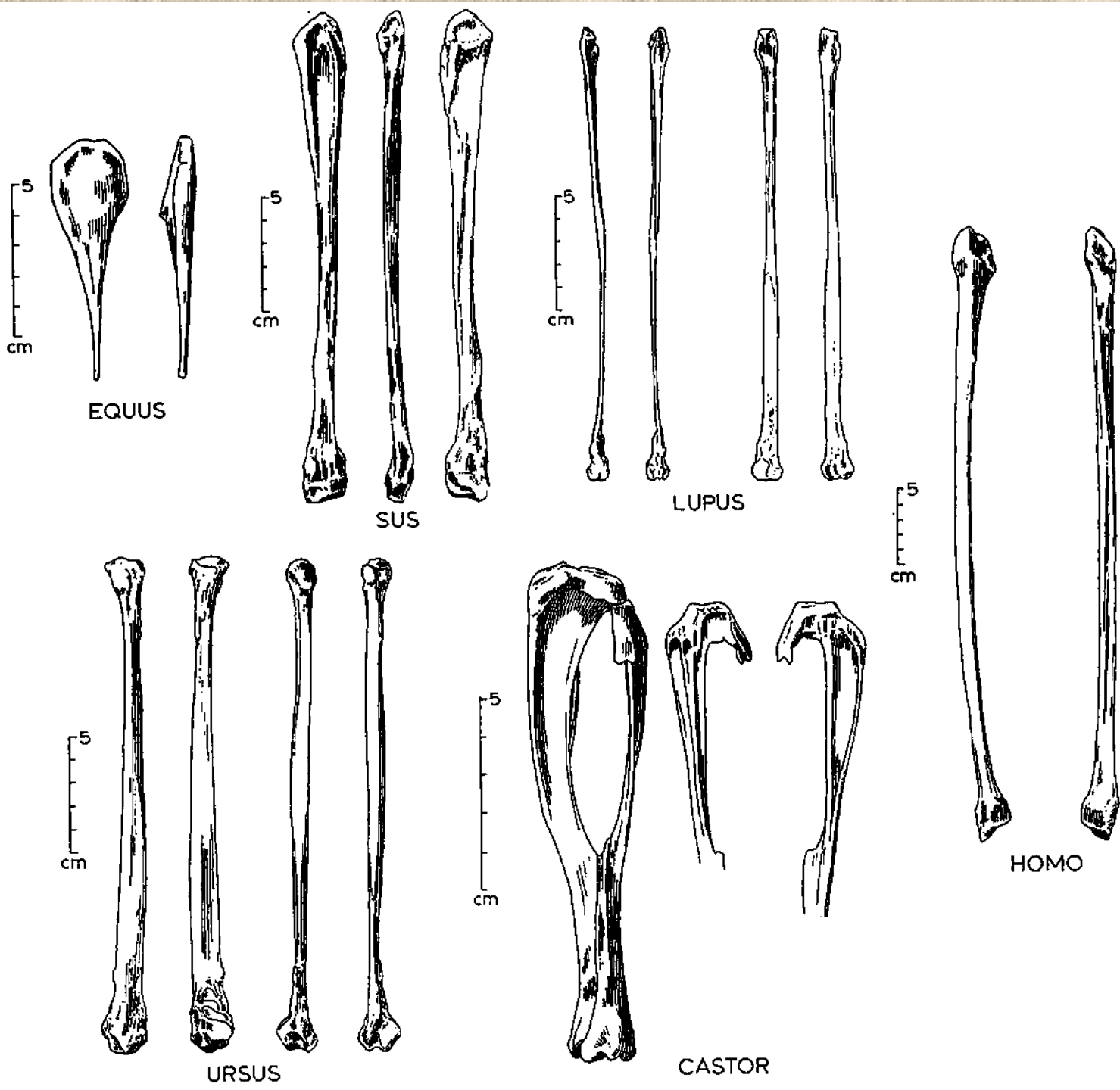
Holenní kosti (*tibiae*)



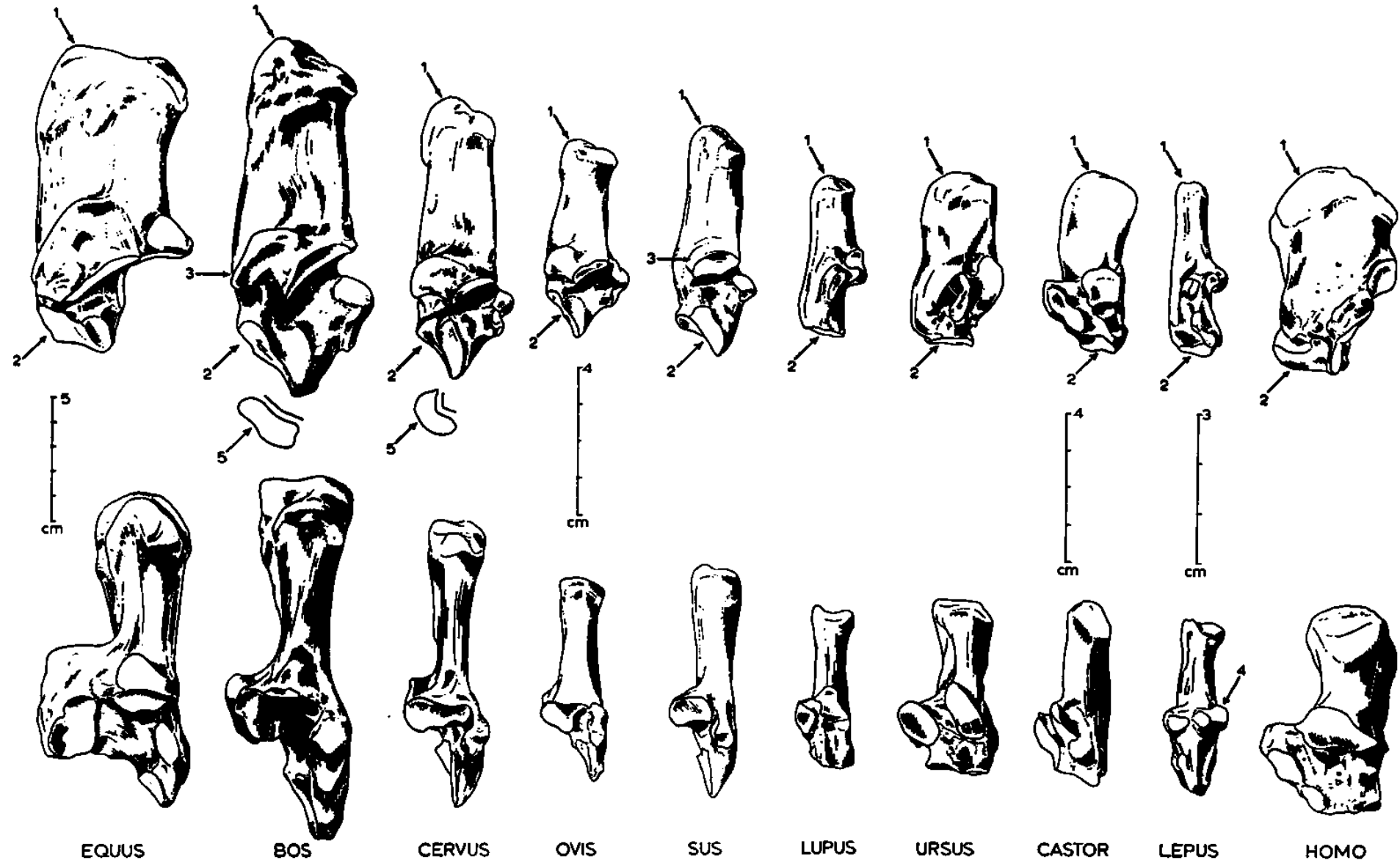
Holenní kosti (*tibie*)

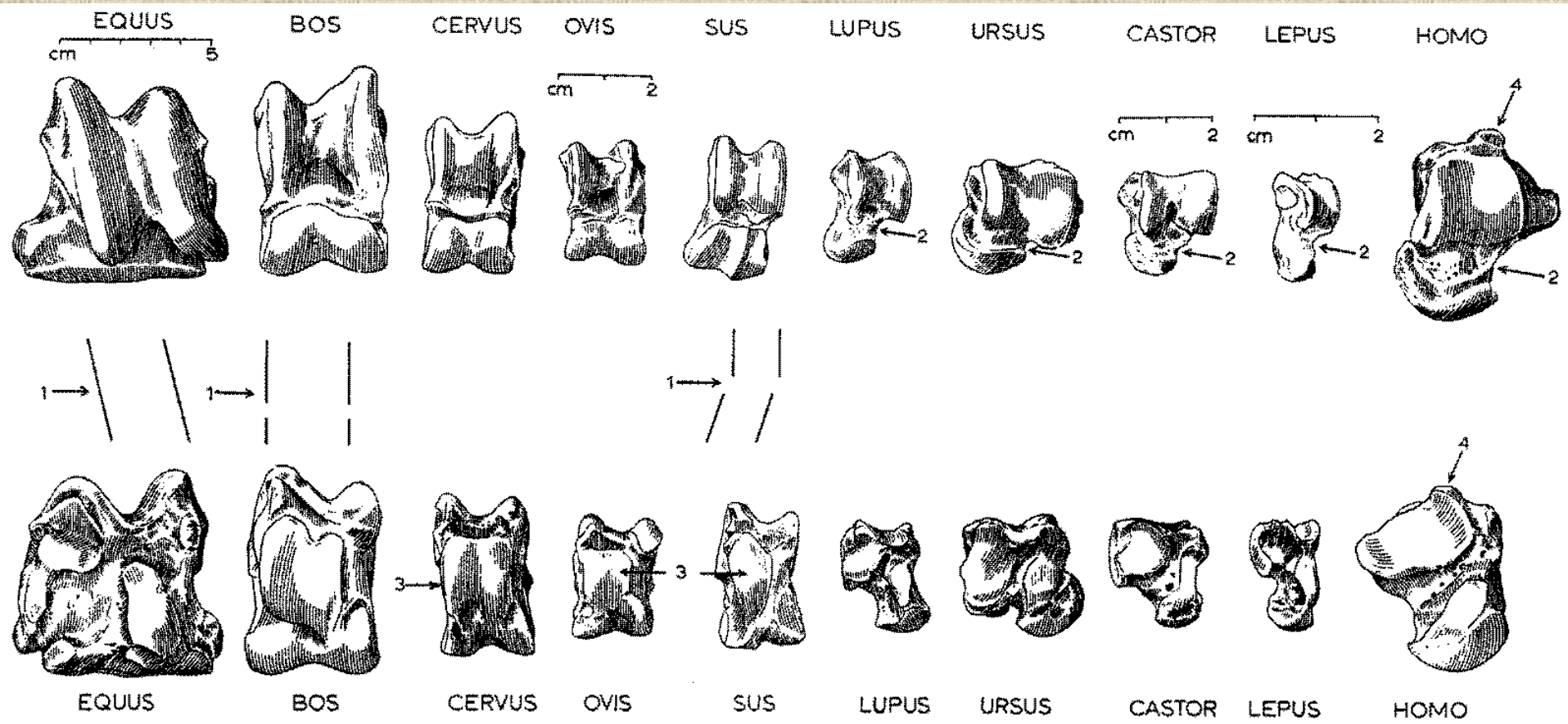


Lýtkové
kosti
(fibula)



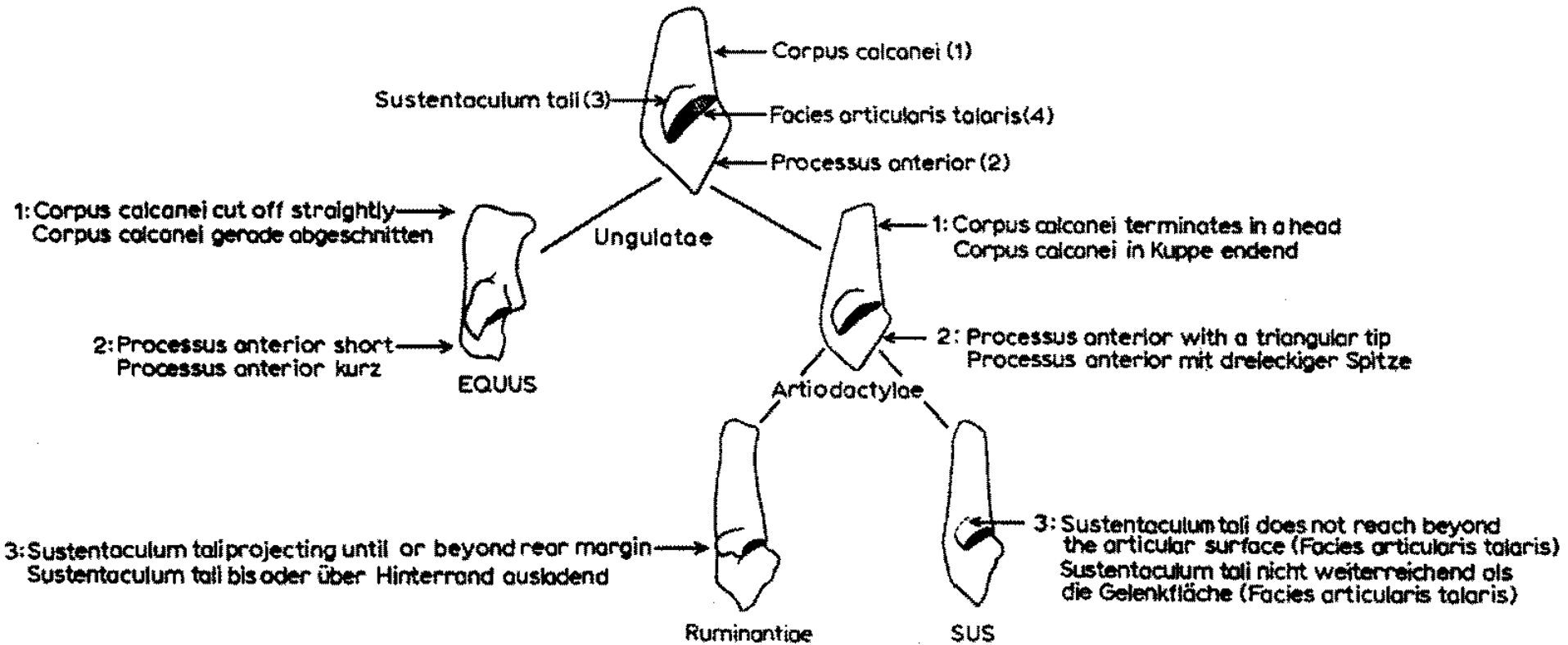
Kost patní (*calcaneus*)



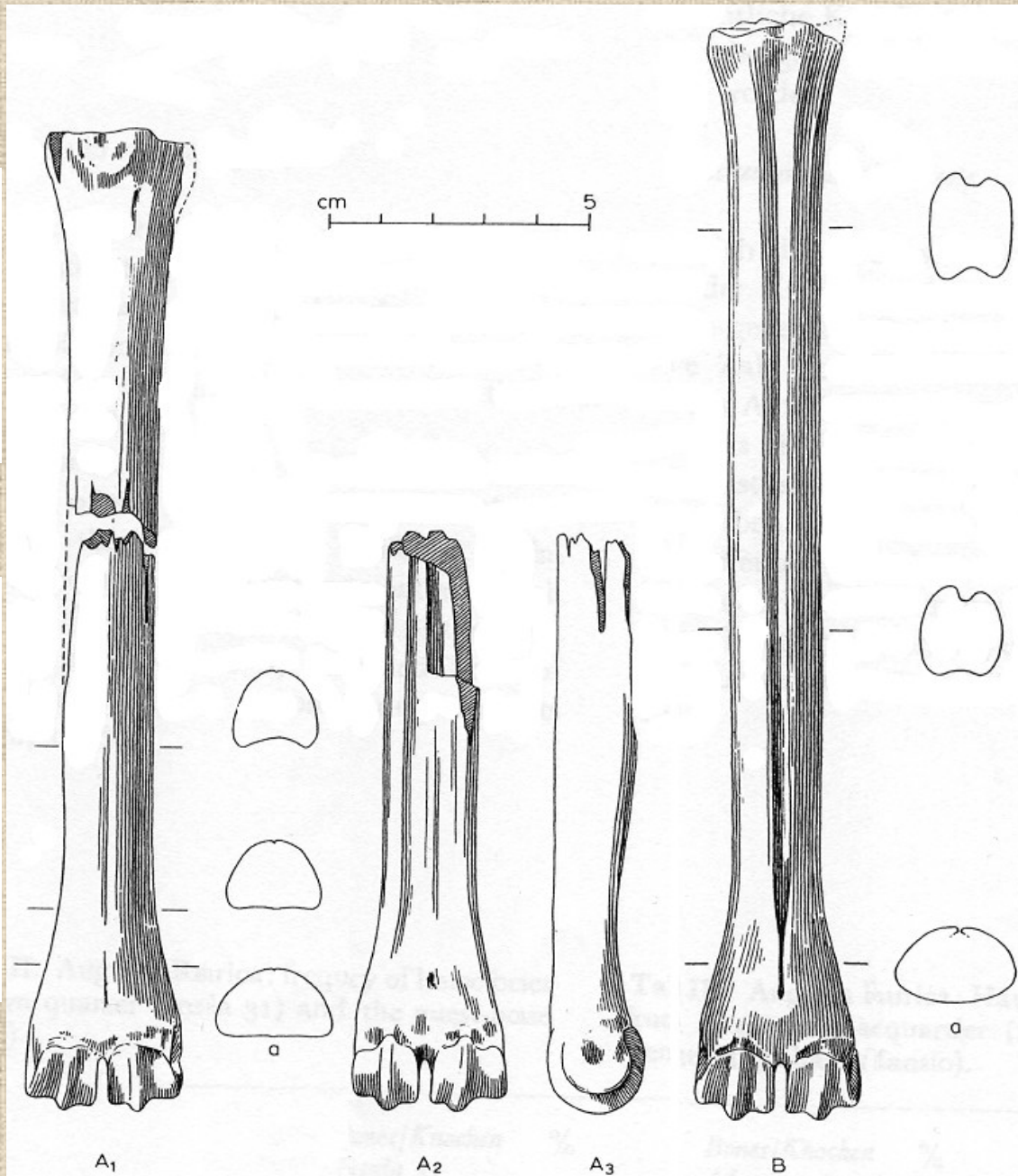
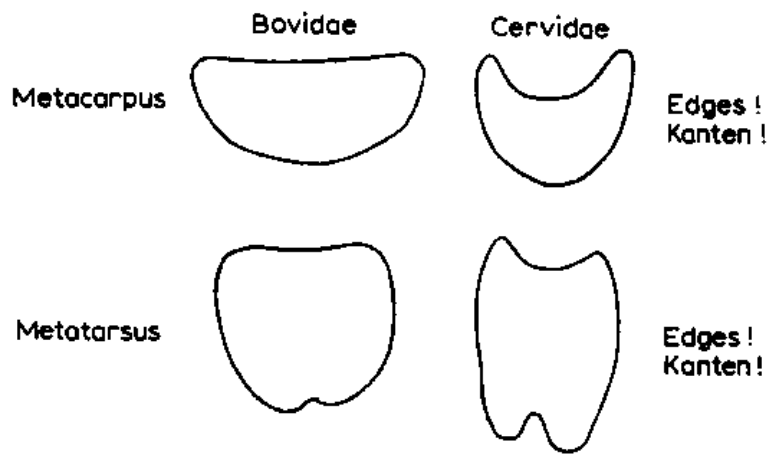
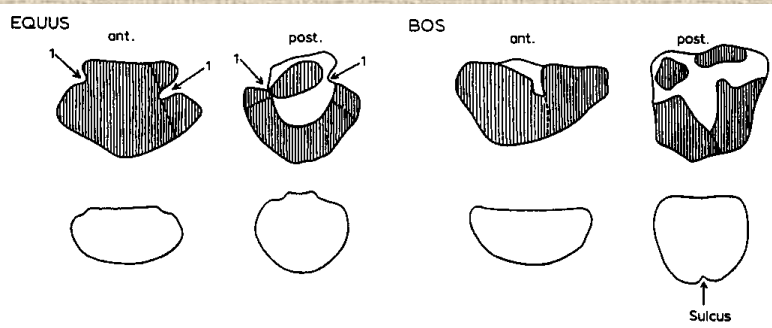


Kost hlezenní (*astragalus*)

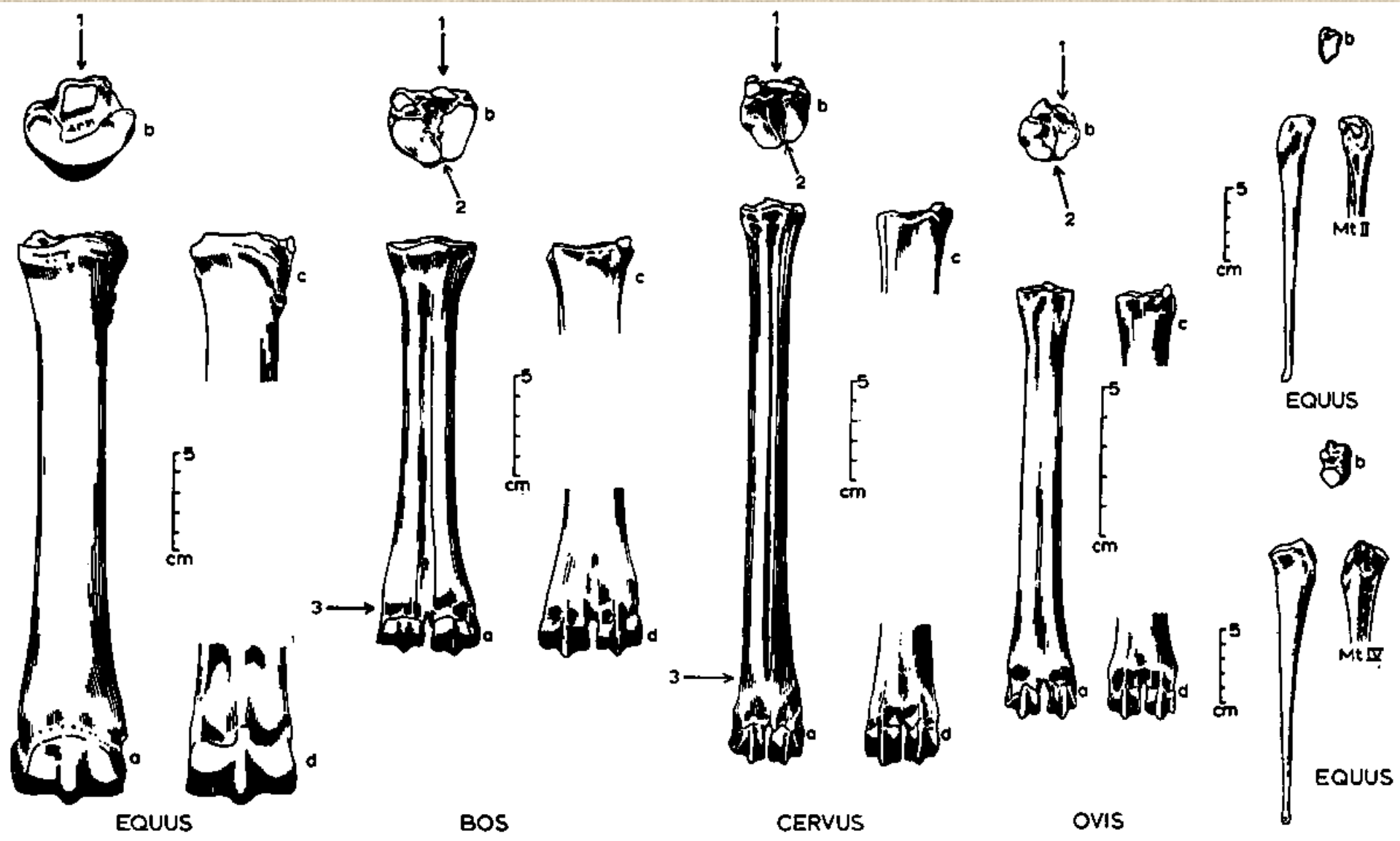
Rozdíly mezi kostmi patními býložravců a masožravců



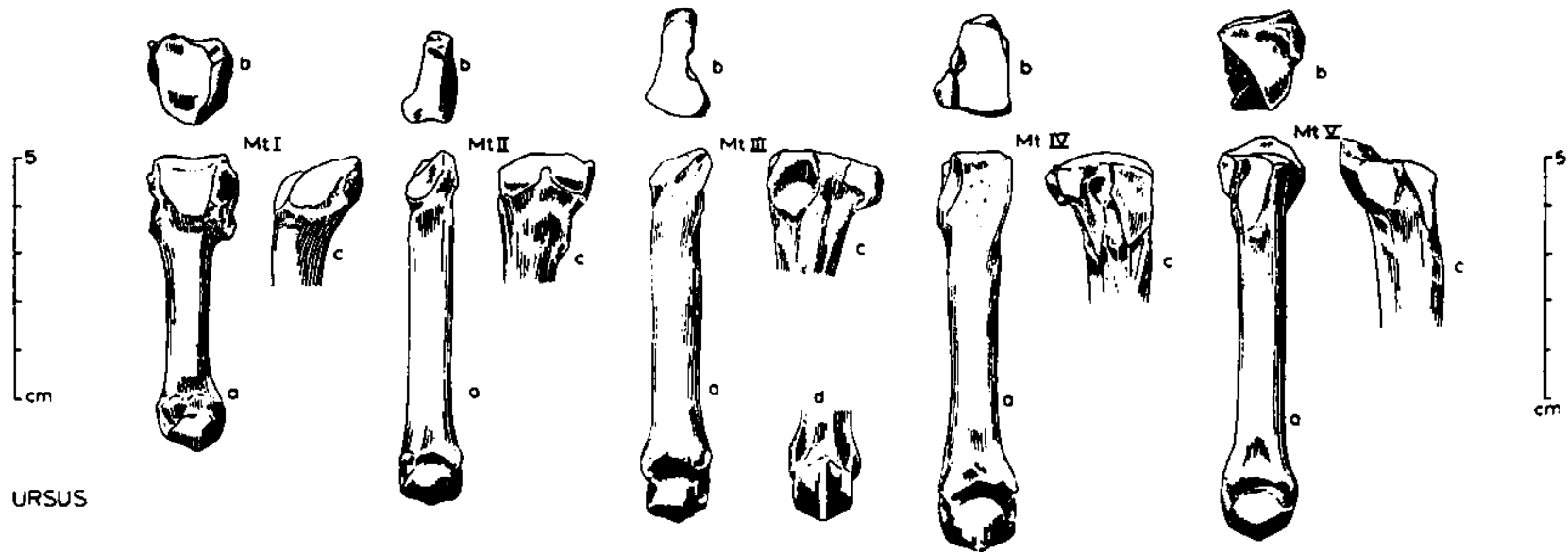
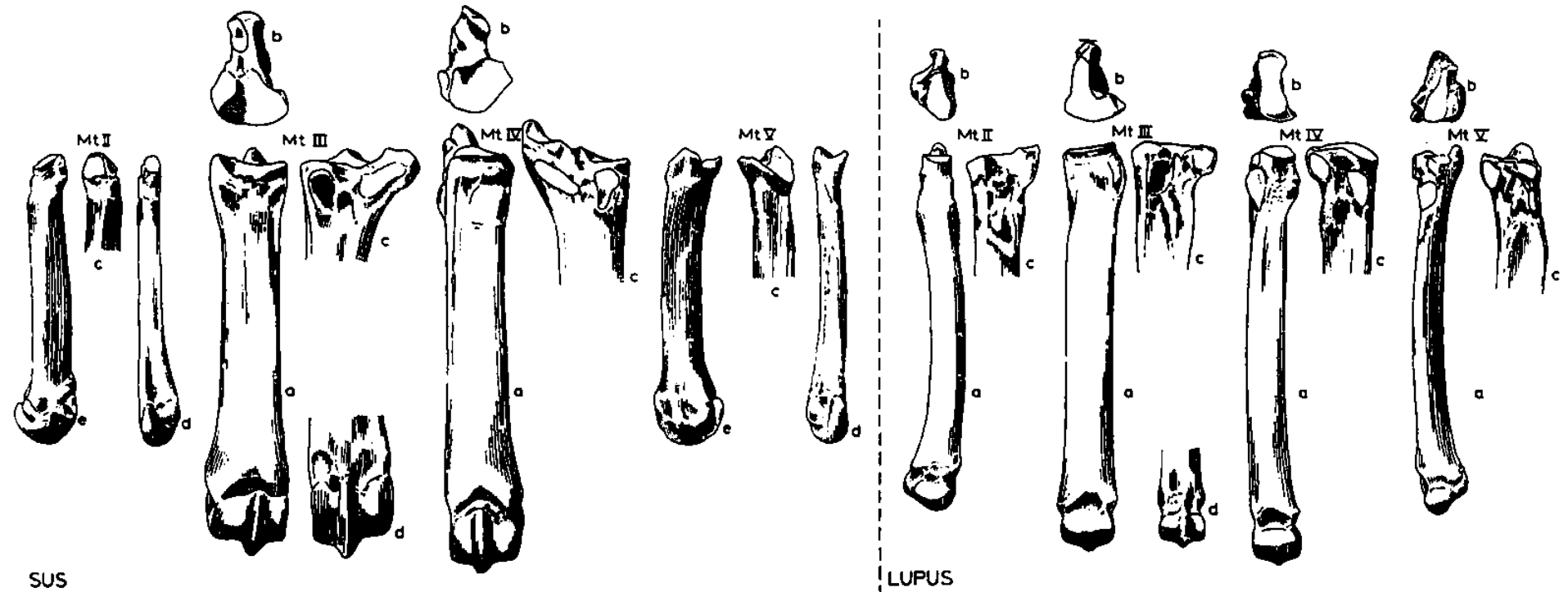
Rozdíl mezi záprstními a nártními kostmi



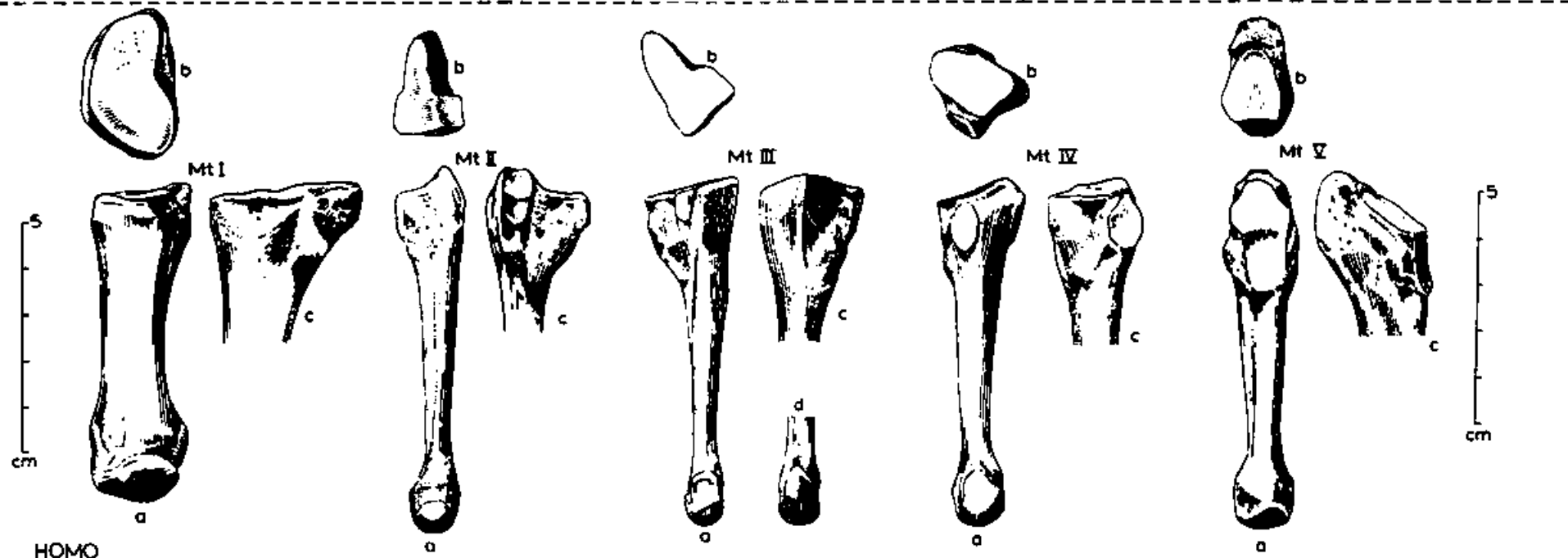
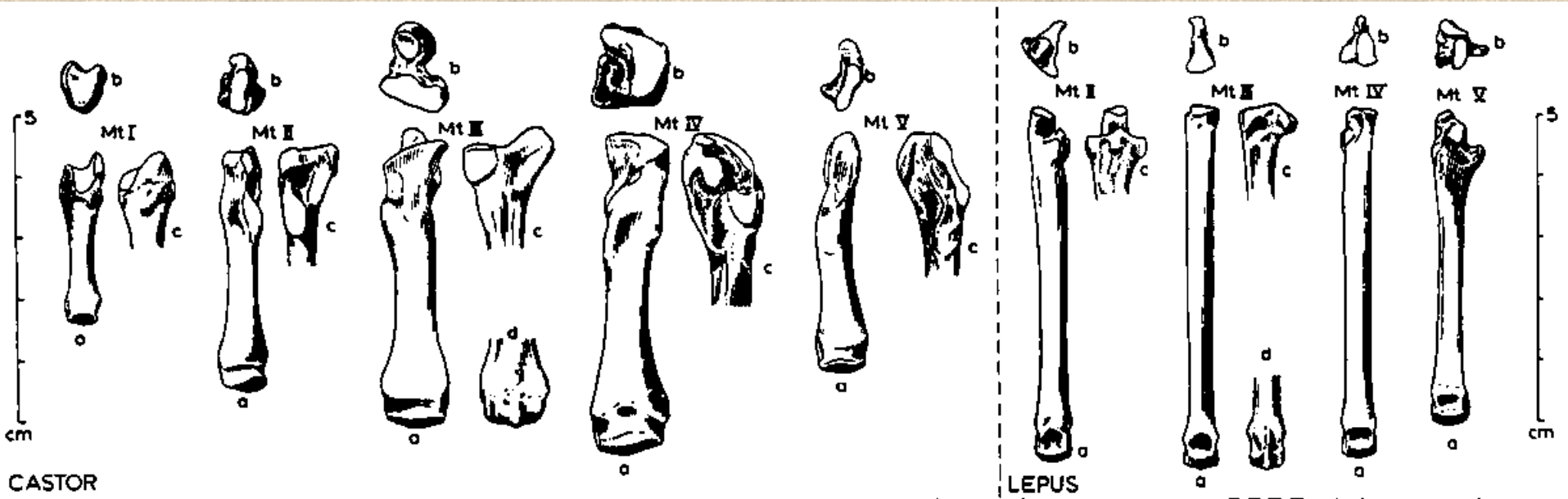
Nártní kost (*metatarsus*)

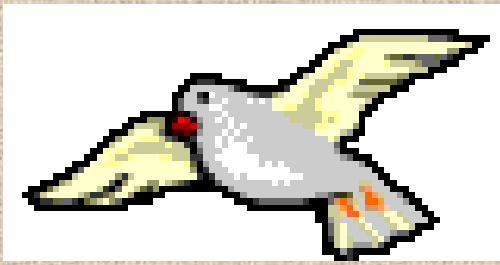

Nártní kost (*metatarsus*)

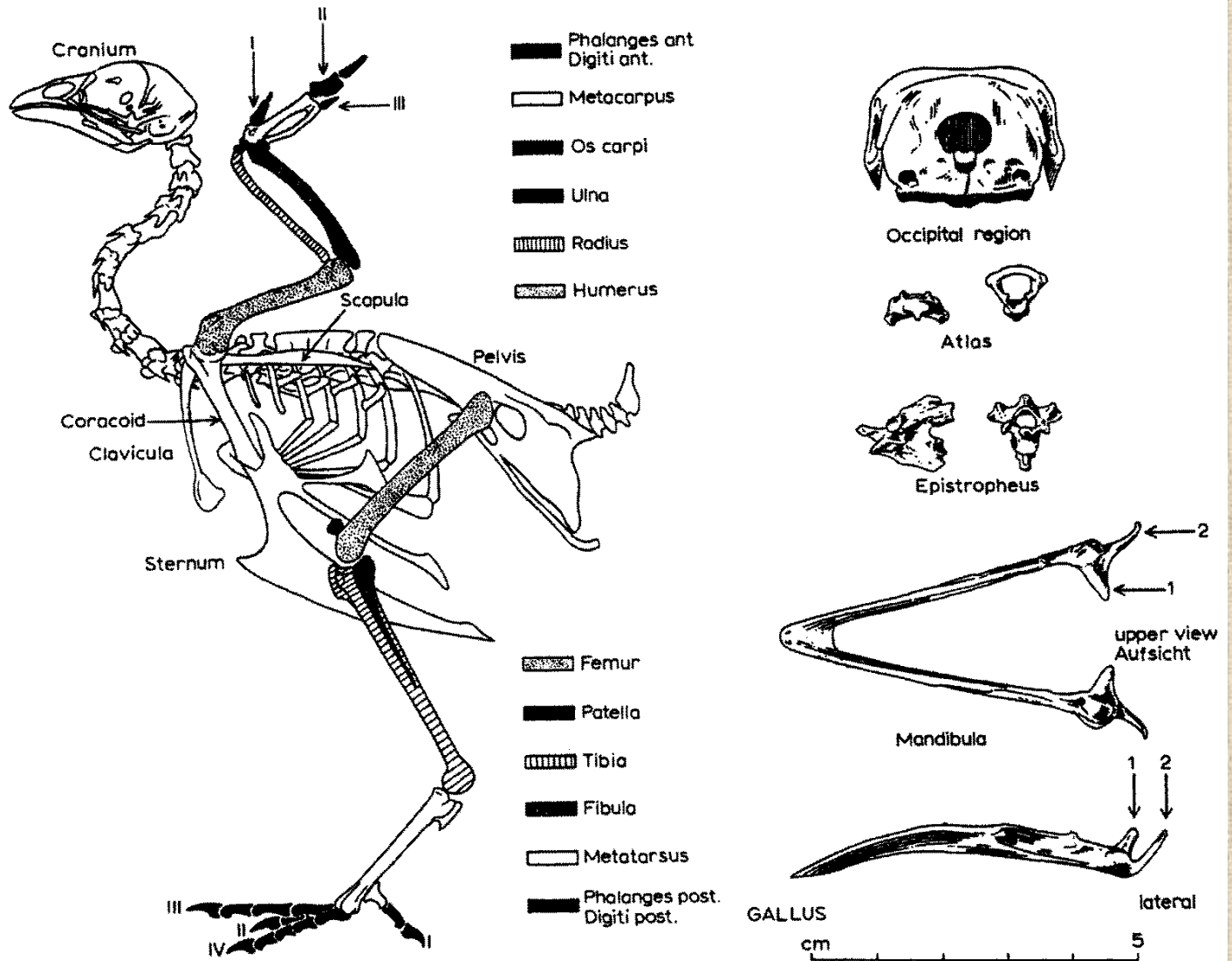


Nártní kost (*metatarsus*)

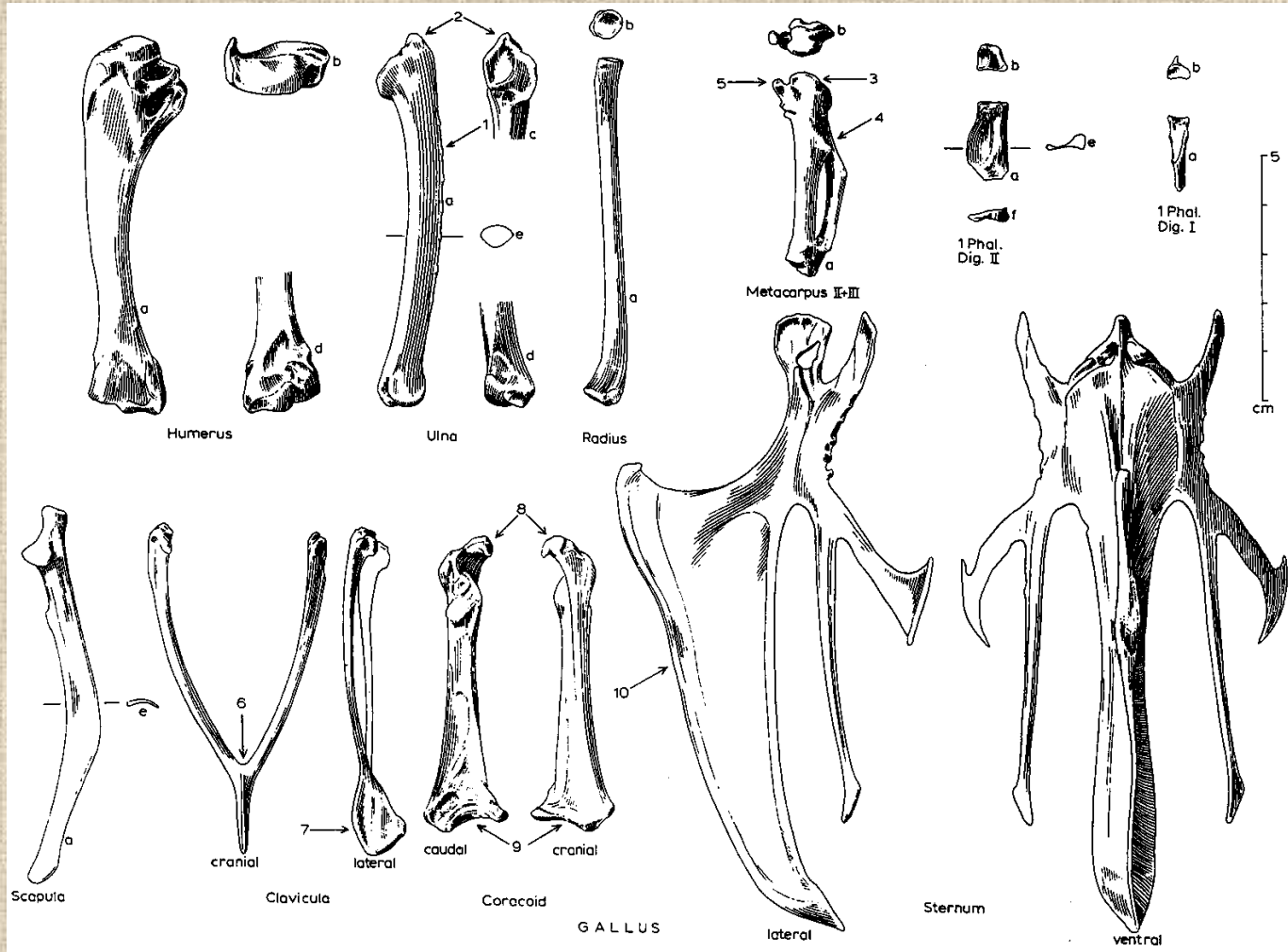




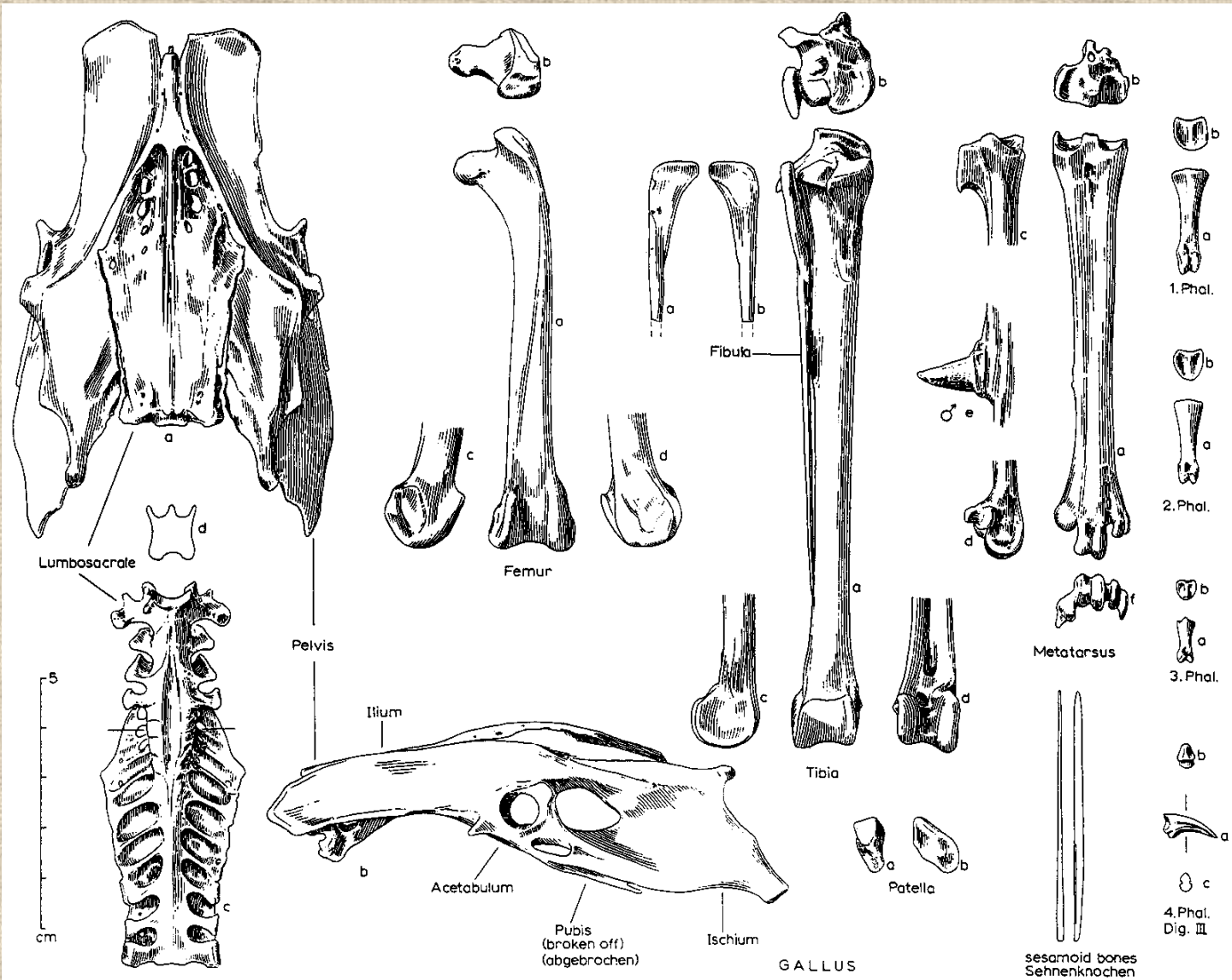
Ptačí kostra



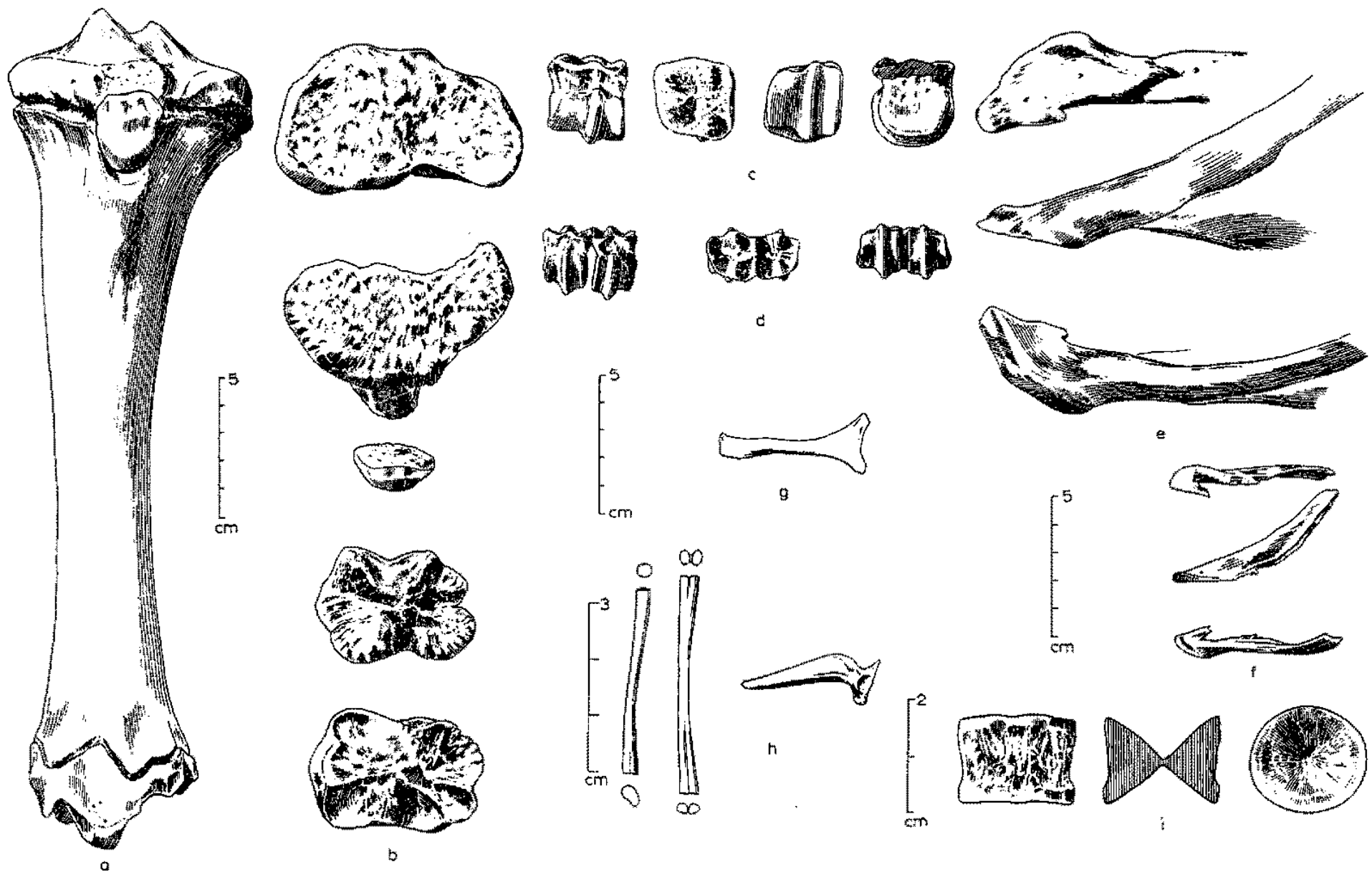
Kostra přední končetiny ptáka



Kostra zadní končetiny ptáka



Rozdílná morfologie kostí různých druhů zvířat





Děkuji za pozornost!