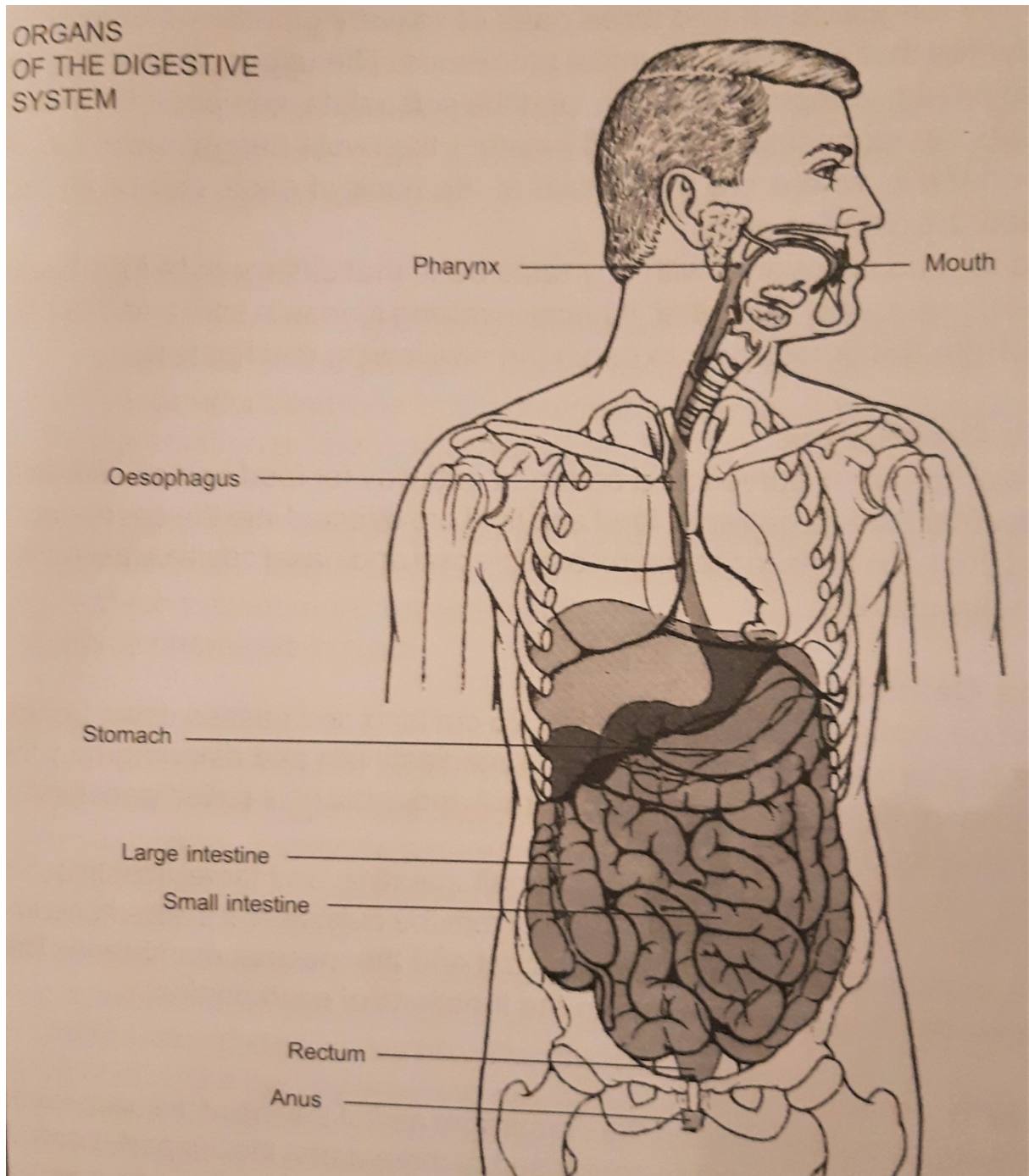


THE DIGESTIVE SYSTEM

The function of the digestive system is to digest food, absorb nutrients into the blood and eliminate any solid wastes. It is composed of:

1. A group of organs that form a tube to carry food from the mouth to the anus,
2. Several accessory organs that aid in digestion.



The tube of organs is called the **gastro-intestinal tract**, or the alimentary canal and is made up of the mouth, oropharynx, oesophagus, stomach, small intestine and large intestine.

The Mouth

The mouth or oral cavity, the first part of the tract, is lined with a mucous membrane, which secretes mucus to mix with the food, facilitating its movement through the pharynx and oesophagus. Within the mouth there are the **tongue, teeth and three pairs of salivary glands**, which produce enzymes that aid in the chemical processes. **The upper part is called the hard palate, composed of bone, and the soft palate, composed of muscle tissue.** An extension of the soft palate - the **uvula** hangs down into the **oropharynx**, where are the **tonsils** at the back of each side of an arch called the palatine arch.

The tongue is covered with tiny **taste buds** that differentiate **four tastes: sweet, sour, salty and bitter**. It helps in mixing food with **saliva** and pushes food into the oropharynx to begin the **swallowing mechanism**.

The Oropharynx

The oropharynx serves as a common pathway for food and air. When its **muscular tissue contracts**, food and fluid are directed into the oesophagus and the **entrances to the larynx and the oral and nasal cavities are closed** simultaneously.

The Oesophagus

The oesophagus is approximately **25 cm long and passes down behind the trachea and heart, through the mediastinum and diaphragm to the stomach.** Its walls alternately contract and relax (it is called **peristalsis**), moving food into the stomach. The structures of the stomach, small intestine and large intestine are similar in that they have four layers. From the outside are: the peritoneum, the muscle coat, the submucous coat and the mucous membrane. The variations that occur are due to the functions of each portion.

The Stomach

The stomach lies beneath the diaphragm and at the top of the abdominal cavity. It is a hollow organ composed of three parts: the top part is called the fundus, the central and the largest portion is called the body, and the lower part is the pylorus. Stomach muscles are very strong; their contraction leads to the mixing of food with gastric secretions to form a semisolid mixture called **chyme**, which is partially digested food. The stomach also produces some **hormones** (gastrin, enterogastrone) and **gastric juices** that help in digestion. The chyme then passes through the small intestine (which takes about 4 to 6 hours) into the large intestine. The food that has been absorbed into the blood by the presence of villi on the surface of the intestine is known as the residue.

The Small Intestine

It is the longest portion of the alimentary canal and is divided into the duodenum, jejunum and ileum. It contains many glands, which secrete digestive enzymes and hormones.

The Large Intestine

The large intestine has a greater diameter and is also called the large bowel. It consists of the caecum, colon, rectum and anal canal. **The appendix**, a slender blind tube, is attached to the caecum and is a frequent site of Inflammation or infection (**appendicitis**).

The liver, gallbladder and pancreas are called accessory organs of the digestion because food does not pass through these organs; instead they produce and store secretions that flow into the small intestine and bring about chemicals in food.

The Liver

The liver is a large reddish brown wedge-shaped organ situated on the right hand side in the upper abdomen, beneath the diaphragm. It is covered by the peritoneum, except for a bare area on the posterior surface, which is closely related to the diaphragm. Blood flows through specialized cells in the liver called sinusoids.

The liver has many functions and is essential for life; it destroys many toxic substances, stores glycogen, vitamins A, D, E, K, and B12, iron, cholesterol, etc., and produces bile. The bile is an alkaline yellowish green fluid formed in the liver by breaking down old red blood cells. It contains water, calcium and sodium salts and bile pigments: bilirubin and biliverdin. The bile salts activate pancreatic lipase and are necessary for the digestion and absorption of fats. Fats are stored in the liver and other fat deposits in the body and when required, they are taken to the liver and split into fatty acids and glycerol. The bile leaves the liver through the hepatic duct that divides into the common bile duct (it carries bile into the small intestine) and the **cystic duct that transports bile to the gallbladder for storage.**

The Gallbladder

It is on the undersurface of the liver with an average capacity of 40 - 50 ml. When food containing fat and partially digested proteins enters the duodenum, a hormone is secreted by cells of the duodenal mucus; it is carried in the blood and, on reaching the gallbladder, stimulates the smooth muscle tissue to contract and eject bile.

The Pancreas

The pancreas lies on the left side of the abdominal cavity under the stomach. Pancreatic cells produce secretions and enzymes, where starches, fats and proteins break down into nutrients that can be absorbed into the blood.

Three processes must occur to convert food into a form that can be used by the body: digestion, absorption and metabolism.

The digestion process takes 12 to 48 hours, depending upon the type and quantity of food consumed. There are two types of digestion: mechanical and chemical.

Mechanical changes in the food involve breaking relatively large pieces into very small and changing solid food into liquid form, but they cannot completely prepare food for use in the body.

Chemical digestion begins with the addition of the **enzyme ptyalin** to the food. Three salivary glands secrete ptyalin:

1. The parotid glands, located behind the upper jaw just below each ear,
2. The submaxillary glands, found in the floor of the mouth beside the lower jaw,
3. The sublingual glands, located under the tongue.

No digestive changes occur in the oesophagus; additional digestive processes begin in the stomach. How long food remains in the stomach depends upon the type of food consumed - carbohydrates leave the stomach more quickly than fats or proteins.

Digestion is complete when nutrients have been reduced to their simplest form: carbohydrates have become monosaccharides (glucose, fructose or galactose), proteins have become amino acids and fats have been broken down into fatty acids and glycerides. These substances must be absorbed before the body can use them.

Absorption of nutrients occurs in all three sections of the small intestine, and absorption of water in the large intestine.

Metabolism is the process, by which the body uses nutrients for energy and the building of body tissue. Two processes are involved in metabolism:

- a) **Anabolism - the building, repairing and maintaining of the tissue,**
- b) **Catabolism - the breaking down of tissues and excretion of the byproducts.**

When the products of carbohydrate digestion are absorbed into blood through the villi, these nutrients are transported to the liver, where fructose and galactose are changed to **glucose**. If glucose is not needed immediately for energy, the liver converts extra glucose into **glycogen**, which is stored in the liver. **The body produces many substances to regulate the level of glucose in the blood. When it is high, insulin converts the glucose into glycogen. Insulin is a hormone produced in the pancreas; an increase in the blood glucose level stimulates the pancreas to secrete additional insulin, which results in a lowering of the blood sugar level.**

Common disorders of the gastro-intestinal system

Conditions of the mouth vary in severity from a mild inflammation to serious pathological changes such as cancer. **Inflammation of the mucous membrane of the mouth is called stomatitis. Herpes simplex and fever blisters** are viral infections that occur where mucous membrane joins the skin.

Symptoms of **stomach disorders** include **indigestion, nausea, vomiting and pain. Inflammation of the stomach lining is gastritis.** When gastritis is accompanied by **diarrhoea**, the condition is called **gastro-enteritis** and **involves the inflammation of both upper and lower tracts.** Complete rest of the digestive system and administration of intravenous fluids may be required to control the symptoms. Lesions of the upper digestive tract are called **peptic ulcers.** In the early stages they are treated with a diet, rest and medication. A large lesion may require surgical repair. The complications of the ulcer are haemorrhage and perforation. **Removal of all the stomach** (for instance at the presence of a tumour) is called **gastrectomy.**

The inflammation of the small intestine is called **enteritis**; the infection in the large one is **colitis.** It is caused **by bacteria, viruses and parasites.** A regional enteritis, known as **Crohn's disease** is a chronic type. Chronic inflammation that results in ulceration of the colon lining is called **ulcerative colitis,** caused mostly by emotional problems.

If the tiny lumen of the appendix becomes obstructed with faecal material and inflamed, we speak about **appendicitis.** The appendix then must be removed surgically as soon as possible.

When **the enlarged veins** (varicose veins) that are **distended with blood occur in the rectum,** we speak about haemorrhoids. **Internal haemorrhoids** are located inside the anal sphincter, the **external** ones can be found outside the anus. Surgical excision is called haemorrhoidectomy. It is not a complicated procedure, but the postoperative period is painful.

One of the first symptoms of **liver dysfunction** is related to the secretion of bile. When the liver fails to remove bilirubin from the blood, its accumulation gives rise to **jaundice** (yellowing of the skin and the whites of the eyes). **The next common diseases of the liver are hepatitis, cirrhosis and cancer.** **Viral hepatitis** is an inflammation that destroys liver cells. It is a serious illness that does not respond to drug therapy, but permanent liver damage is rare because new liver cells eventually replace the damaged ones. Convalescence is lengthy, sometimes requiring 3 to 6 months. The exact reason for the **cirrhosis,** when **normal liver cells are replaced by fibrous tissue, which results in hardening or scarring of the liver,** is not known, but there is a relationship between **alcoholism** and the disease. There is no cure again, treatment is long and requires changes in the patient's life-style and a diet full of vitamins.

Inflammation of the gallbladder is called **cholecystitis** (caused by fats); and inflammation of the pancreas (mostly as a complication of a viral or bacterial infection) is called **pancreatitis.**

If the pancreas does not produce sufficient insulin to allow glucose to enter the body cells, the condition called diabetes mellitus develops. It may be hereditary and often occurs after the age of 50. Sometimes it can also develop as a secondary feature to another disorder or following the administration of certain drugs (corticosteroids).

The diabetes may be controlled by a diet alone, or by the combination of diet and hypoglycemic drugs, or diet and insulin. Patients who especially inquire insulin therapy are often children and young adults. Insulin is a protein and cannot, therefore, be given orally as it would be destroyed by the gastric juices. It is prepared from the pancreas of cattle and sheep so that it might be given parenterally.

Tumours of the liver and pancreas are usually malignant and have a high death rate because symptoms do not occur until the tumour is large. Survival after diagnosis is usually less than one year.

| VOCABULARY | |
|--|-----------------------|
| alimentary canal [æli'mentri kæn] | zažívací ústrojí |
| anal [eɪn] | řitní |
| bare [beə] | holý, obnažený |
| bile [baɪ] | žluč |
| capsule [kæpsju:l] | pouzdro, váček |
| cholecystitis [kəulisɪs'taɪtɪs] | zánět žlučníku |
| cholelithiasis [kəulɪli'θaɪəɪsɪs] | žlučové kaménky |
| cut off [kat of] | odříznout |
| deplete [dɛ'pli:t] | vyprázdnit |
| diaphragm [daɪəfræm] | bránice |
| diarrhoea [daɪə'riə] | průjem |
| digestion [dɪ'dʒesʃn] | trávení |
| duct [dakt] | kanálek, vývod |
| duodenum [dju:ə'di:nəm] | dvanáctník |
| flatulence [flætjʊləns] | nadýmání |
| fundus, pl. fundi [fandəs] | dno |
| gallbladder [gɔ:lblædə] | žlučník |
| gastric juice [gæstrɪk dʒu:s] | žaludeční šťáva |
| gastritis [gæs'traɪtɪs] | zánět žaludku |
| hepatic [hi'pætɪk] | jaterní |
| hernia [hə:niə] | kýla |
| ileum [iliəm] | kyčelník |
| ileus [iliəs] | neprůchodnost střevní |
| indigestion [ɪndɪ'dʒesʃn] | špatné trávení |
| intestine [ɪn'testɪn] | střevo |
| small intestine [smɔ:l] | tenké střevo |
| large intestine [da:dʒ] | tlusté střevo |
| jaundice [dʒɔ:ndɪs] | žloutenka |
| jejunum [dʒɪ'dʒu:nəm] | lačník |
| nodular [nɔdʒulə] | uzlovitý |
| pancreas [pæŋkriəs] | slinivka břišní |
| pancreatitis [pæŋkriə'taɪtɪs] | zánět slinivky břišní |
| pelvic [pevɪk] | pánevní |
| peptic ulcer [peptɪk a:lsə] | žaludeční vřed |
| perforation [pə:fə'reɪʃn] | protržení, perforace |
| peristalsis [perɪ'stælsɪs] | peristaltika |

| | |
|---|--------------------------|
| peritoneum [peritə'ni:əm] | pobřišnice |
| peritonitis [peritə'naitis] | zánět pobřišnice |
| pylorus [pai'lorəs] | vrátník |
| rectum [rektəm] | konečník |
| residue [rezidju:] | zbytek, usazenina |
| salivary gland [sælivəri glænd] | slinná žláza |
| parotid salivary gland [pə'rotid] | příušnicová slinná žláza |
| sublingual salivary gland [səb'liŋgwel] | podjazyková slinná žláza |
| submaxillary salivary gland [səb'mæksiləri] | podčelistní slinná žláza |
| scarring [ska:riŋ] | zjizvení |
| sphincter [sfɪŋktə] | svěrač |
| spleen [spli:n] | slezina |
| stenosis [stə'nəʊsis] | zúžení |
| stool [stu:l] | stolice |
| swelling [swelɪŋ] | otok |
| uvula [ju:vjulə] | čípek |
| varix, varices [veərɪks, veərɪsi:z] | křečové žíly |
| vermiform appendix [və:mifo:m ə'pendɪks] | červovitý přívěsek |
| villus, pl. villi [viləs, vilai] | klk |
| viscera [visərə] | útroby |