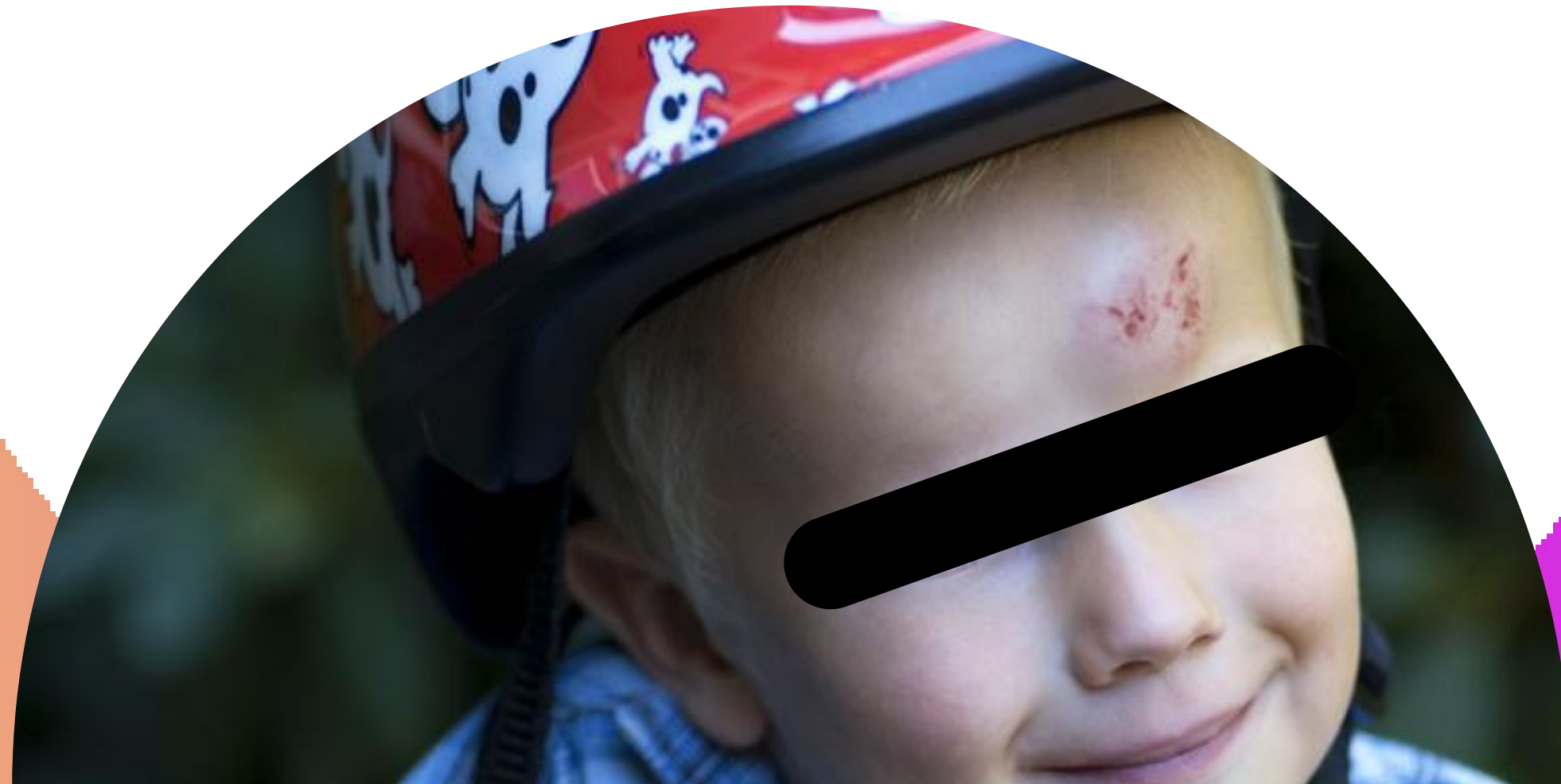





KCP

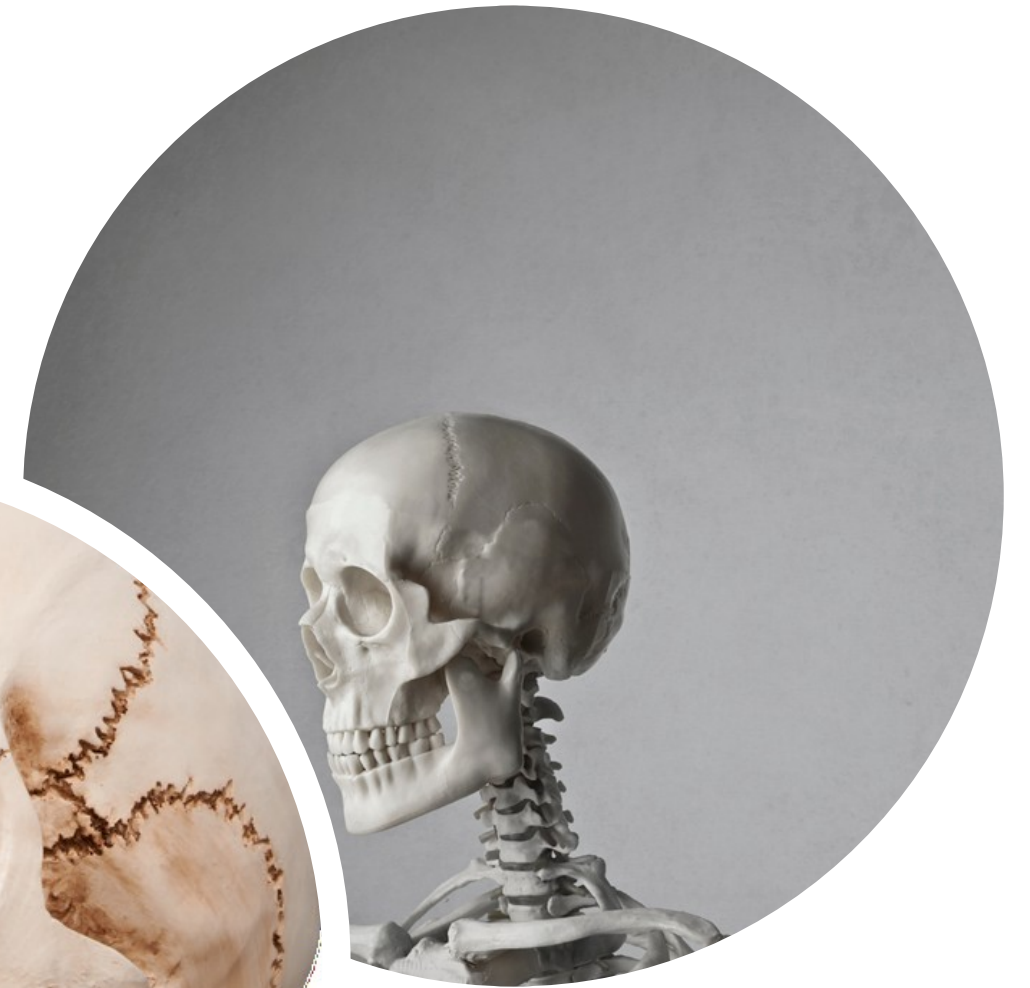
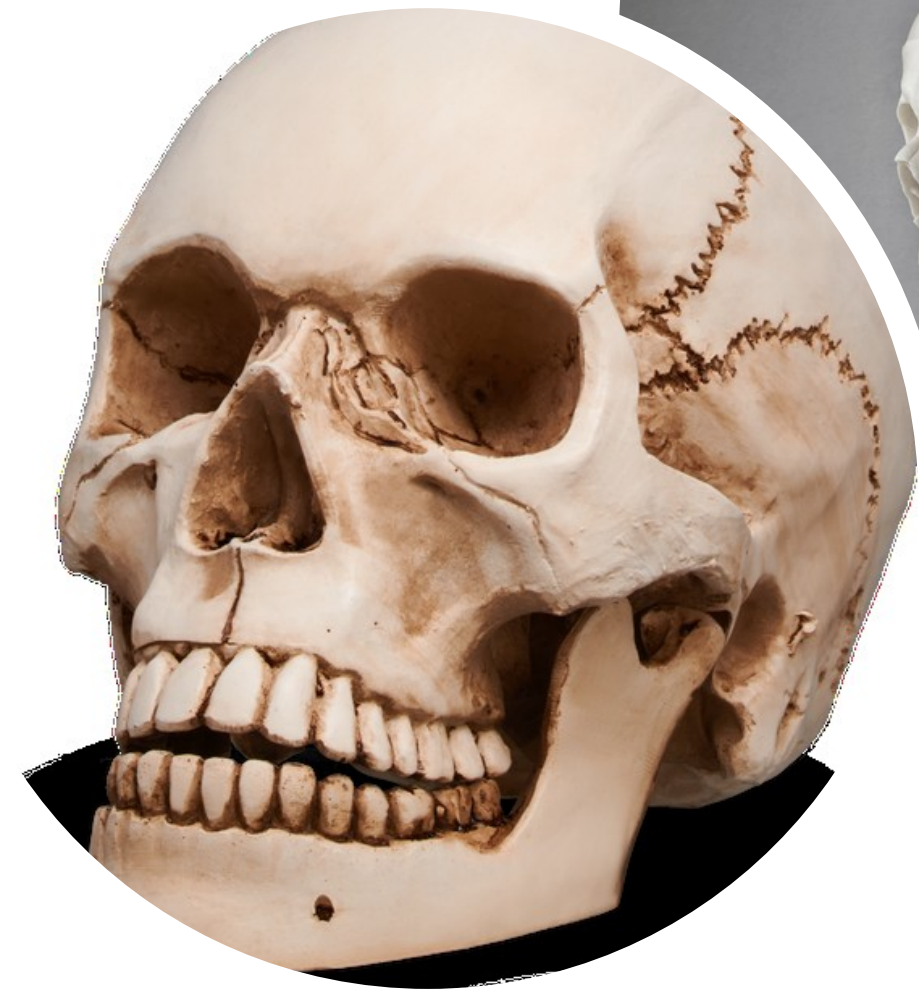
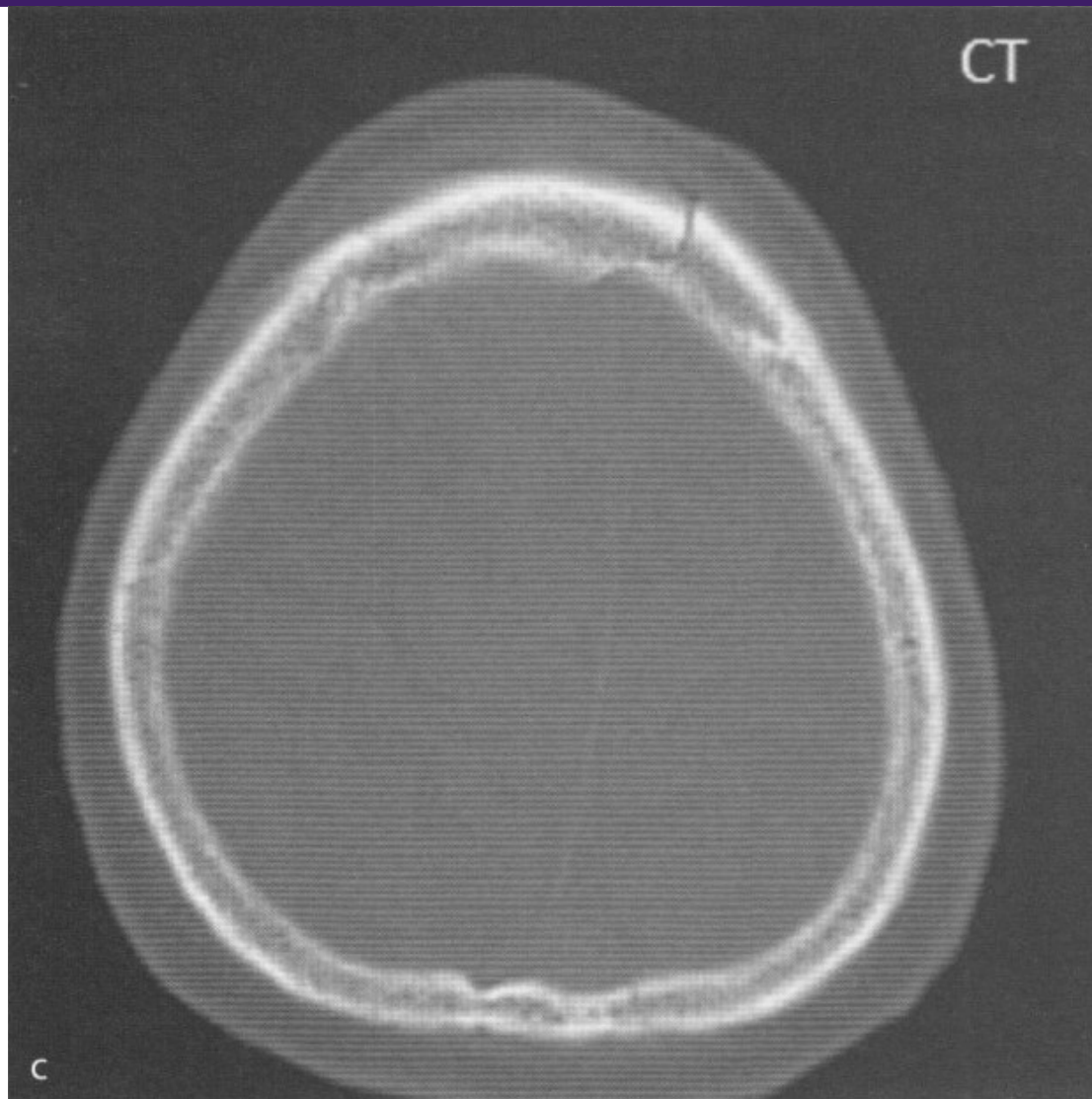


# poranění



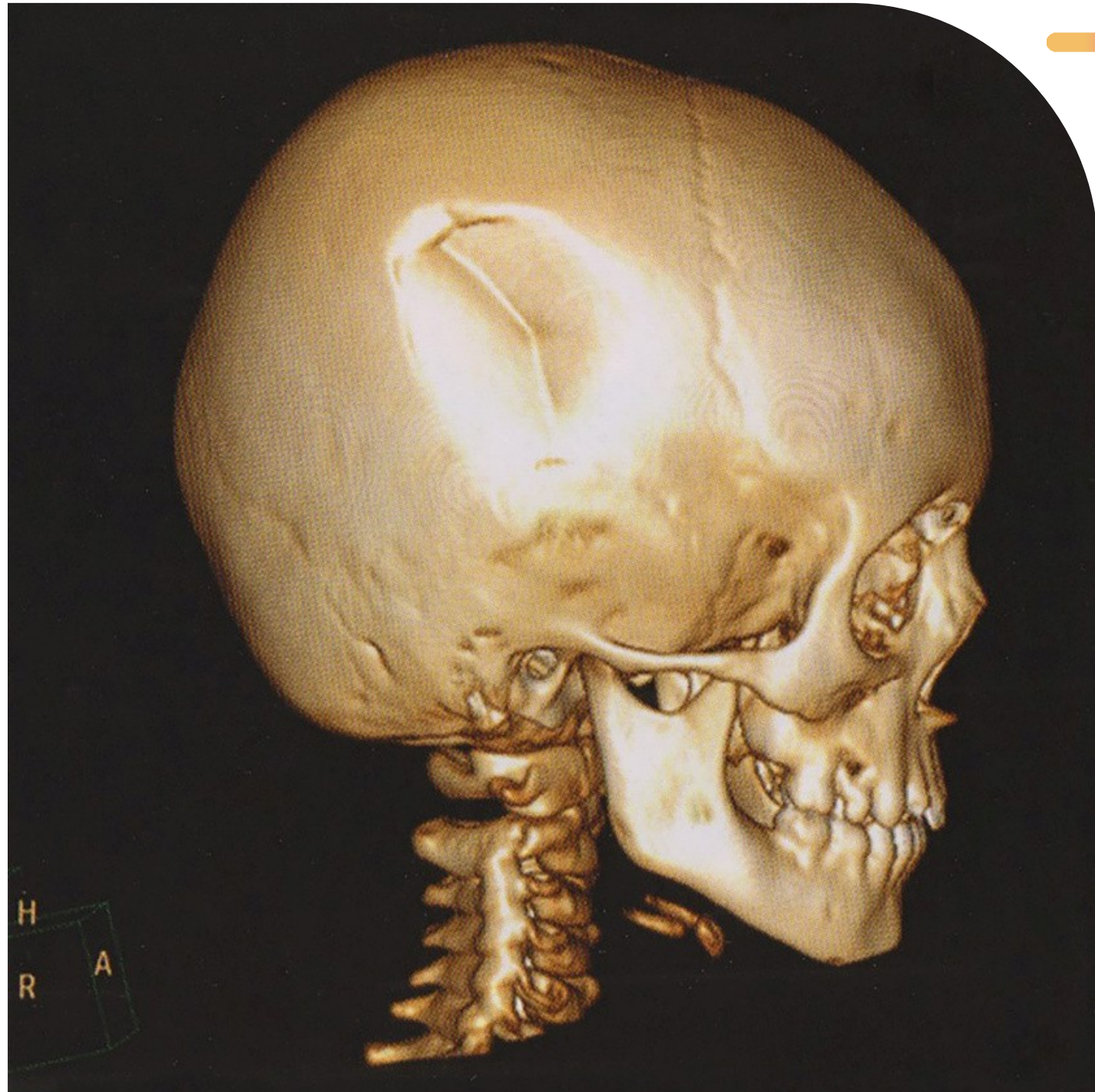





**Fraktura lebky**



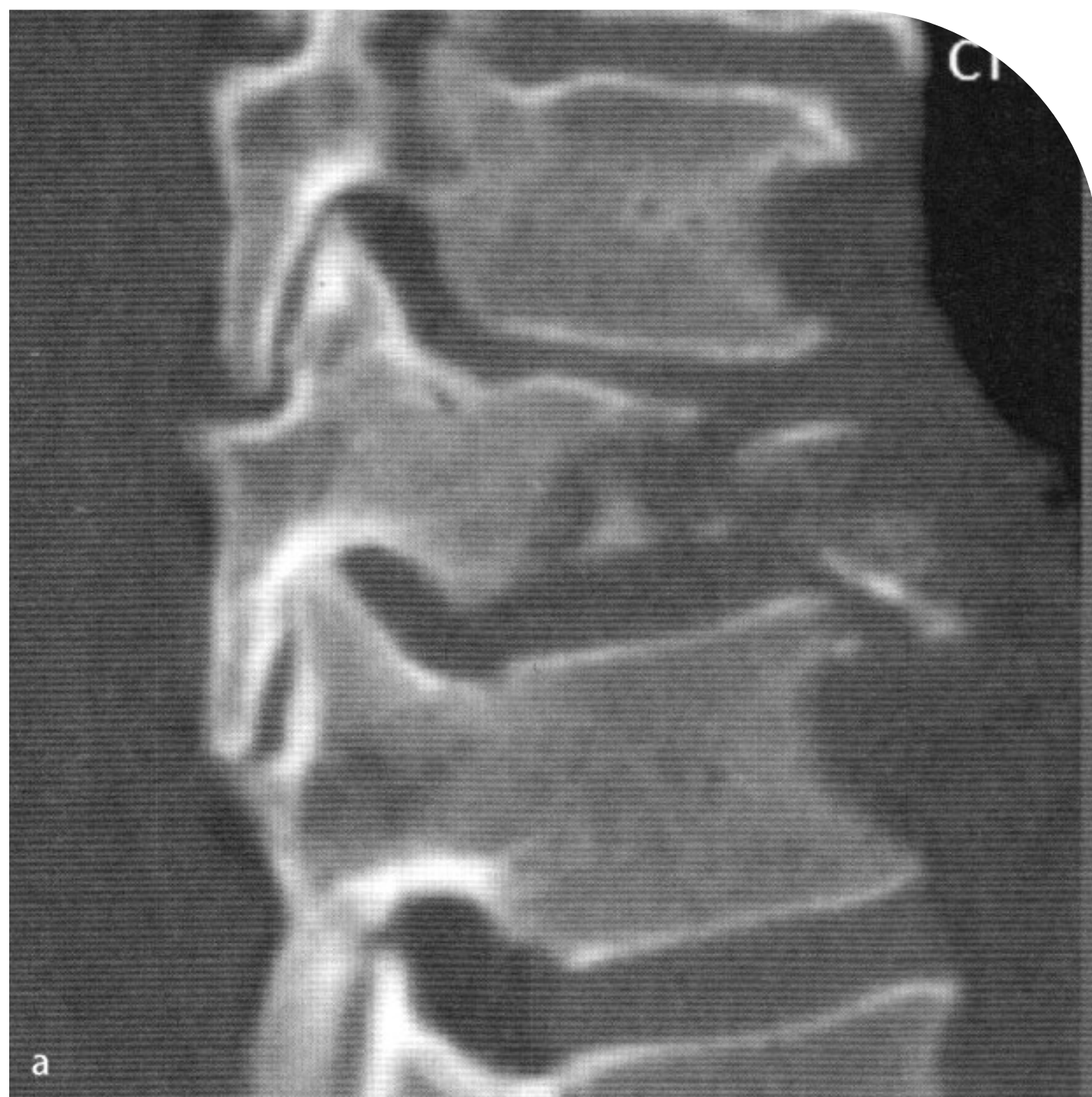

Ibi- 3DCT





**třířtivá**



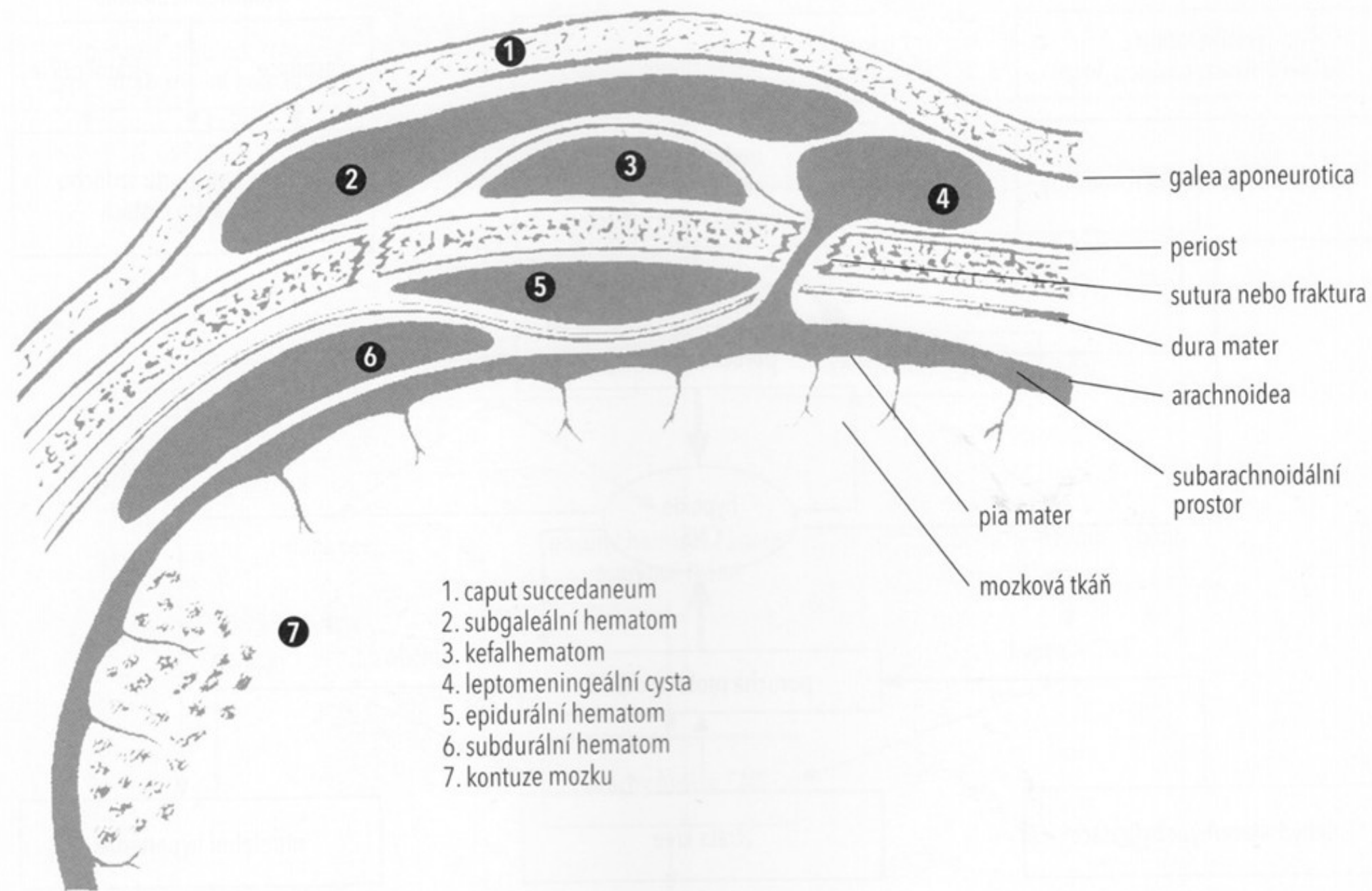




hematoma







1. caput succedaneum
2. subgaleální hematom
3. kefalhematom
4. leptomeningeální cysta
5. epidurální hematom
6. subdurální hematom
7. kontuze mozku

galea aponeurotica

periost

sutura nebo fraktura

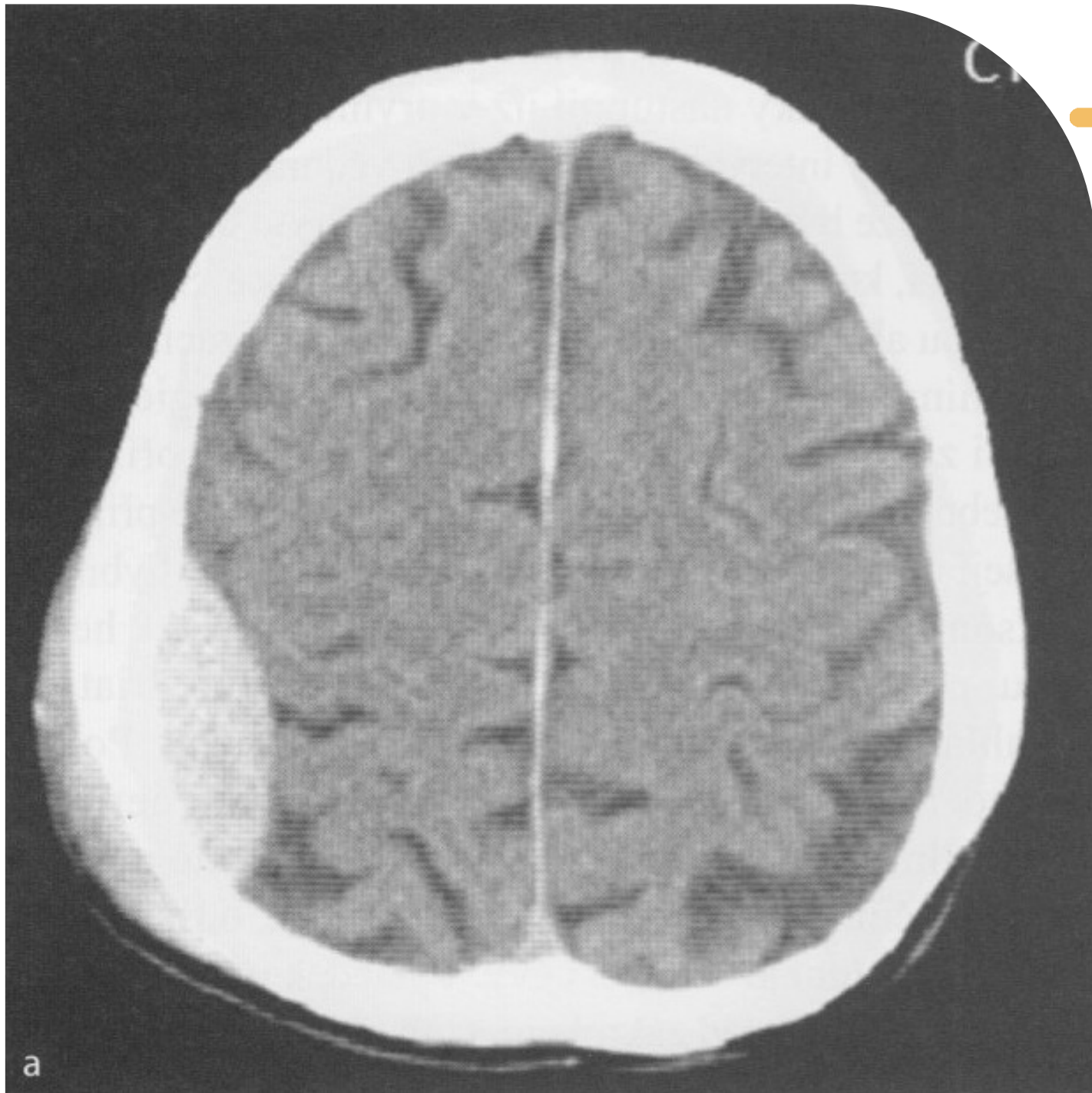dura mater

arachnoidea

subarachnoidální  
prostor


pia mater

mozková tkáň



hematom

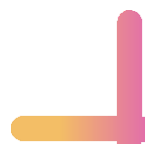



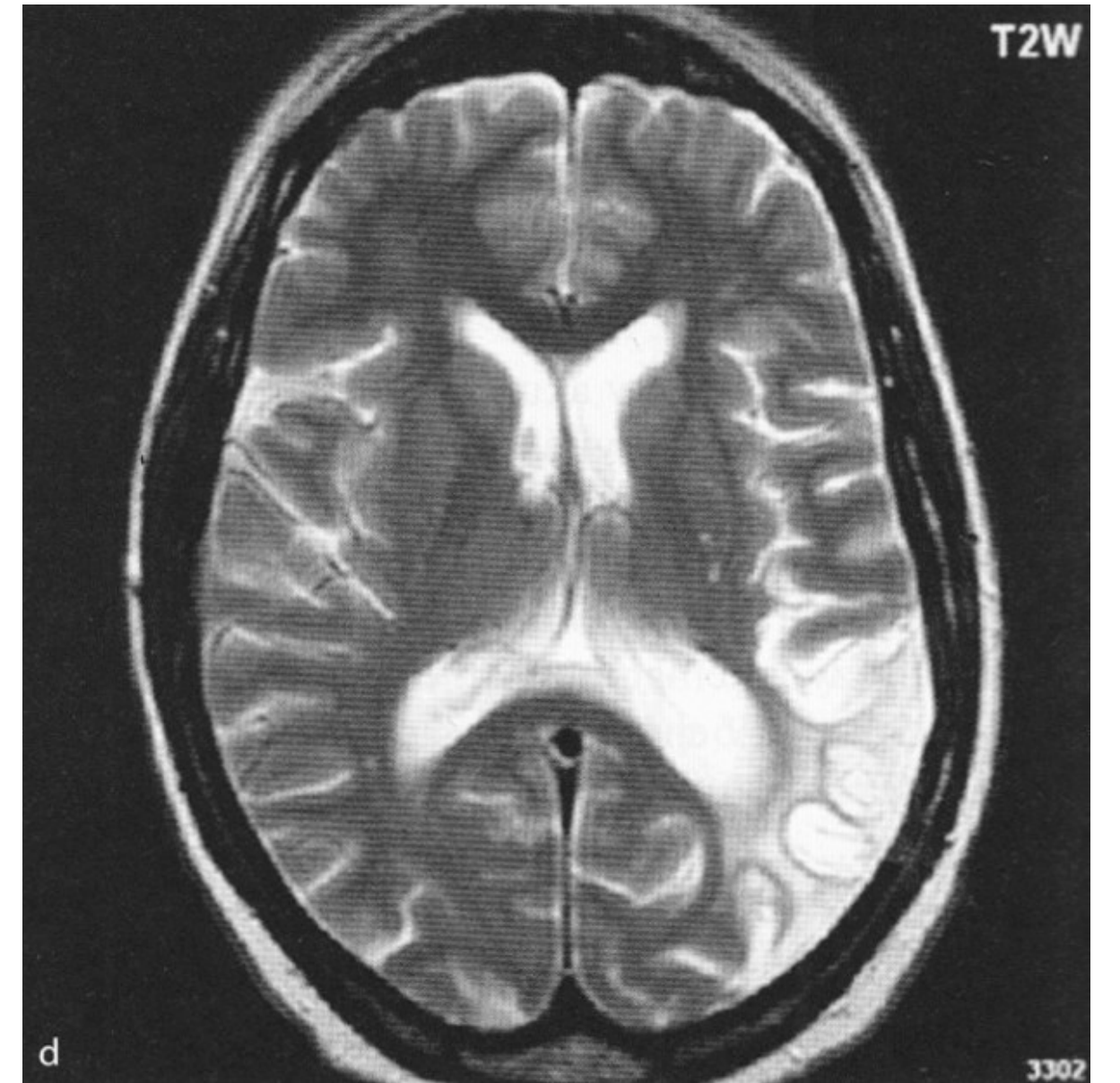
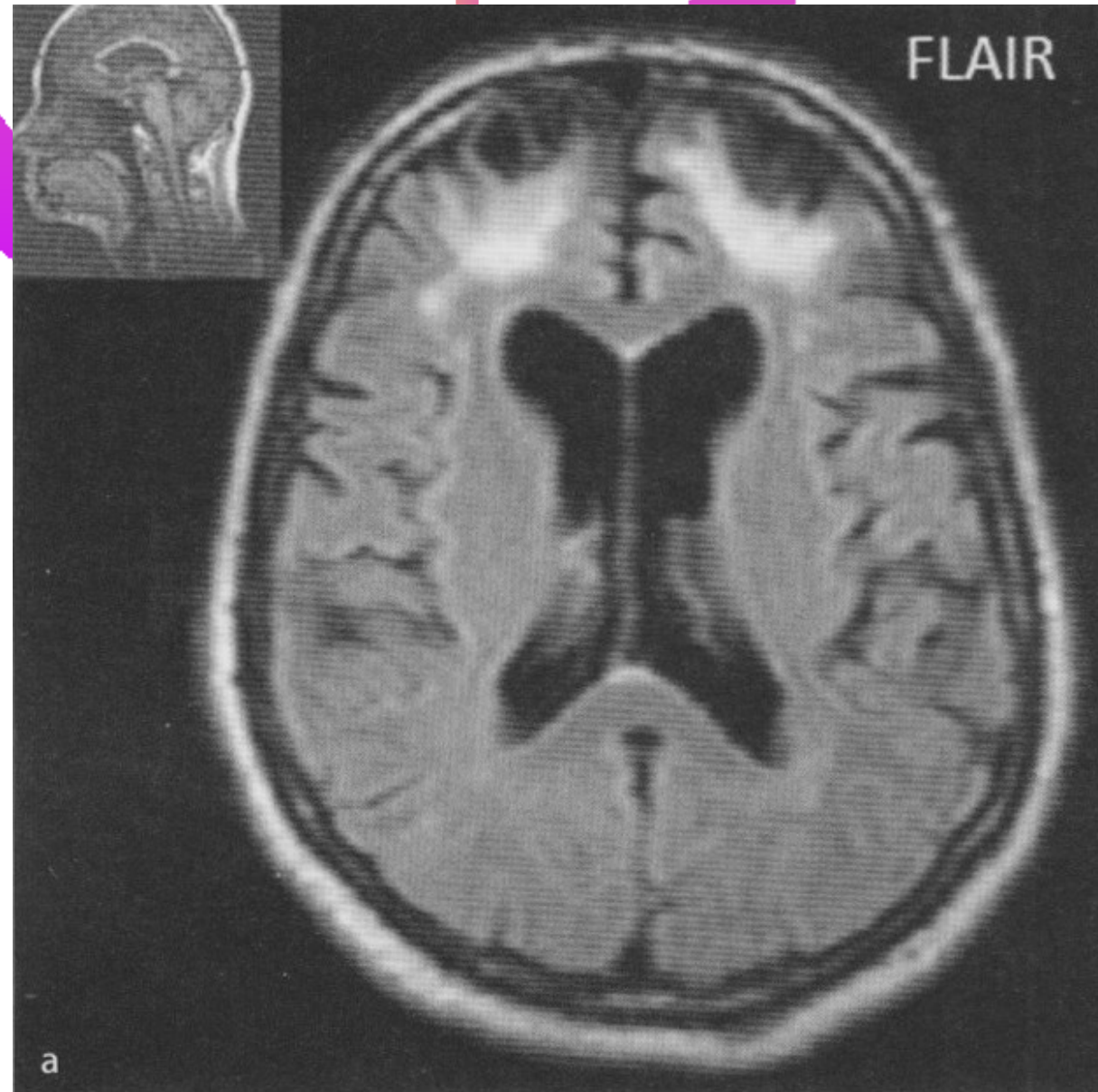
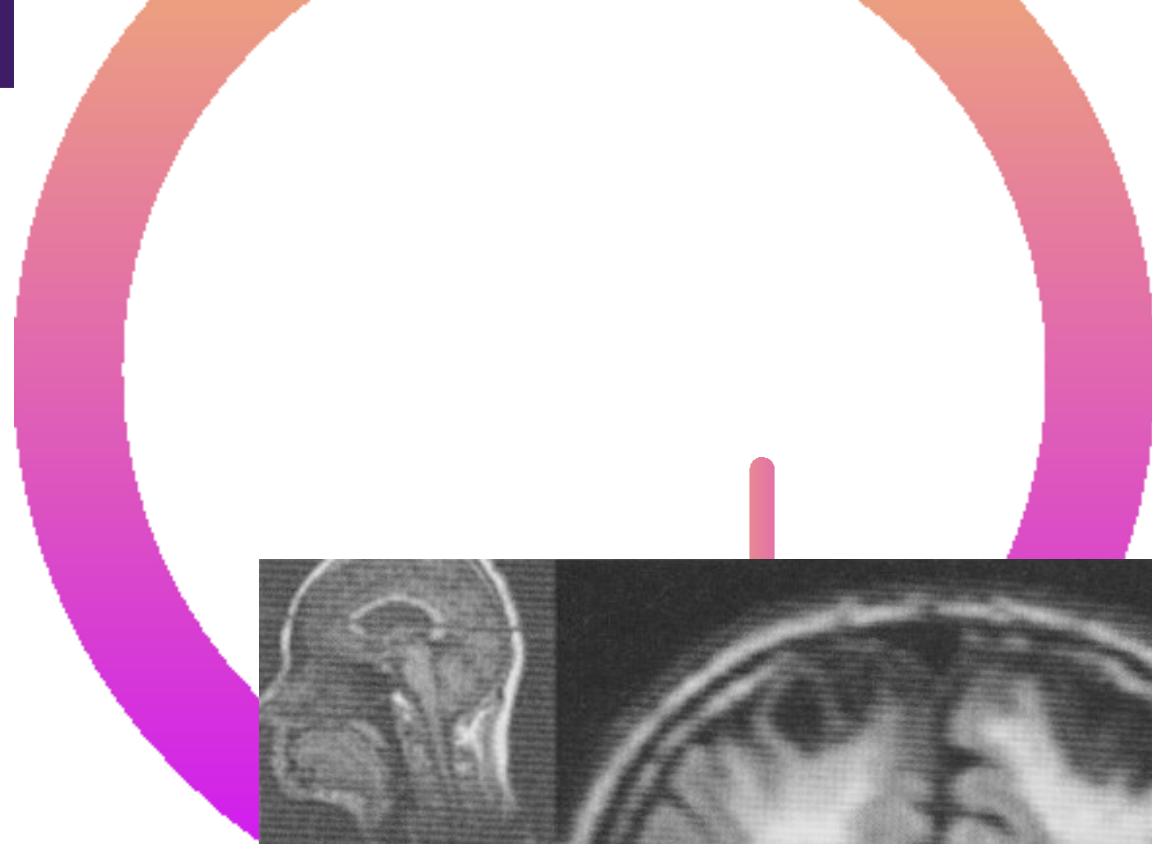
**mozková**



mozku





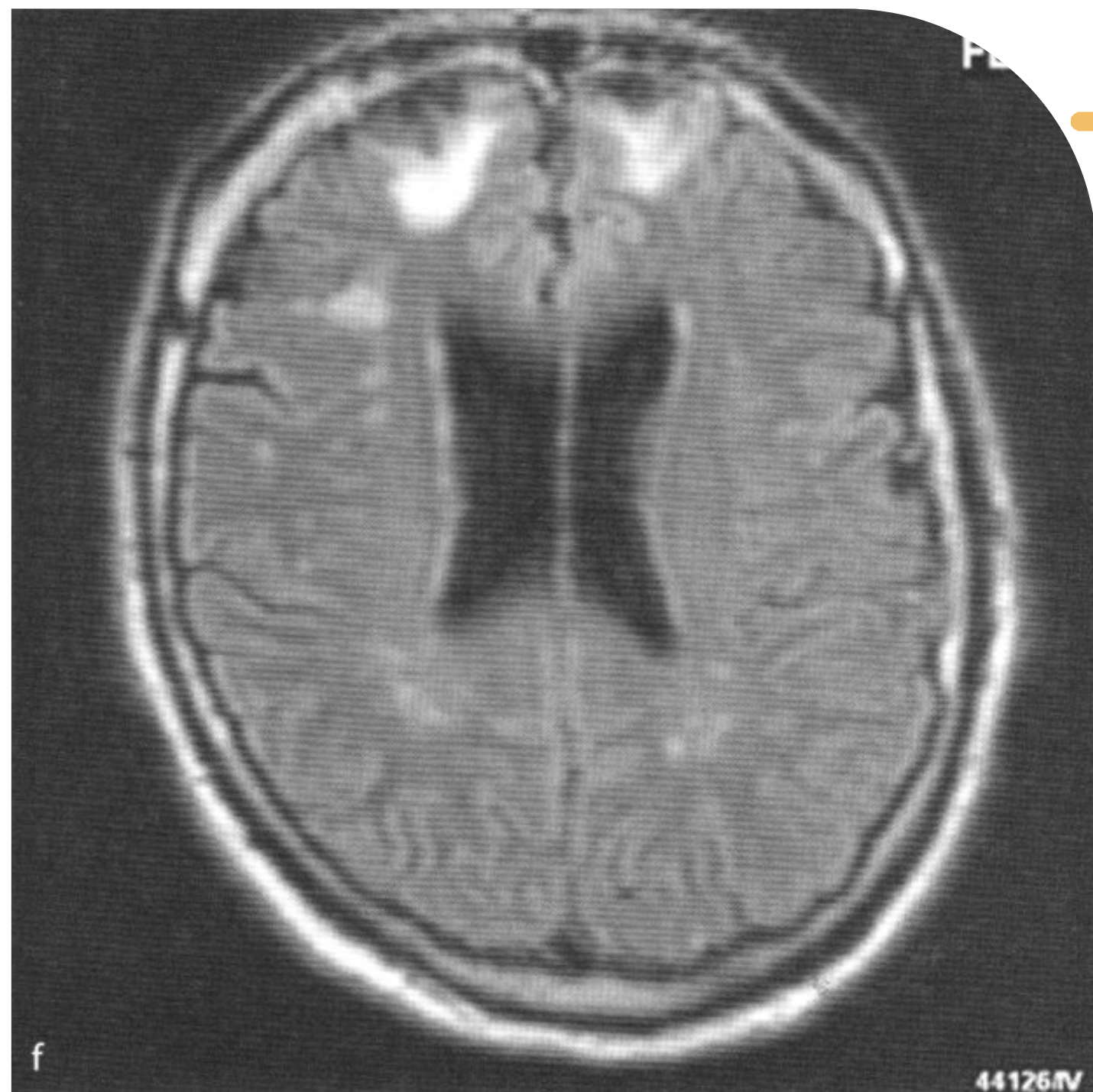




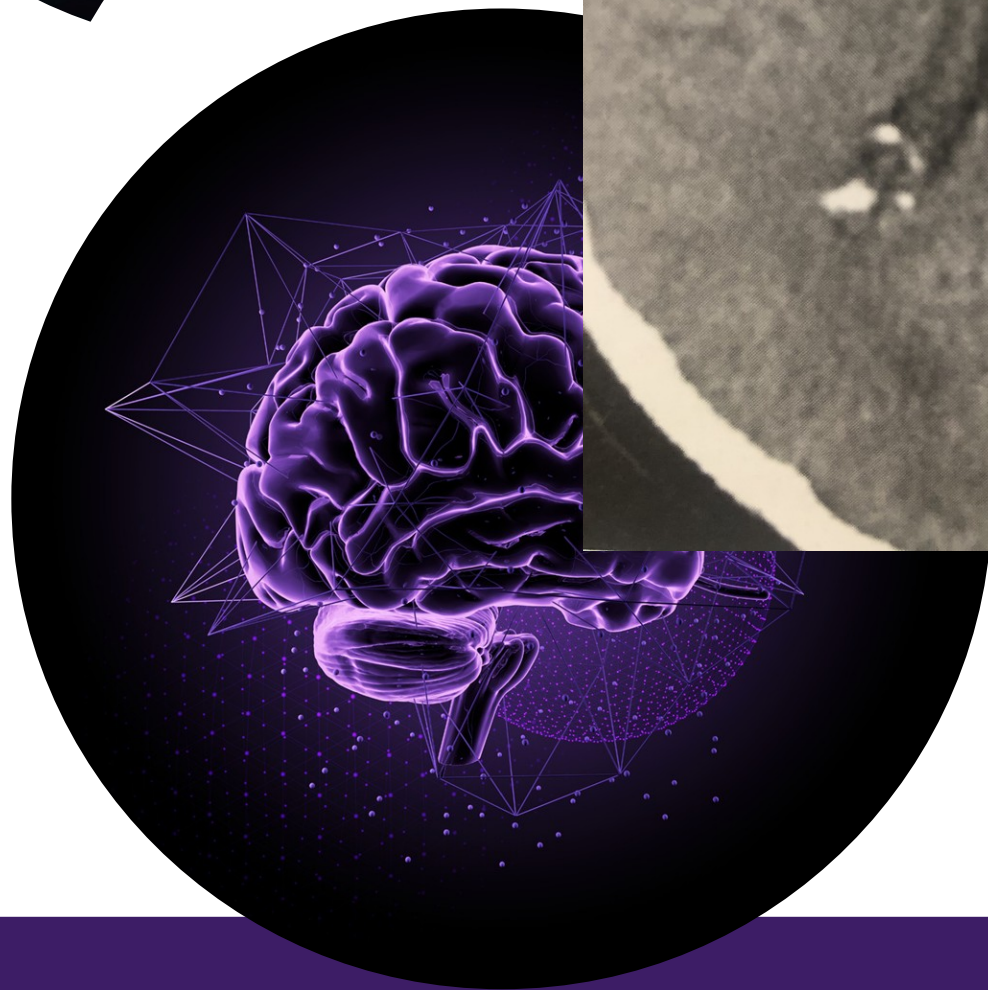
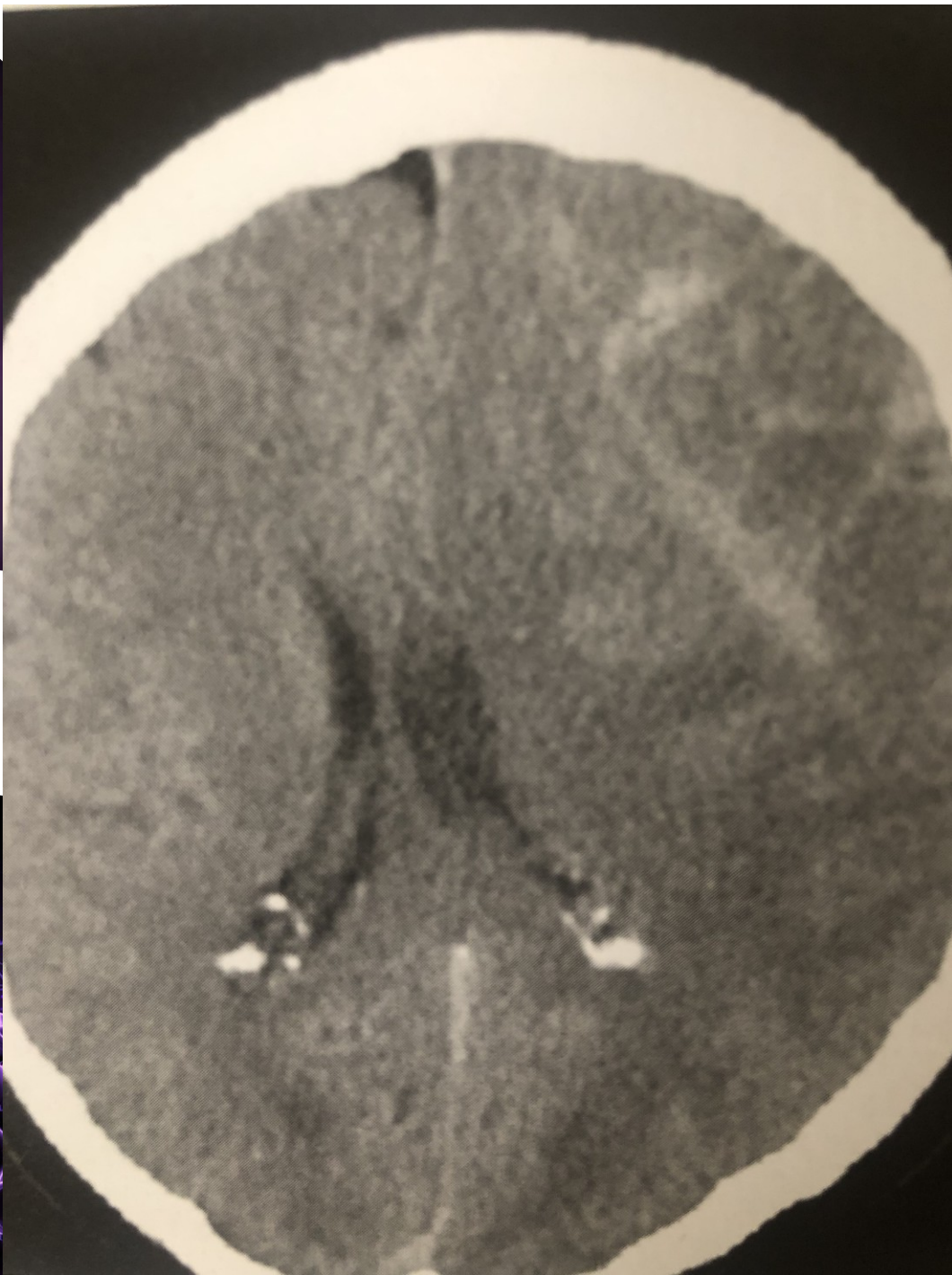
# axonální poranění







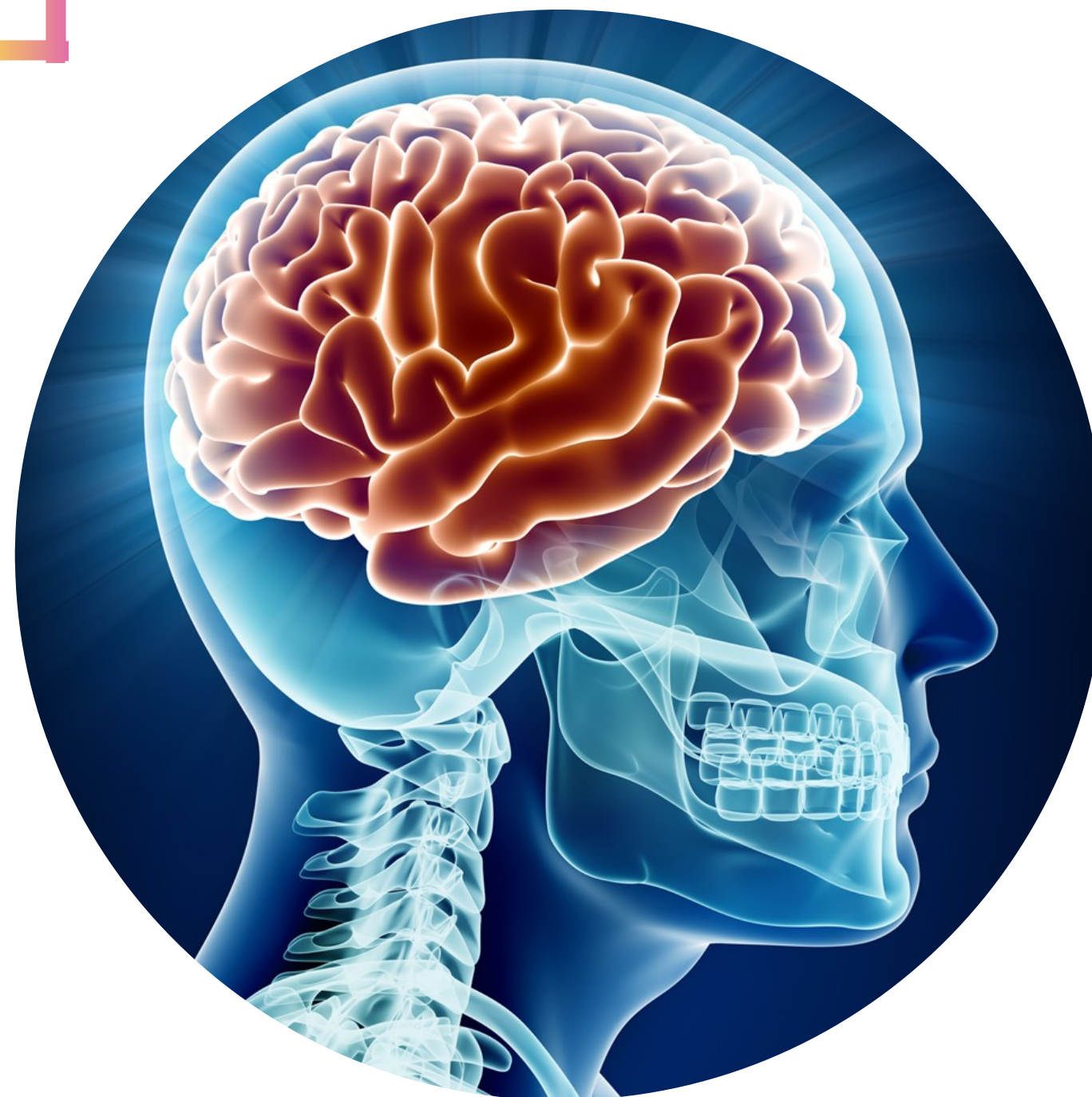
**axonální poranění**








# poranění





# týraného dítěte



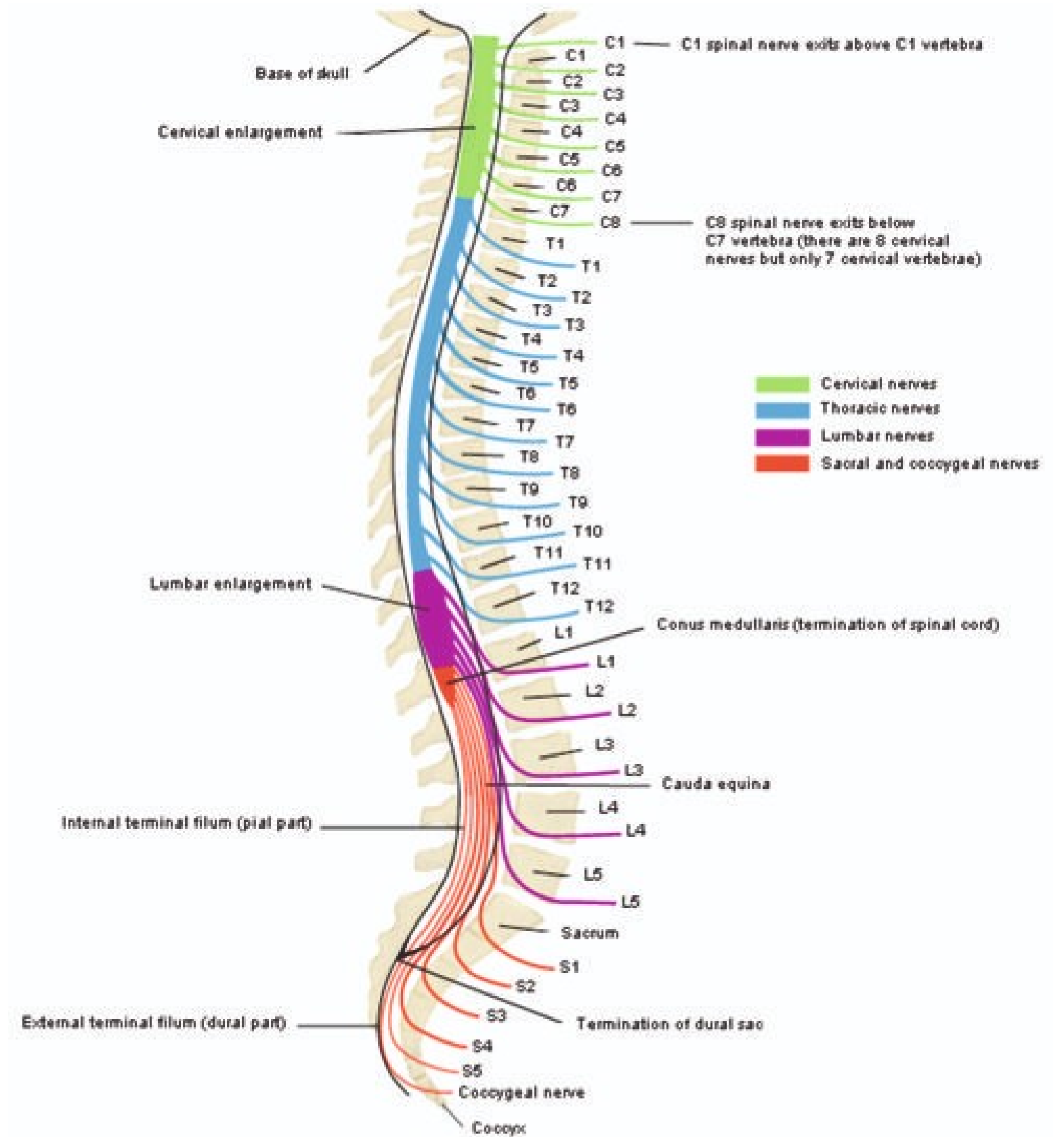


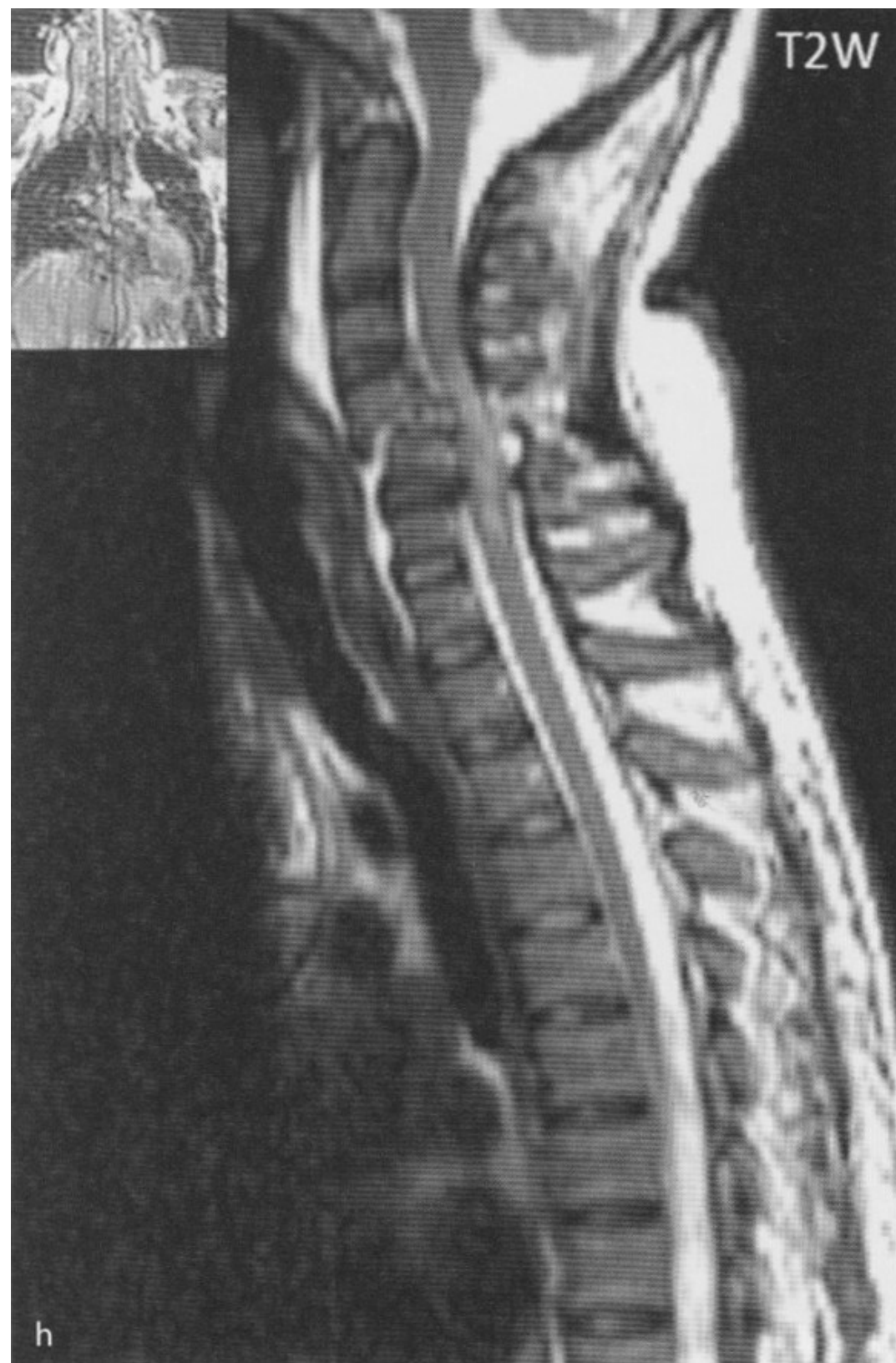
**míchy**





[Seidl Z., Diagnostická radiologie, Grada Publishing, 2014, ISBN 978-80-247-4546-6, str408, obr, II.4.2a](#)

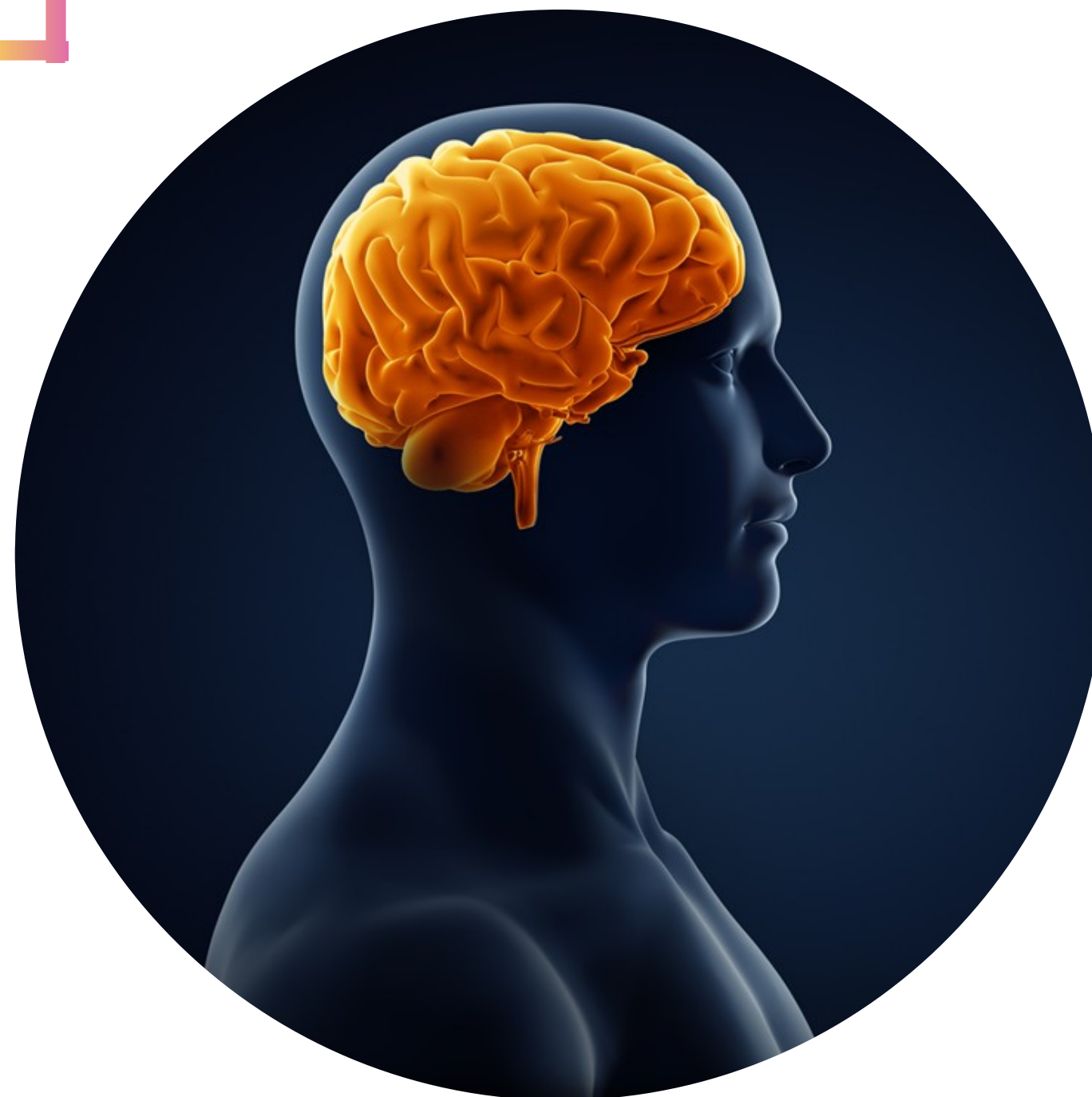





[Seidl Z., Diagnostická radiologie, Grada Publishing, 2014, ISBN 978-80-247-4546-6, str410, obr, II.4.2h](#)



# míšní léze









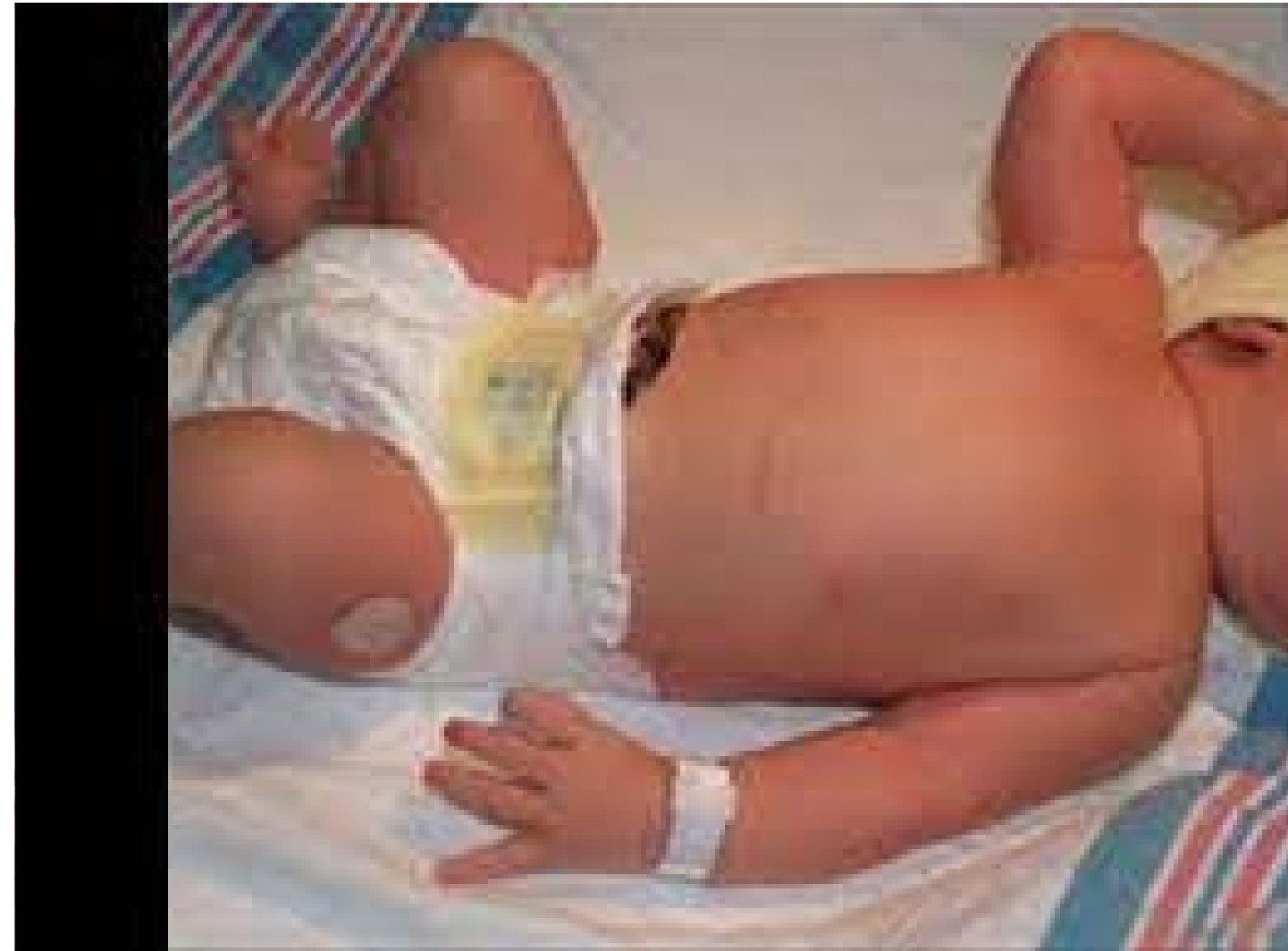
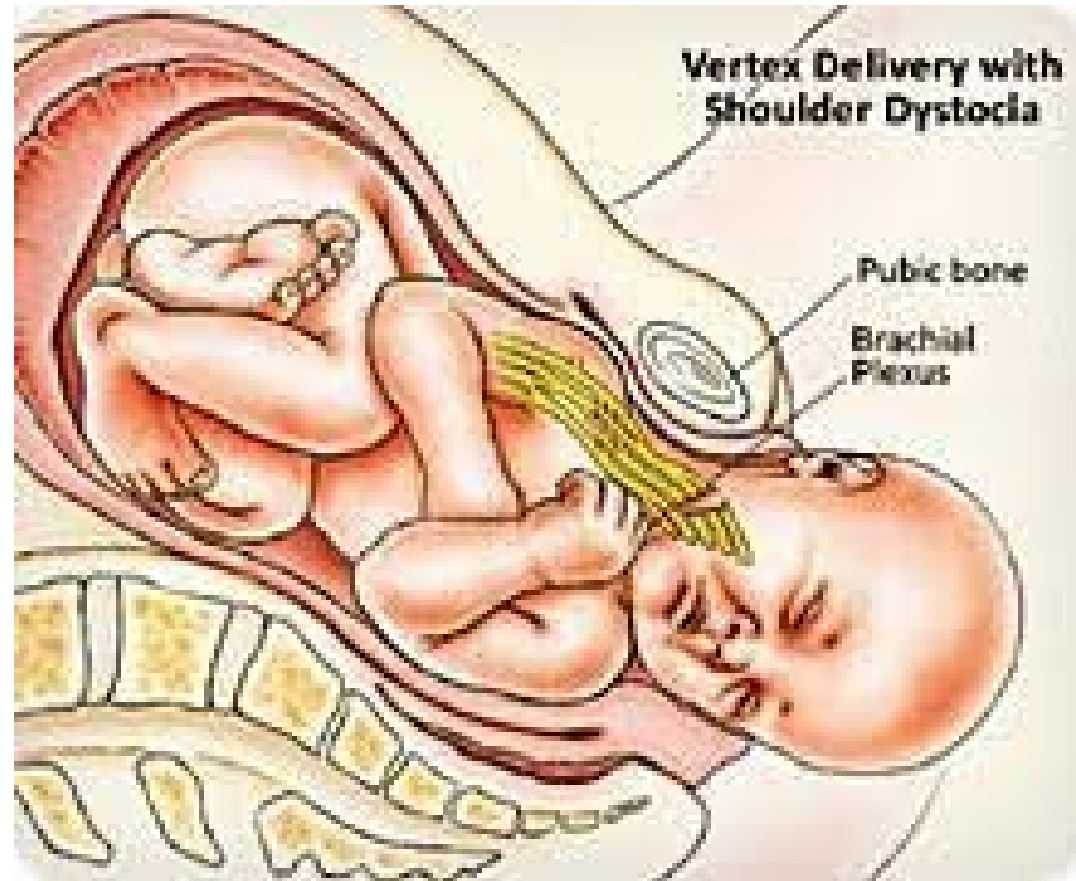




**brachiálního plexu**

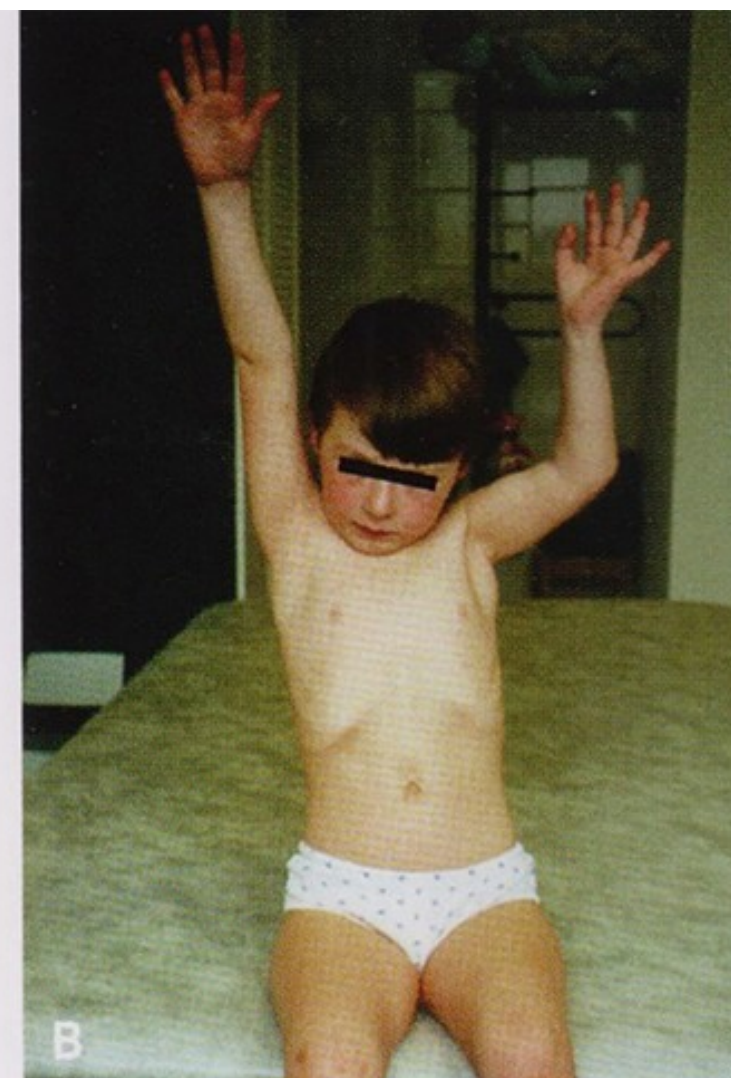
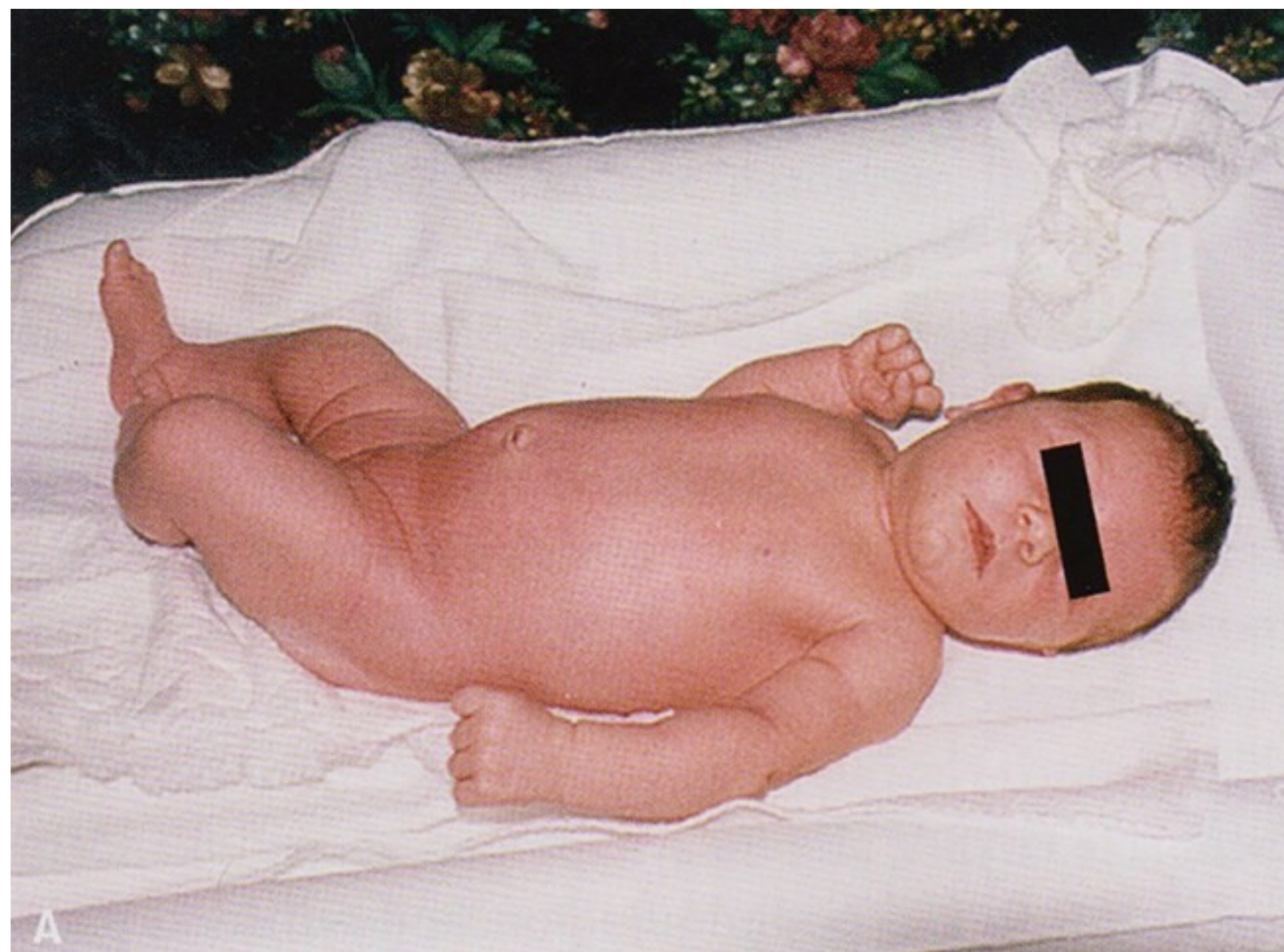







[Nevšimalová S., Dětská neurologie, Galén 2021, ISBN 978-80-7492-557-3, str 111, obr.3-16](#)





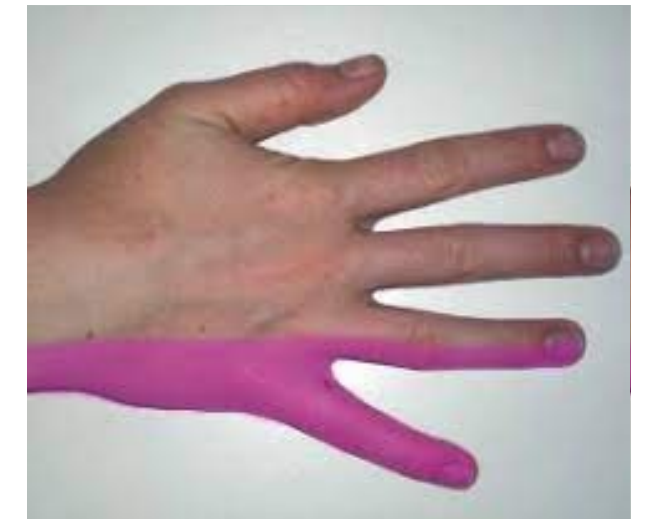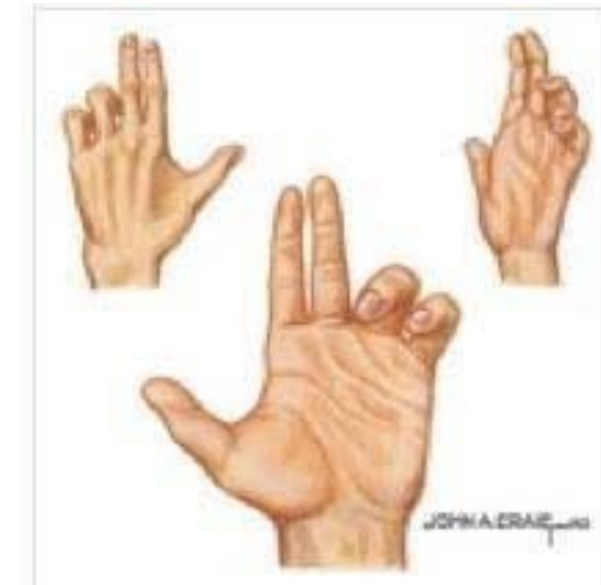
# brachiálního plexu





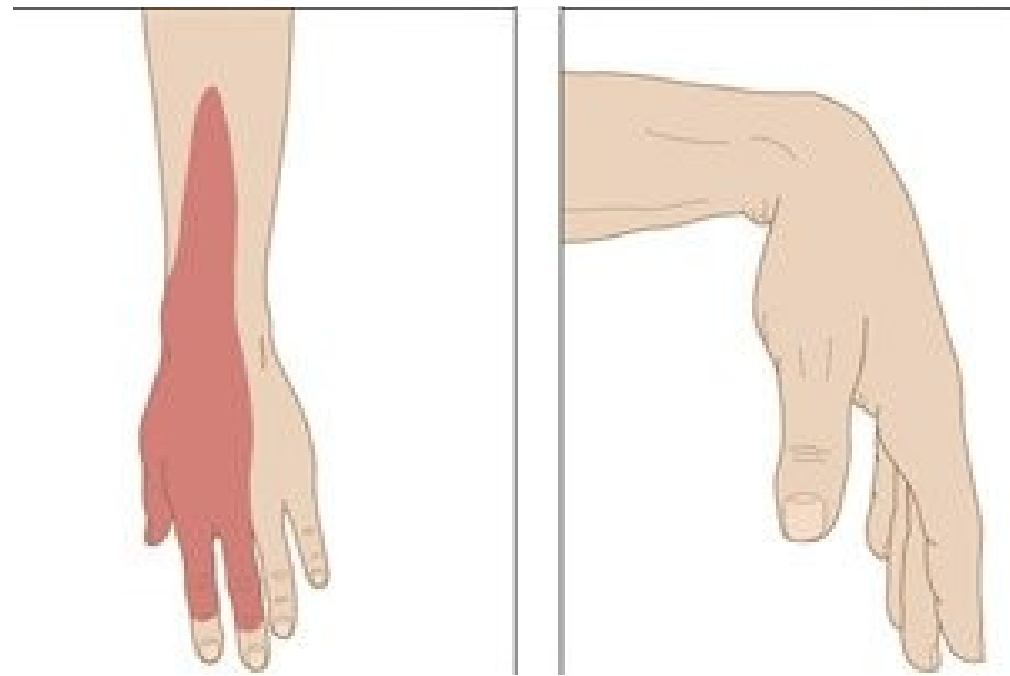


**n. ulnaris**

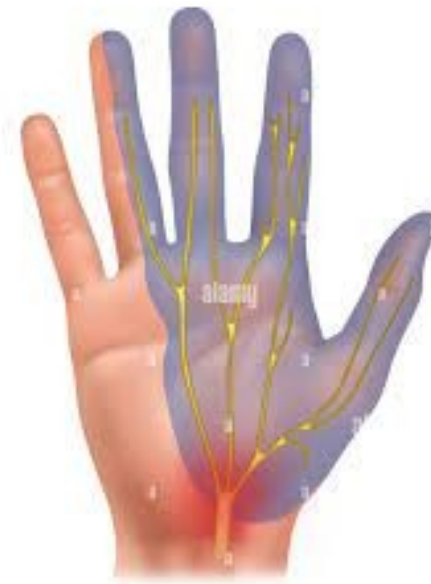



# n. radialis



# n. medianus C5-8, Th1



alamy

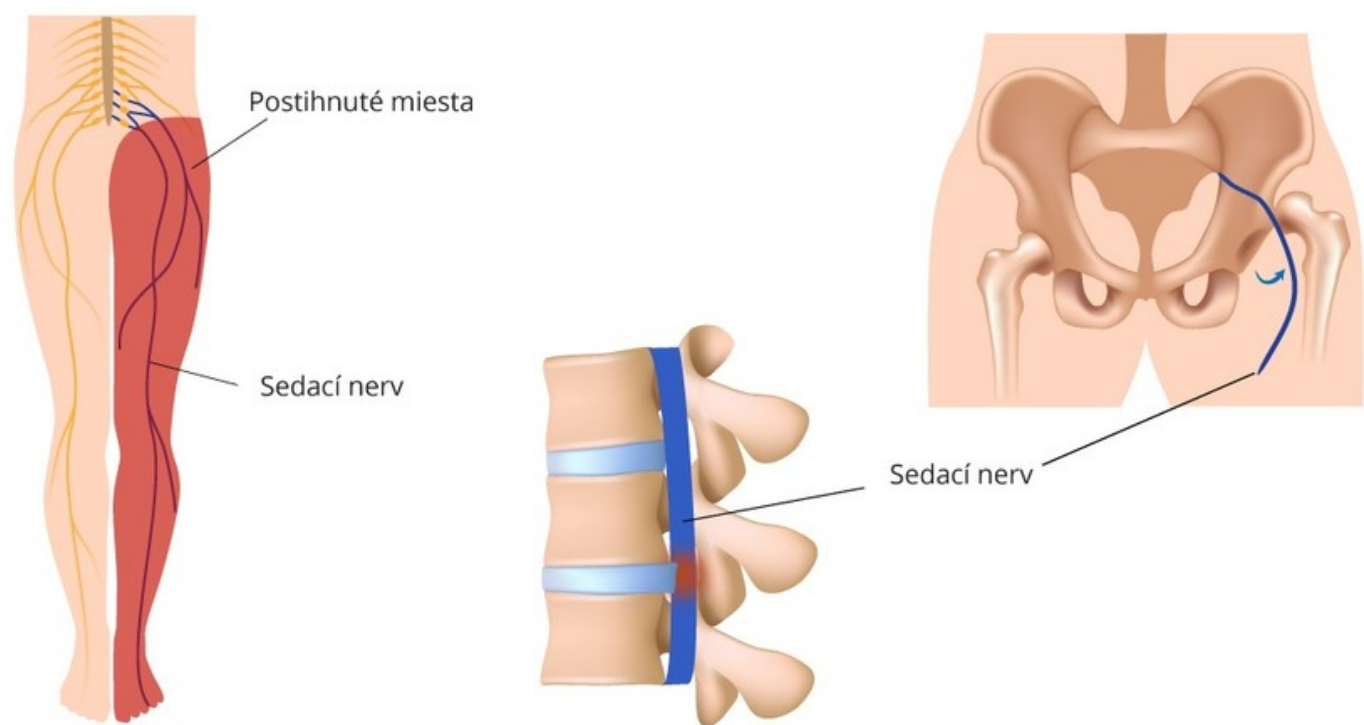




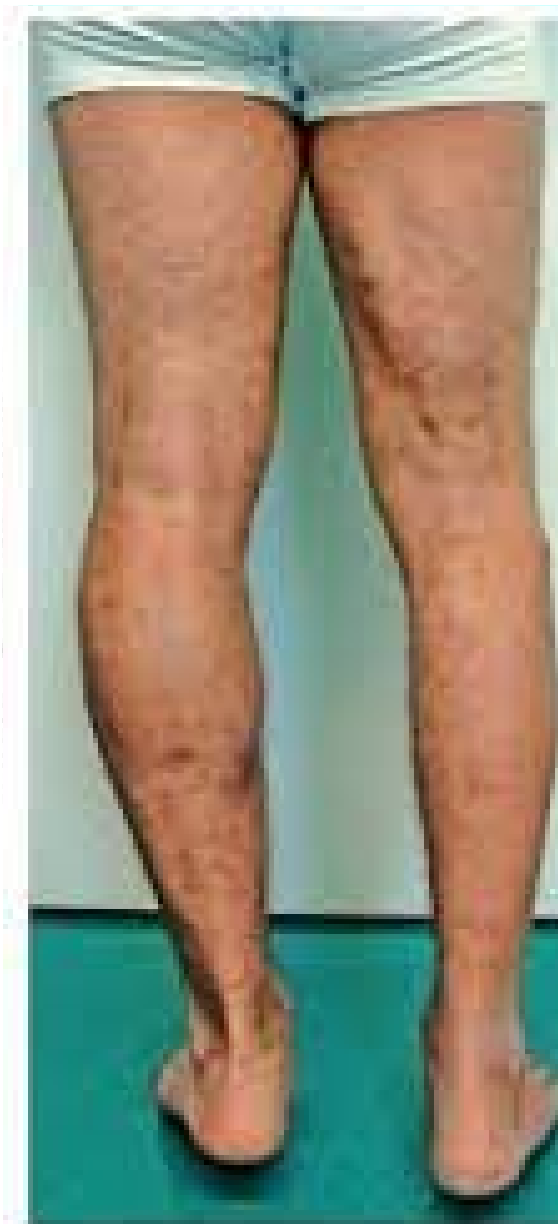

## Špatná volba místa pro injekci do hýždě, porod KP, nehody

### Zápal sedacieho nervu - ischias



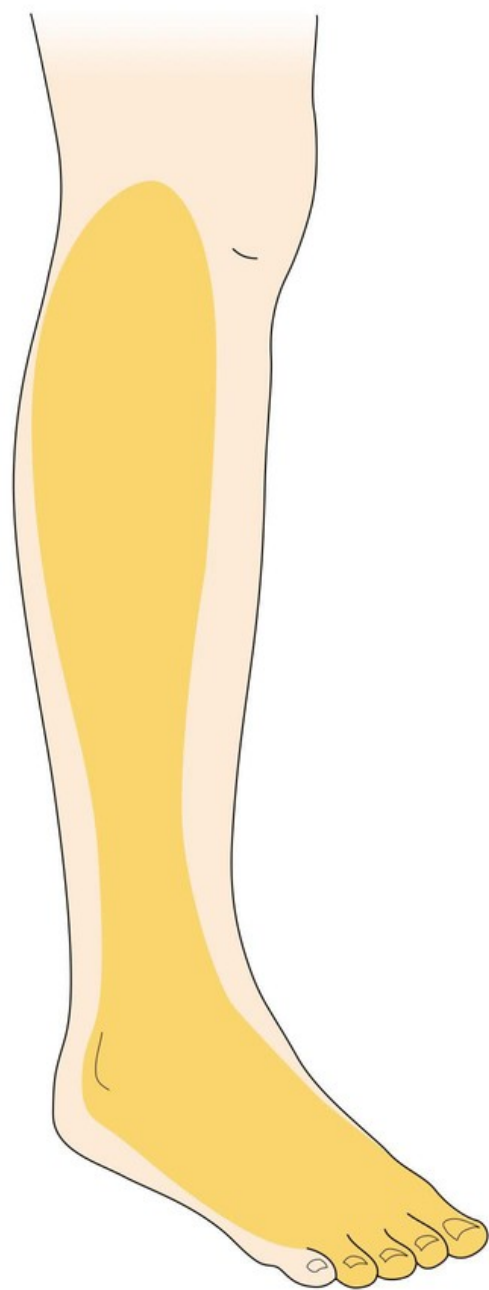
symptomy.sk



*Obra 1. Pacient z kazuistiky 33 mesiaci po rekonstrukcii NI sprava v úrovni stehna. Pravy bicep hypotroficky, tonus svalstva zachovaný, postaví sa na špičku. Jazyk po revízií patrná na stehne, na oboch lýtkách drobné jazyky po odberoch na nervoch.*



Trauma nervu u hlavičky fibuly , ortopedické výkony v oblasti kolene, inverze nohy v kotníku



© Birgitte Lerche-Barlach 2012

