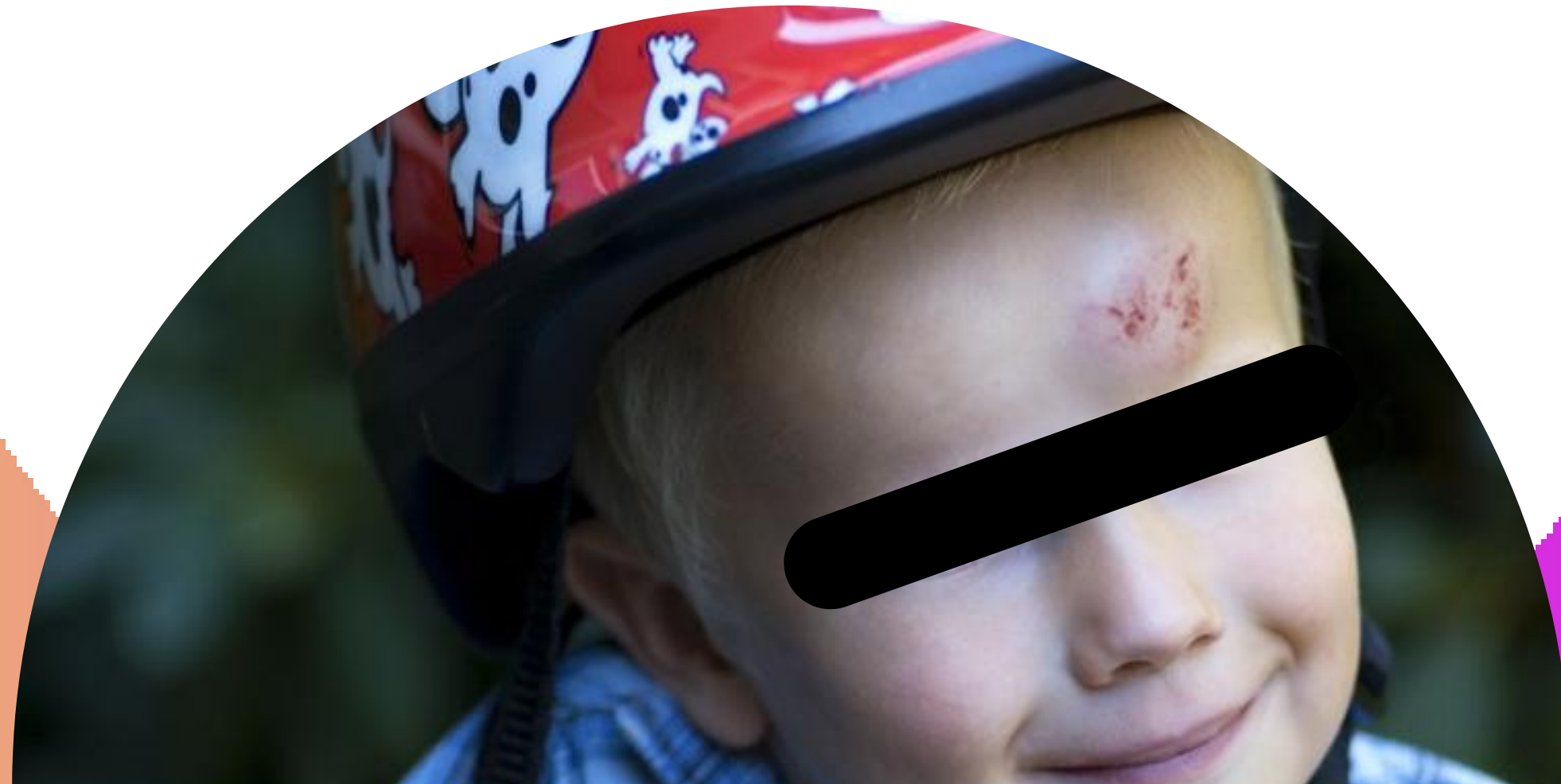



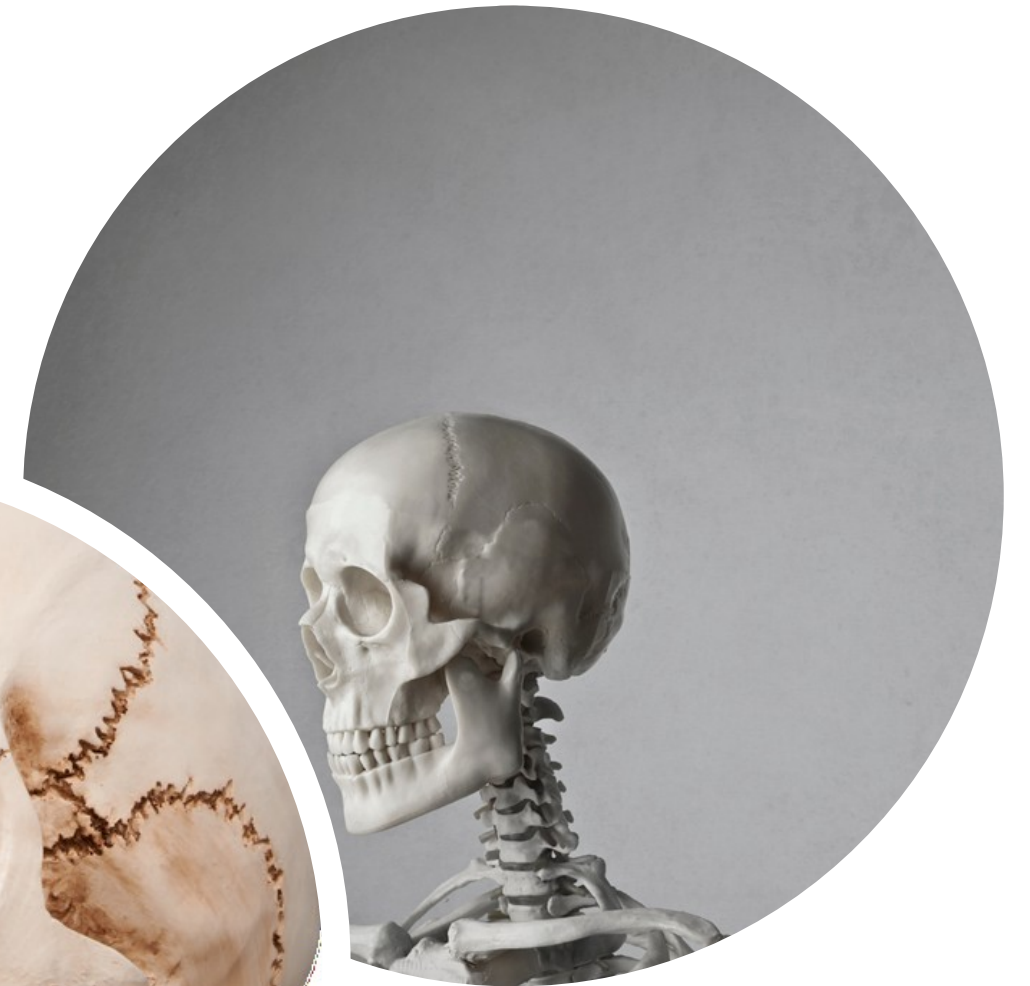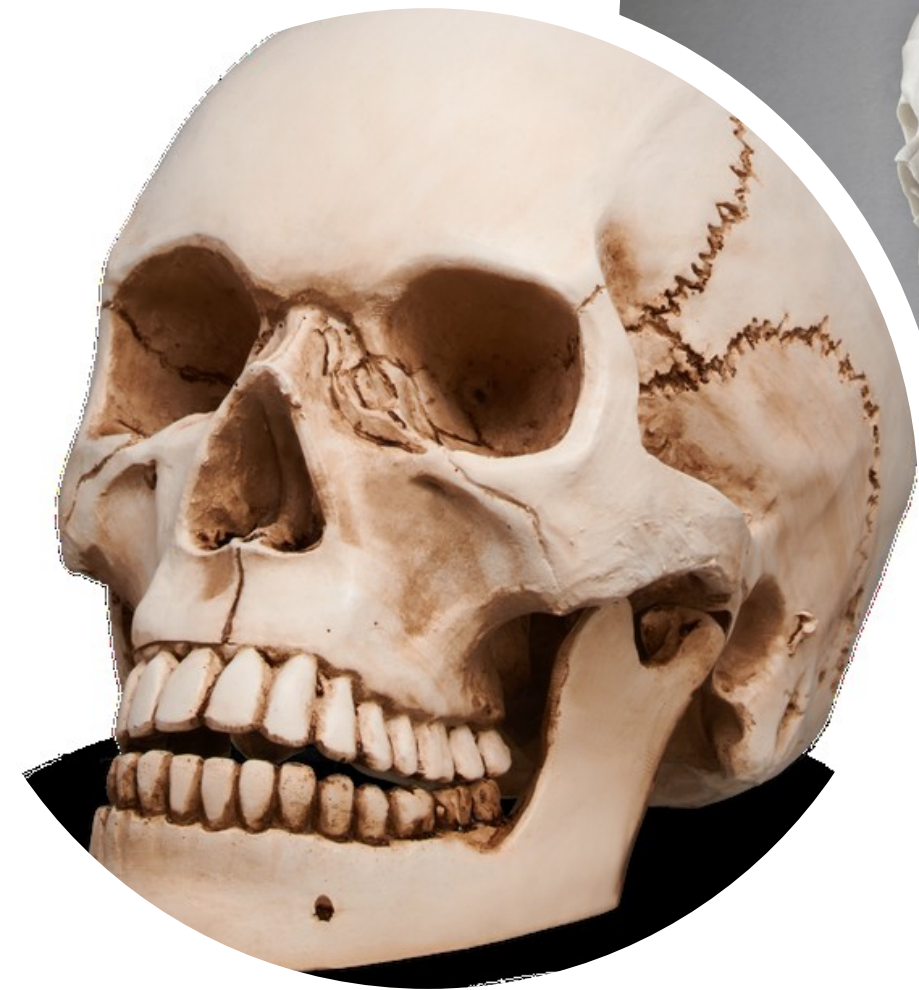KCP

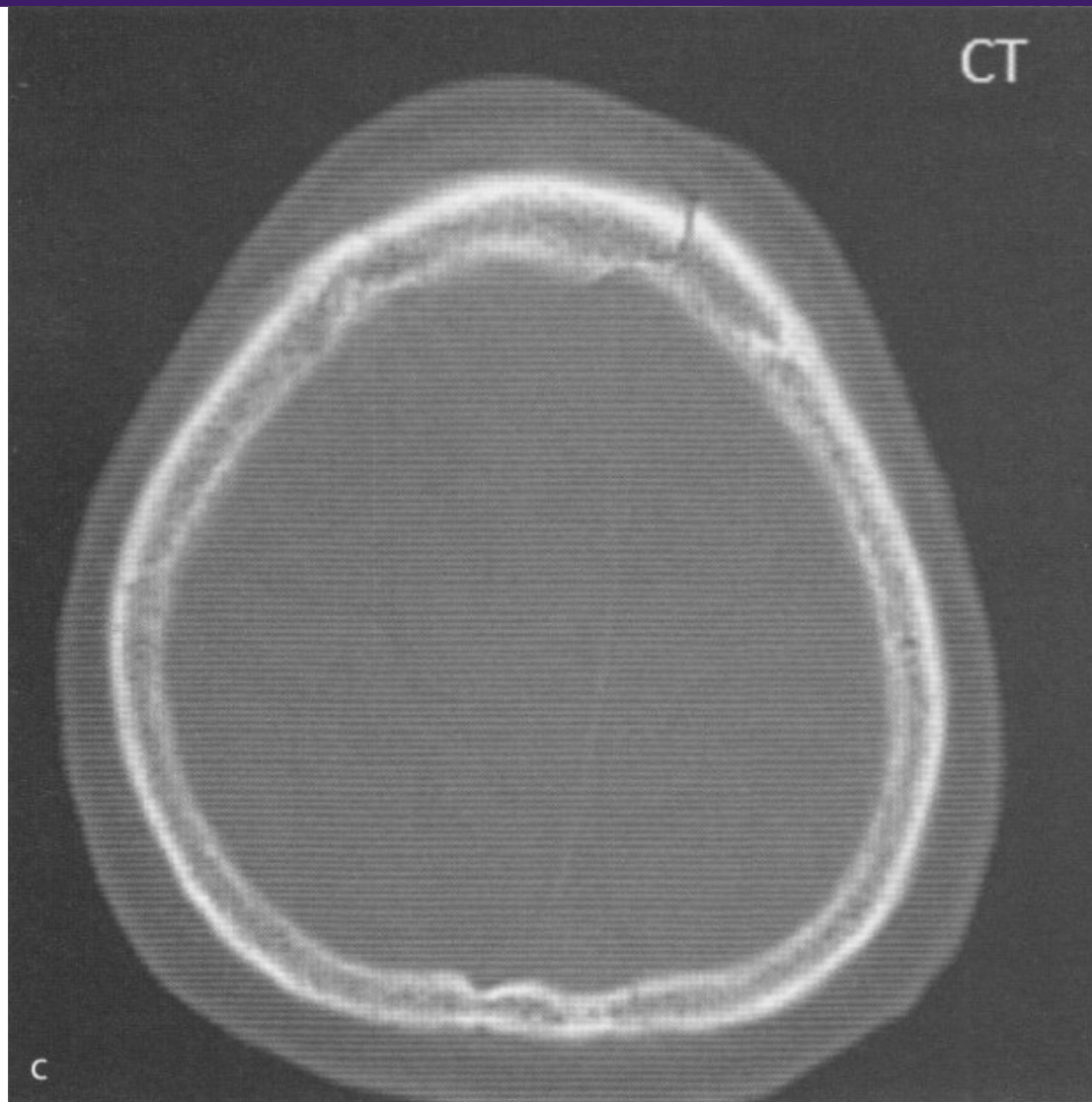




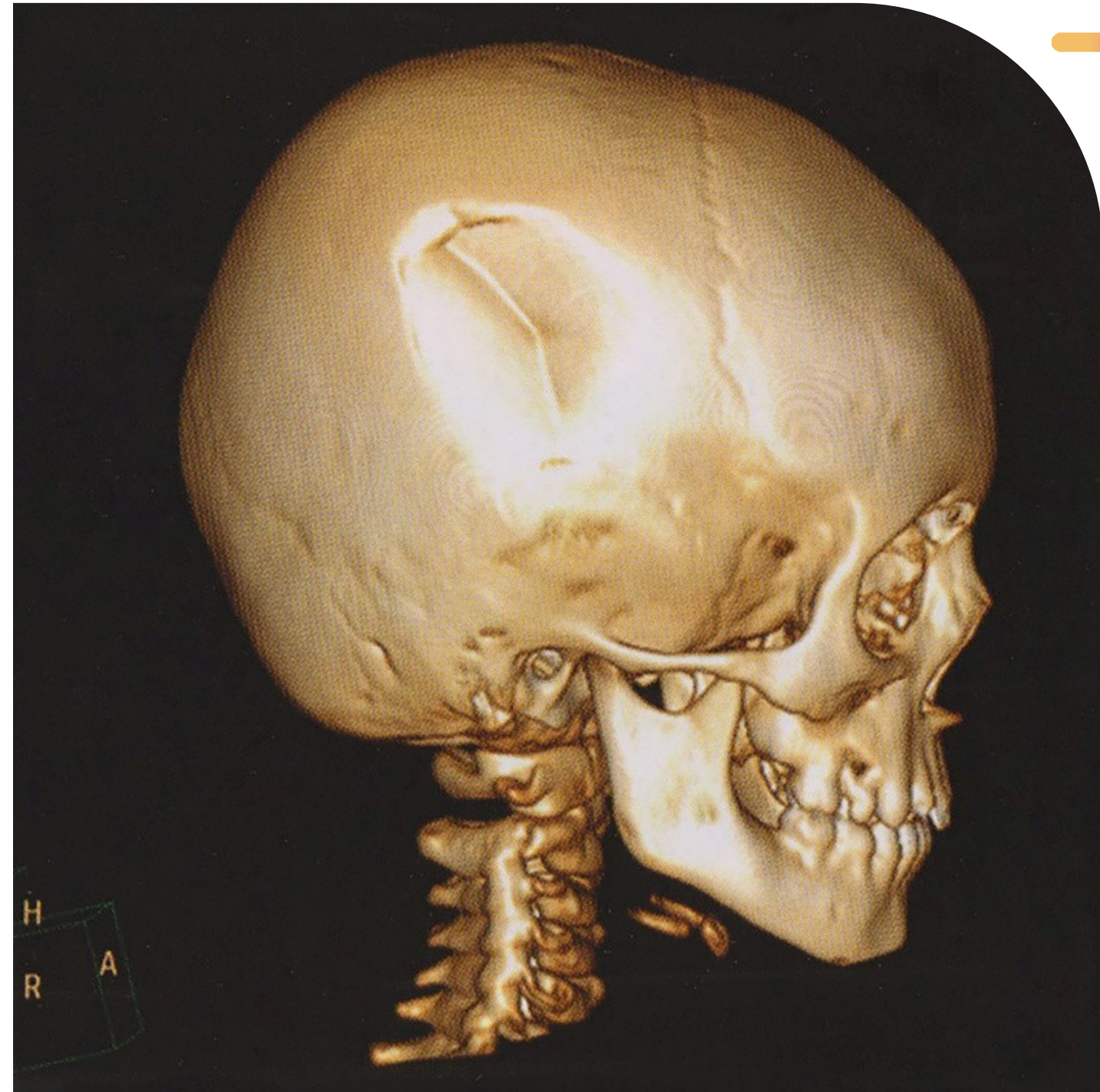poranění







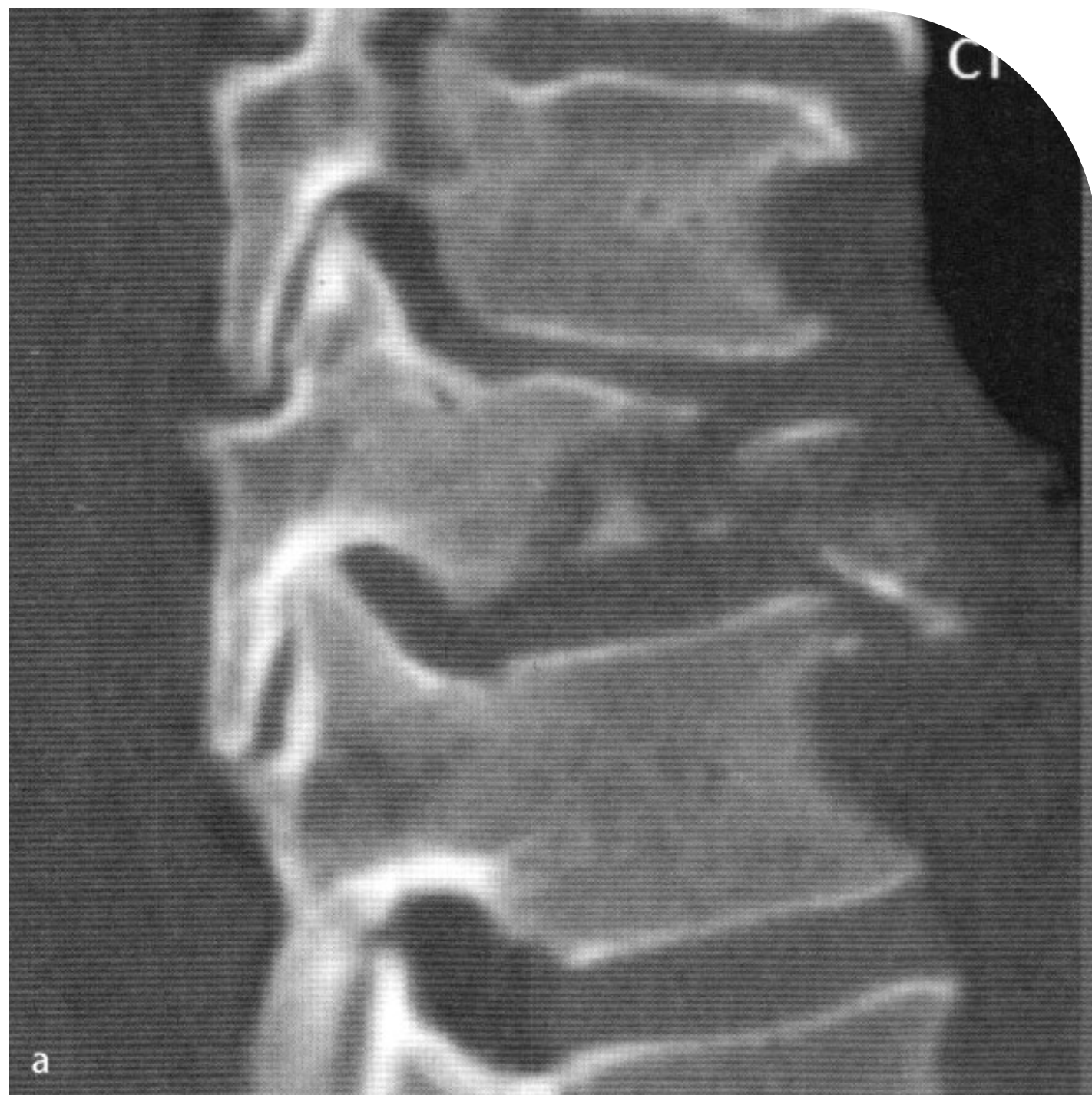
Fraktura lebky



Ibi- 3DCT



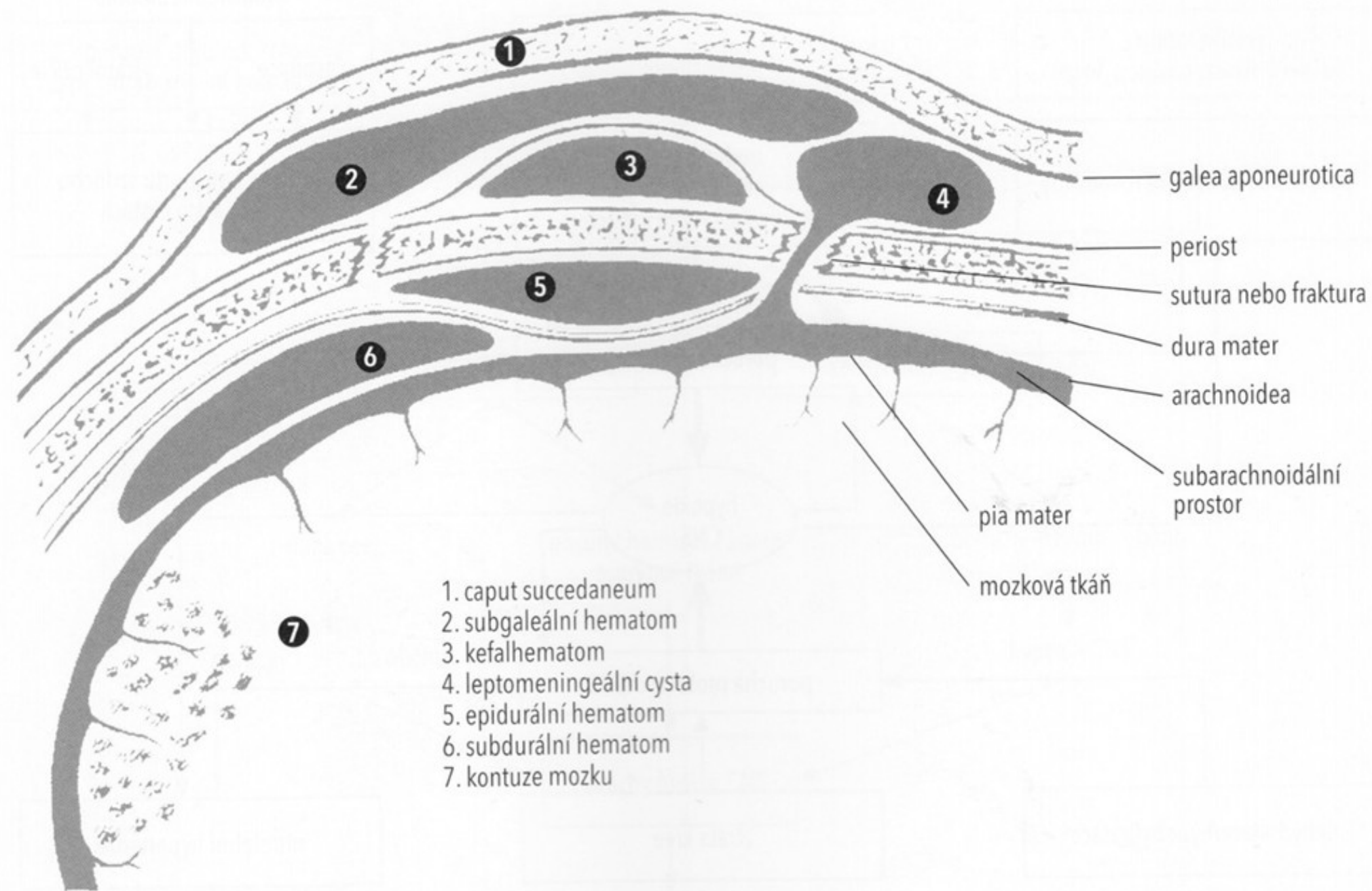
třířtivá





hematoma





1. caput succedaneum
2. subgaleální hematom
3. kefalhematom
4. leptomeningeální cysta
5. epidurální hematom
6. subdurální hematom
7. kontuze mozku

galea aponeurotica

periost

sutura nebo fraktura

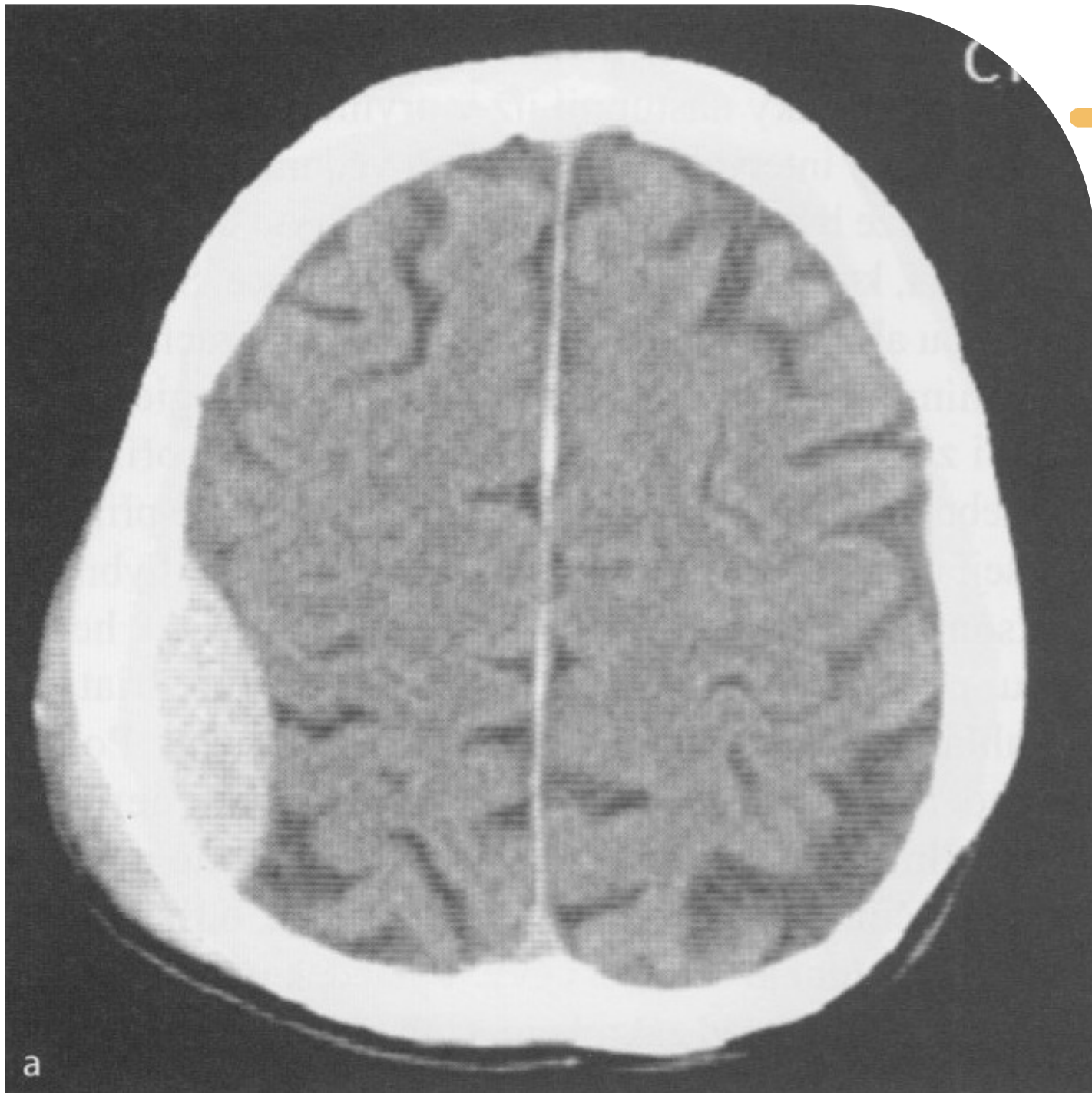
dura mater

arachnoidea


subarachnoidální prostor

pia mater

mozková tkáň



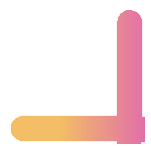hematom

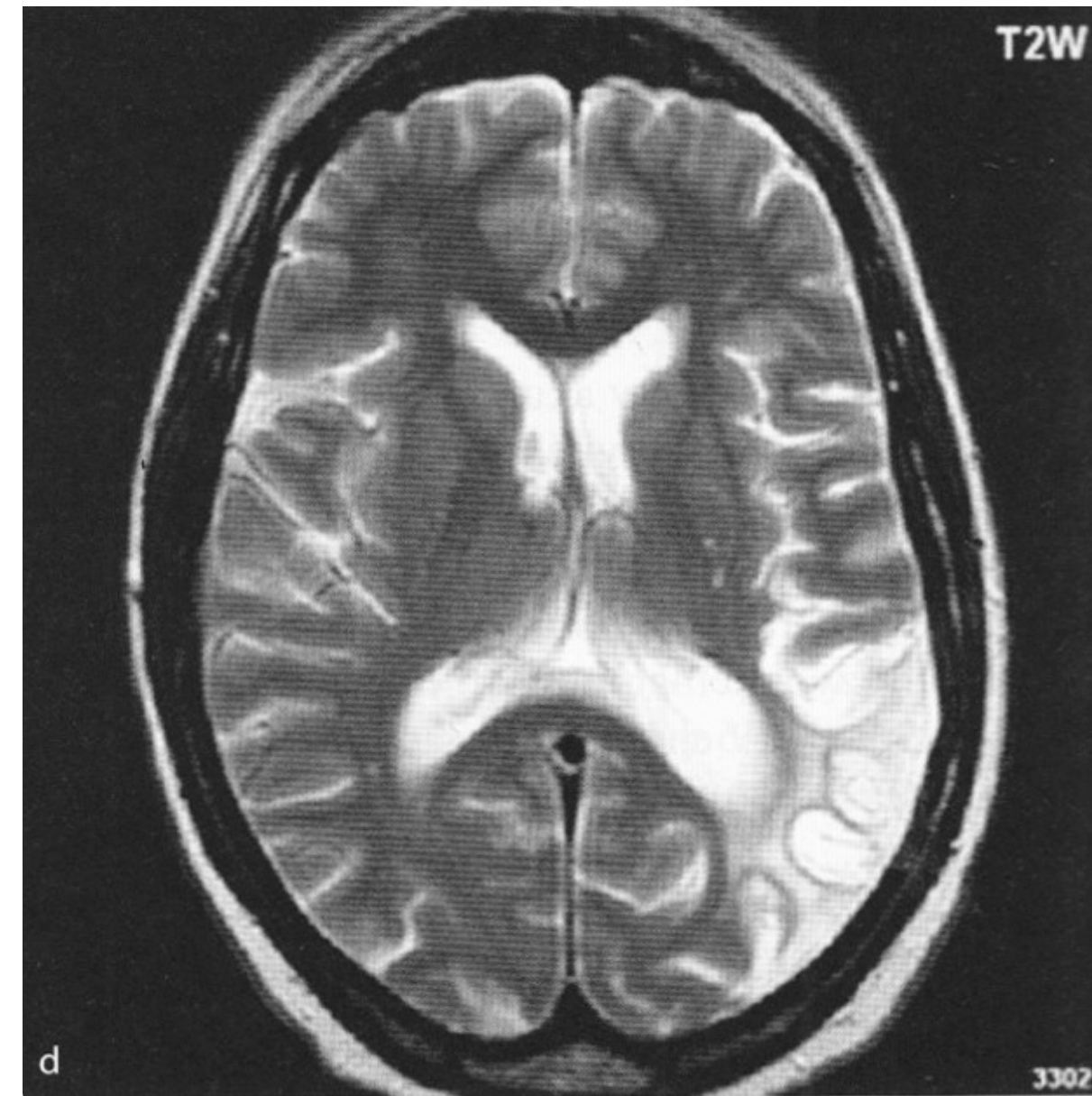
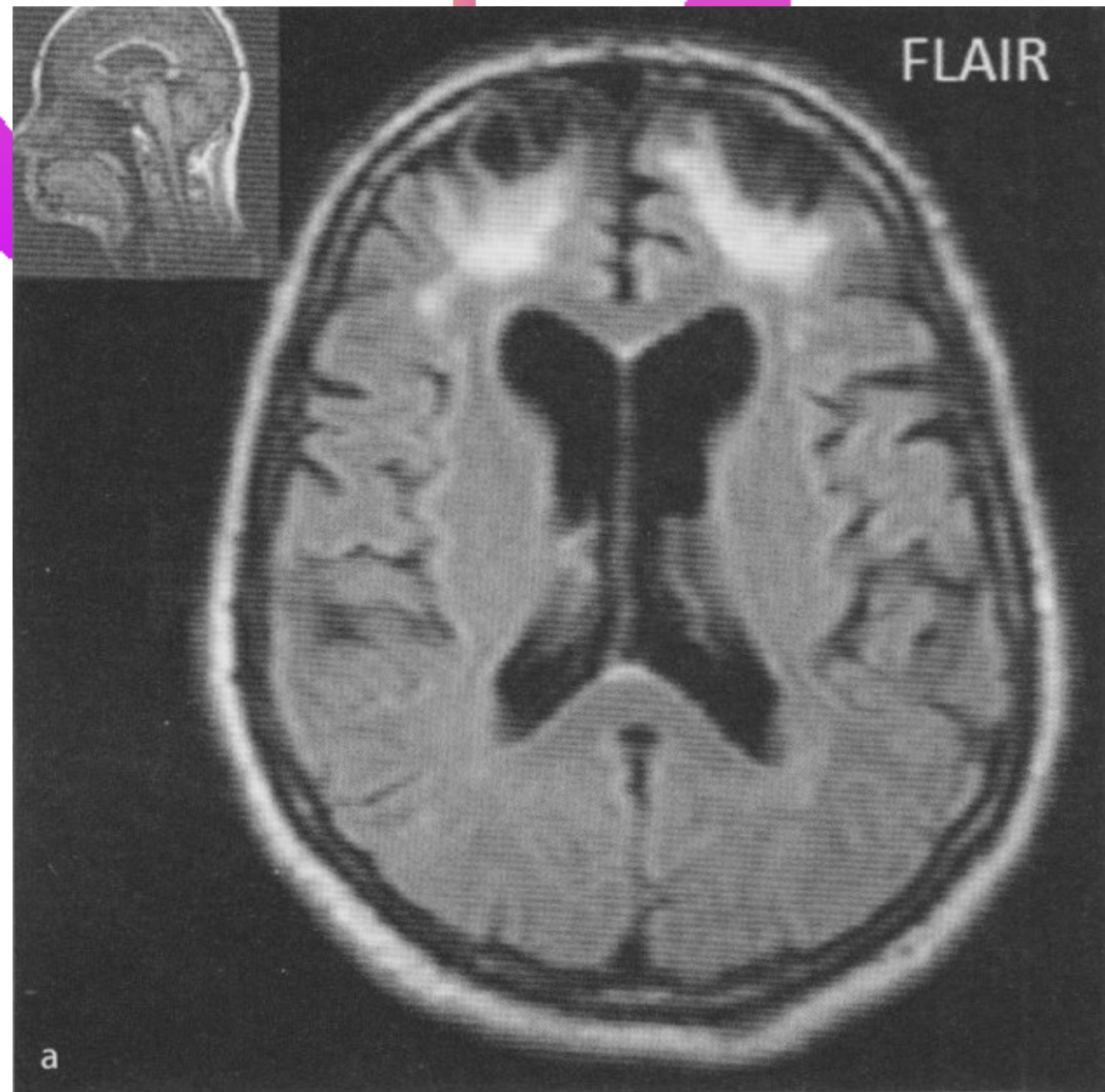
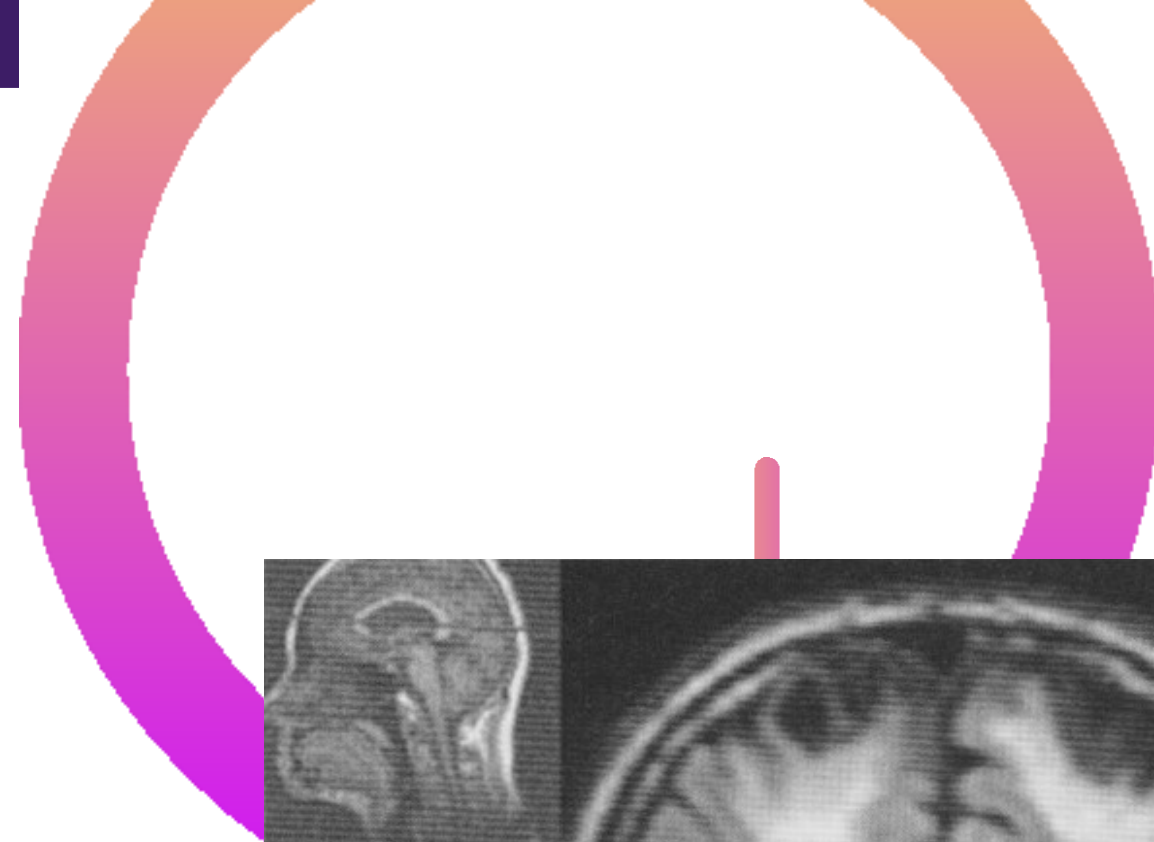


mozková



mozku

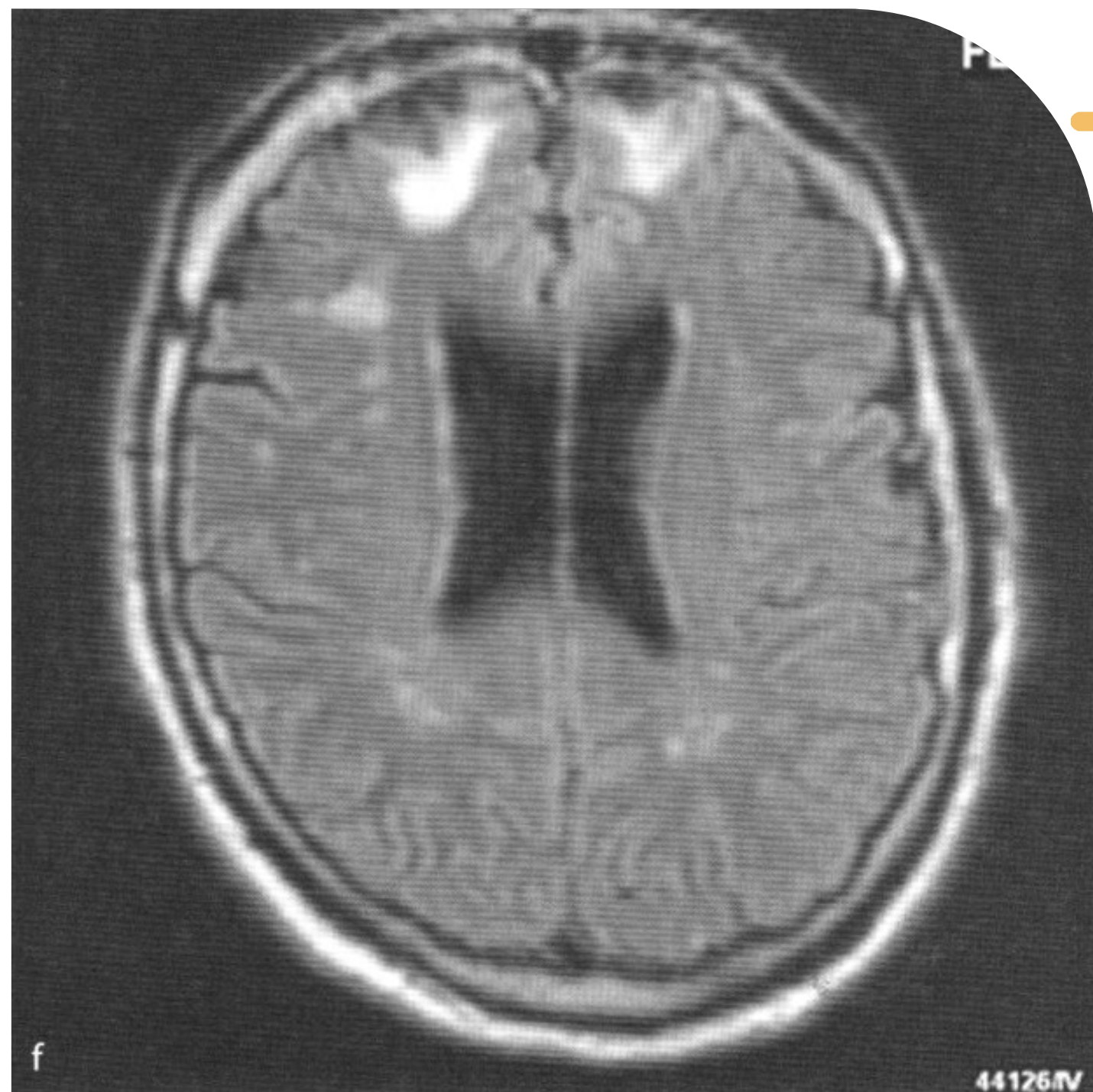





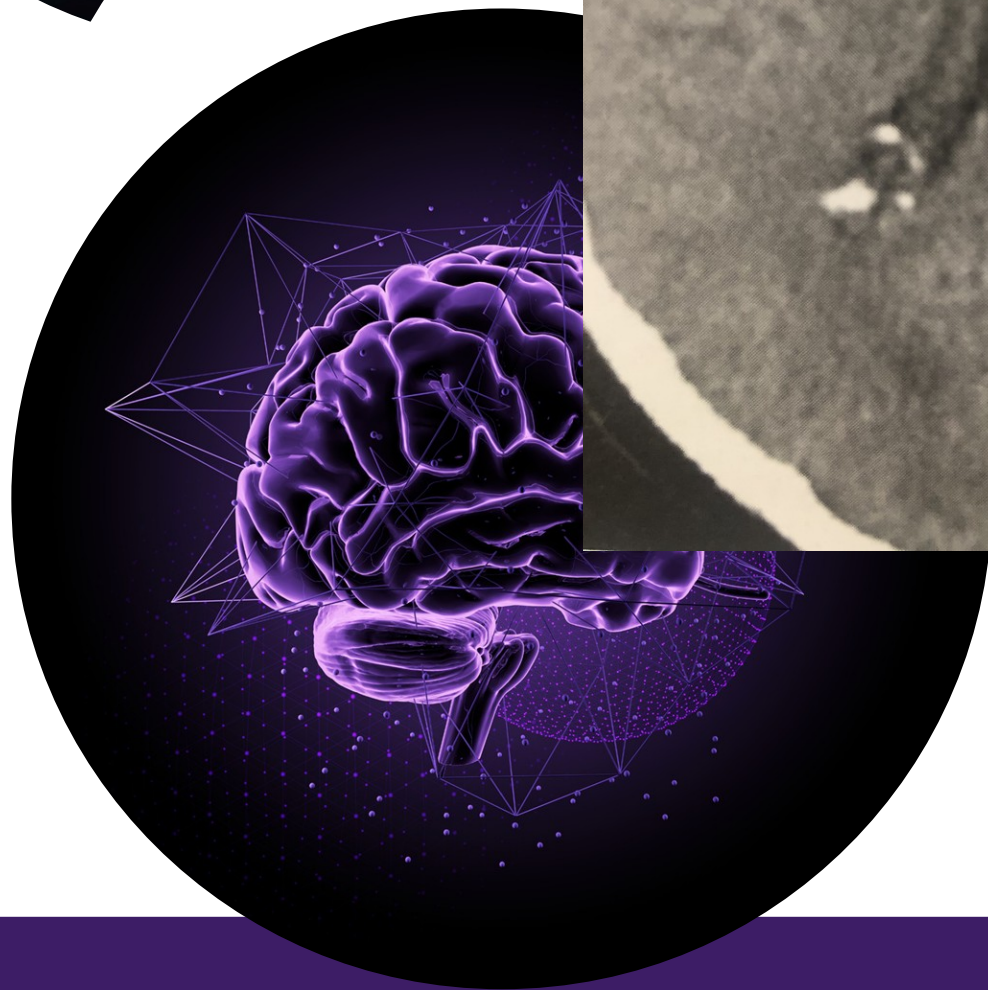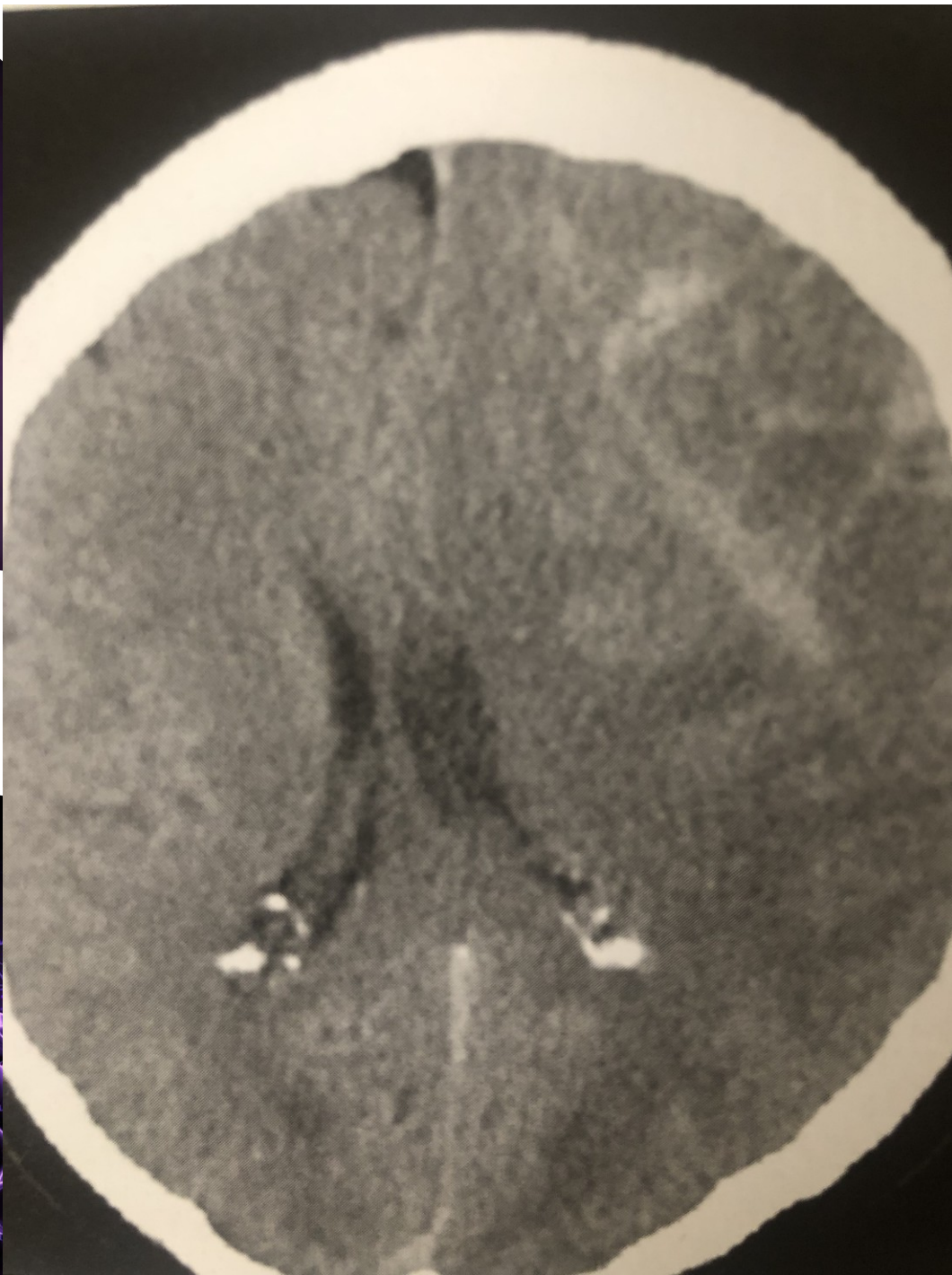


axonální poranění



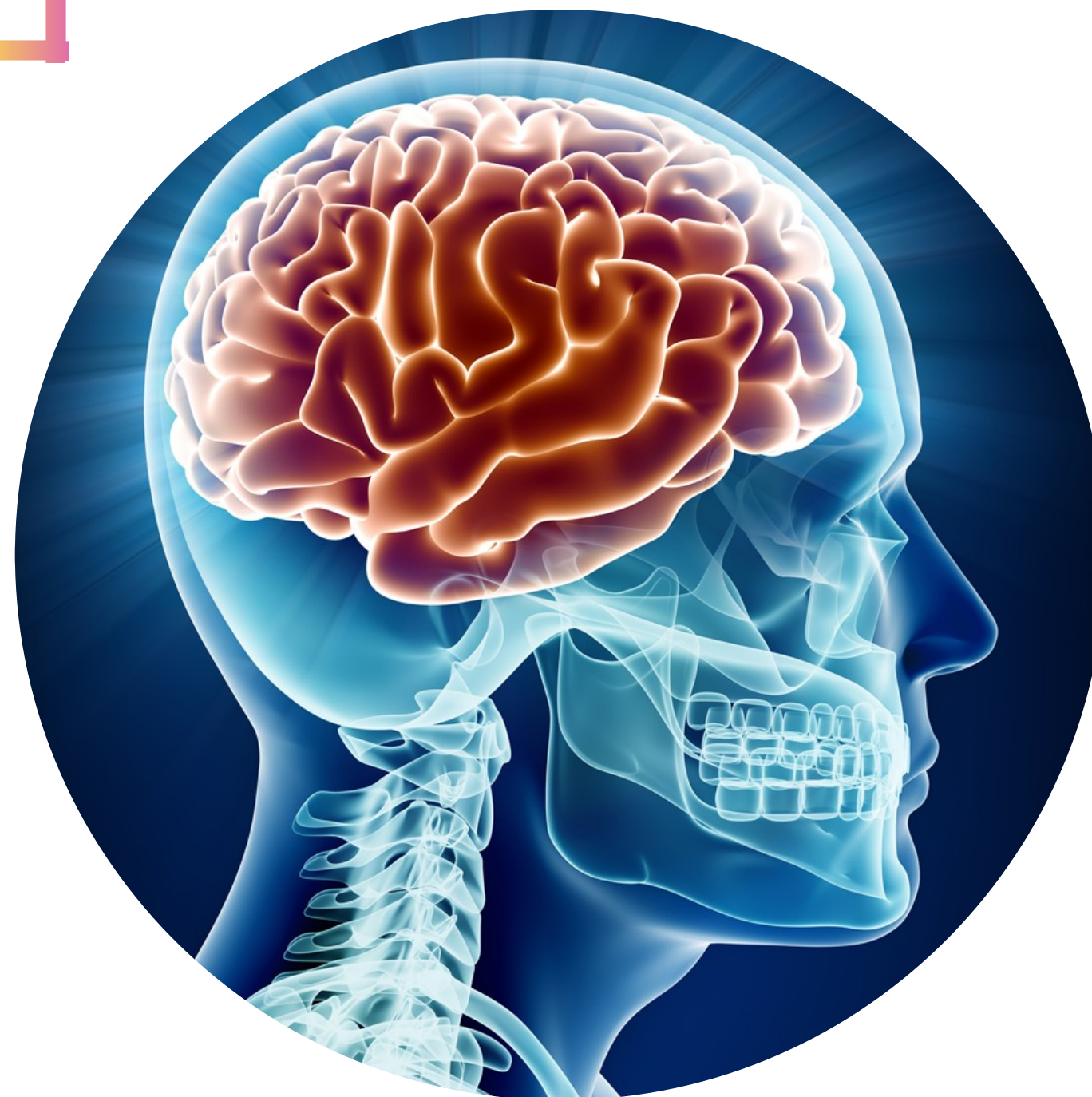

axonální poranění






poranění





týraného dítěte

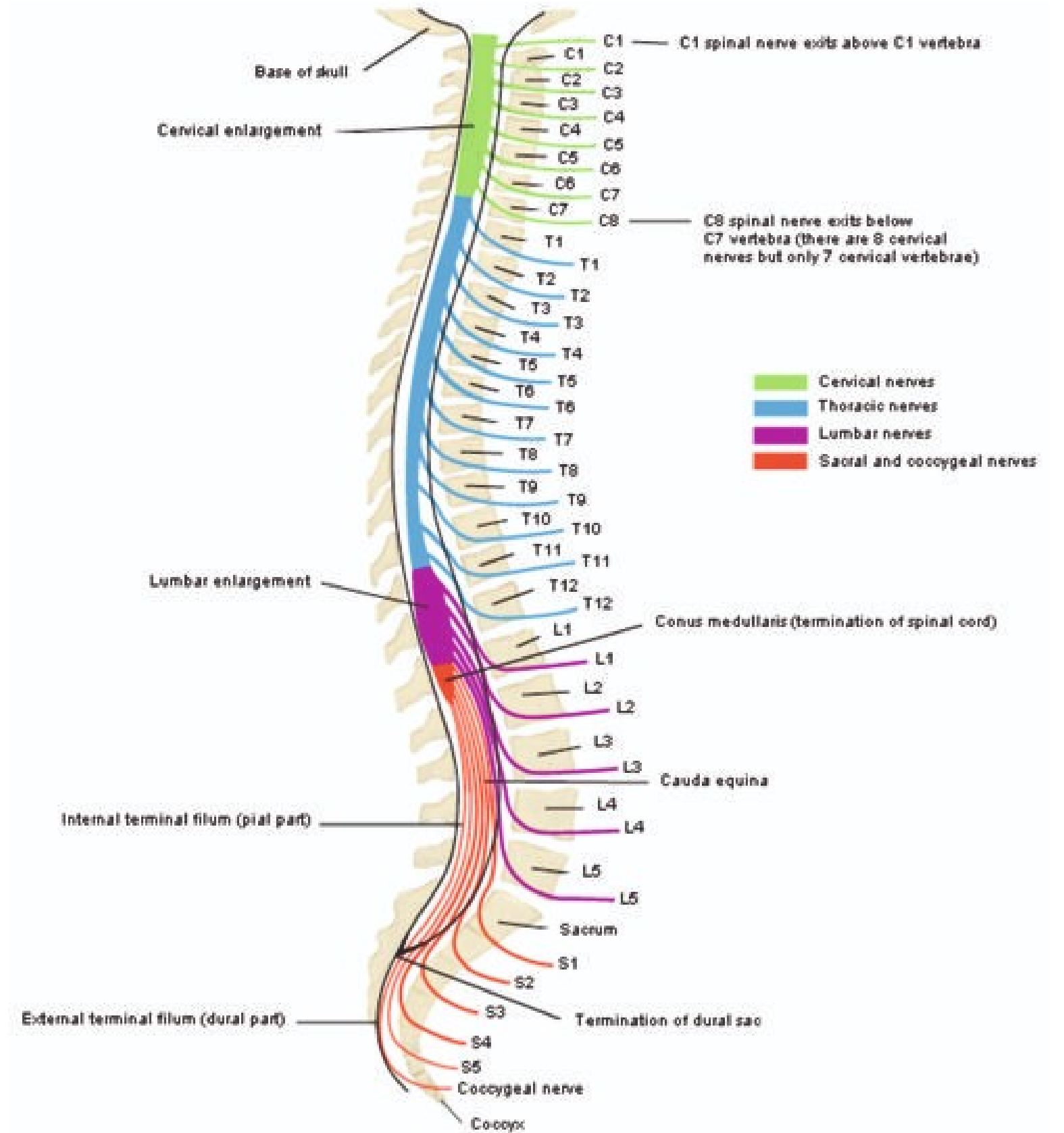


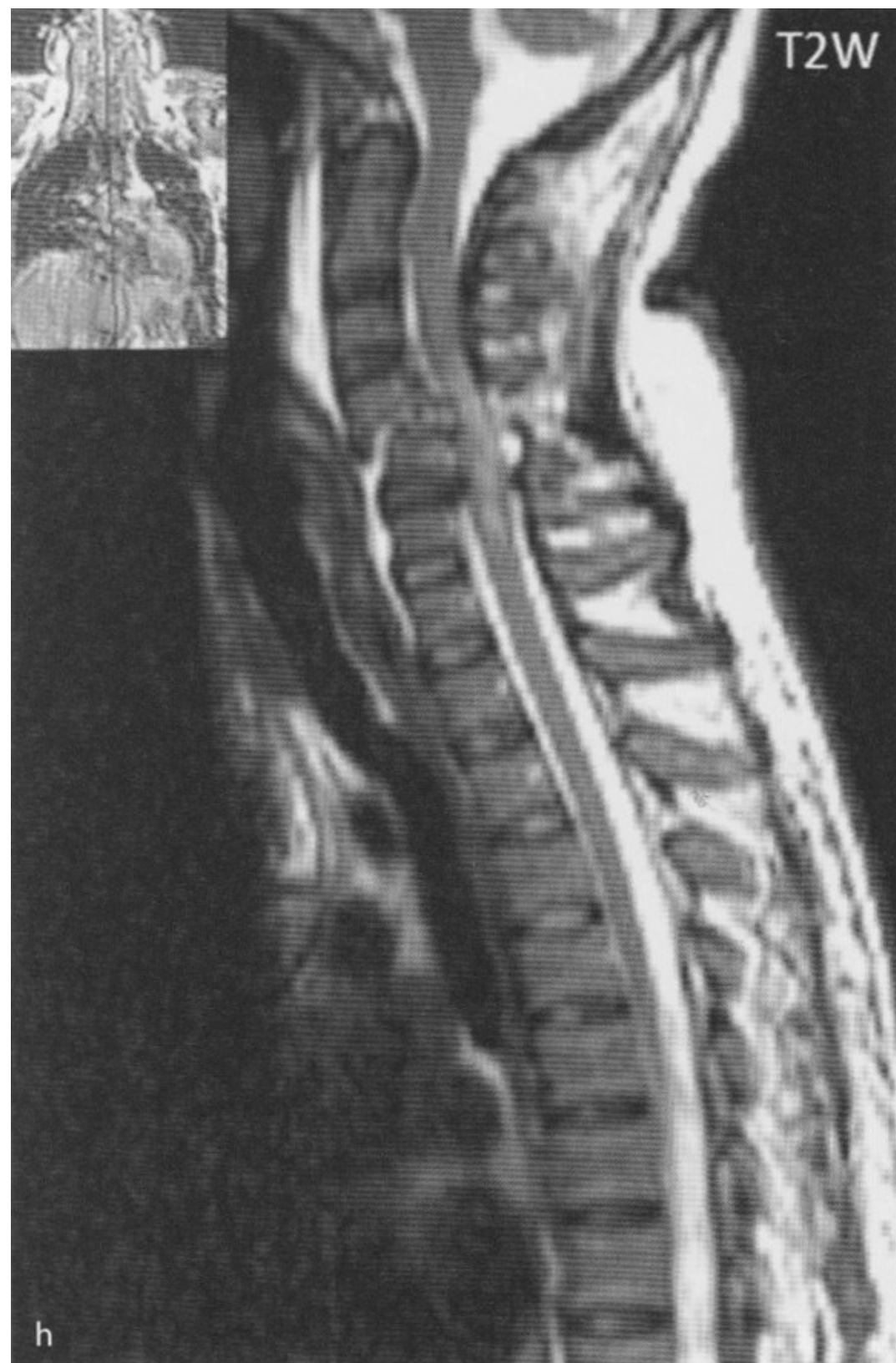


míchy



[Seidl Z., Diagnostická radiologie, Grada Publishing, 2014, ISBN 978-80-247-4546-6, str408, obr, II.4.2a](#)

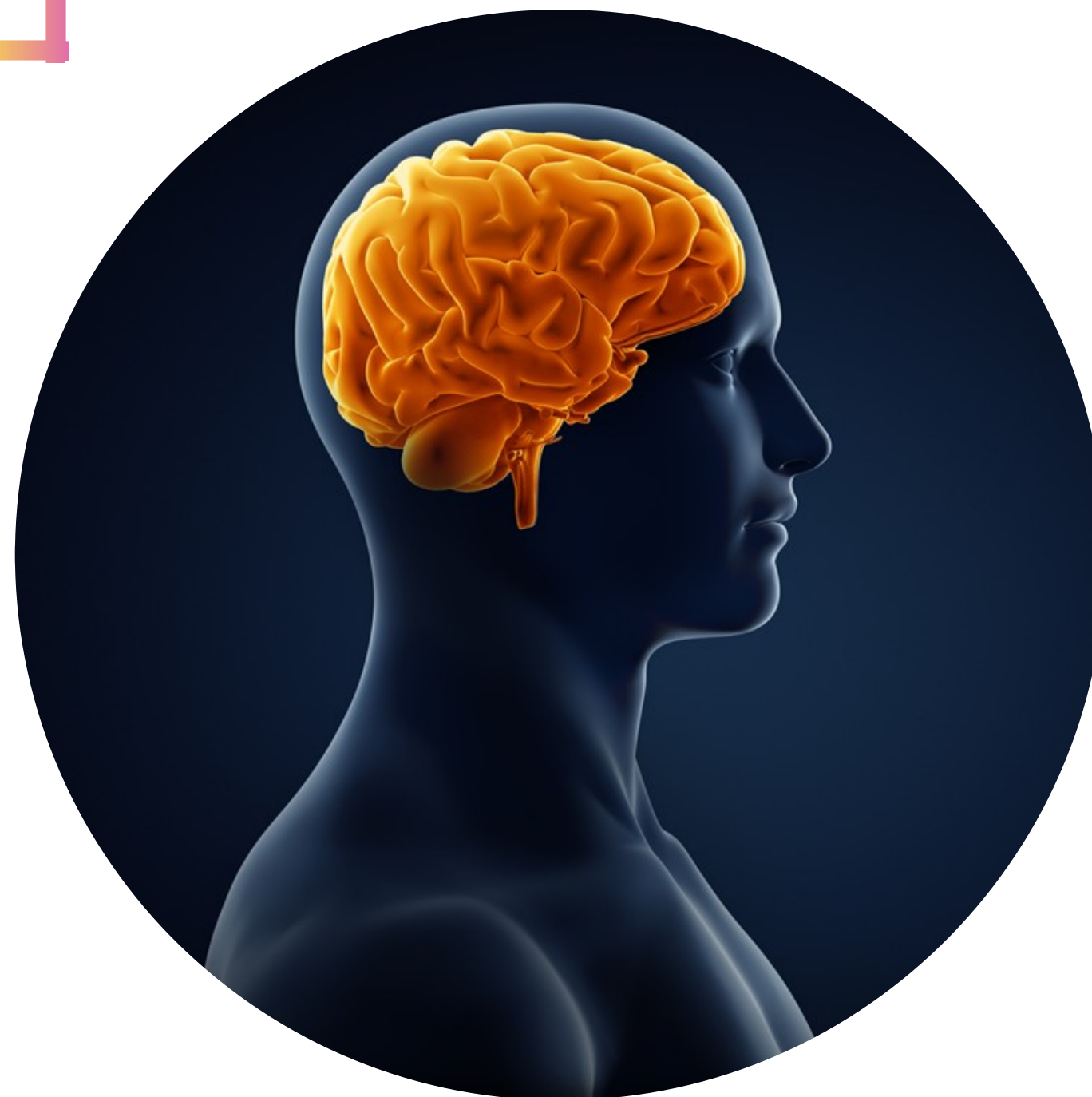





[Seidl Z., Diagnostická radiologie, Grada Publishing, 2014, ISBN 978-80-247-4546-6, str410, obr, II.4.2h](#)



míšní léze



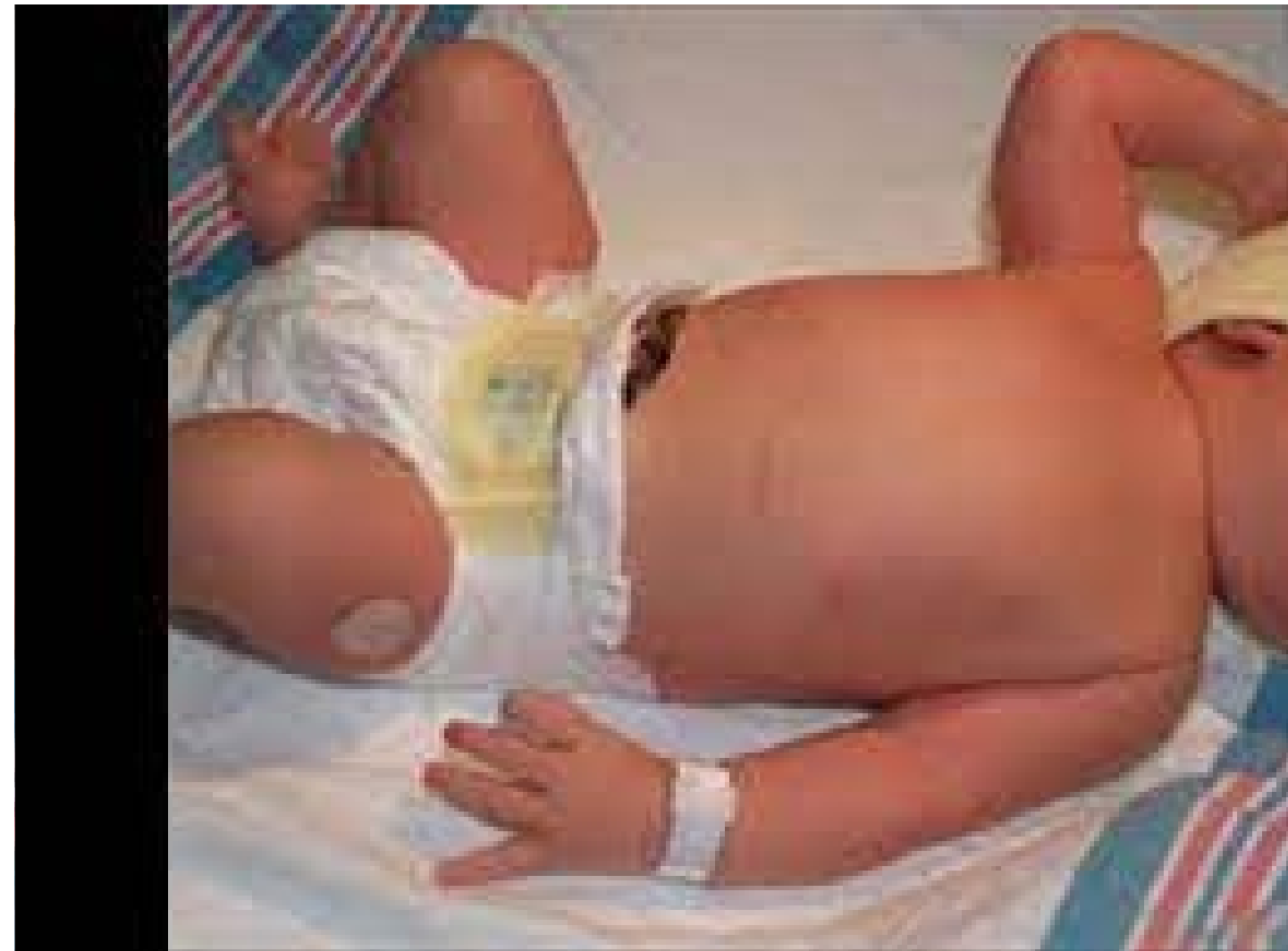
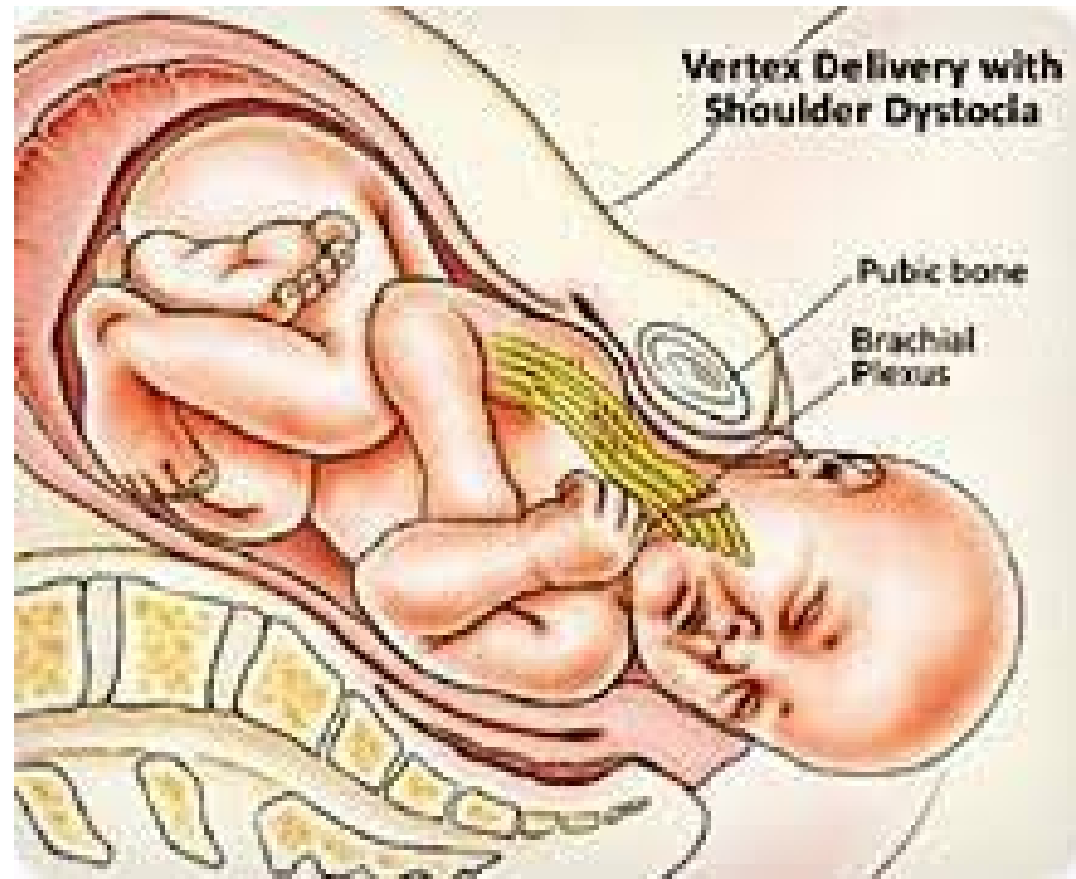





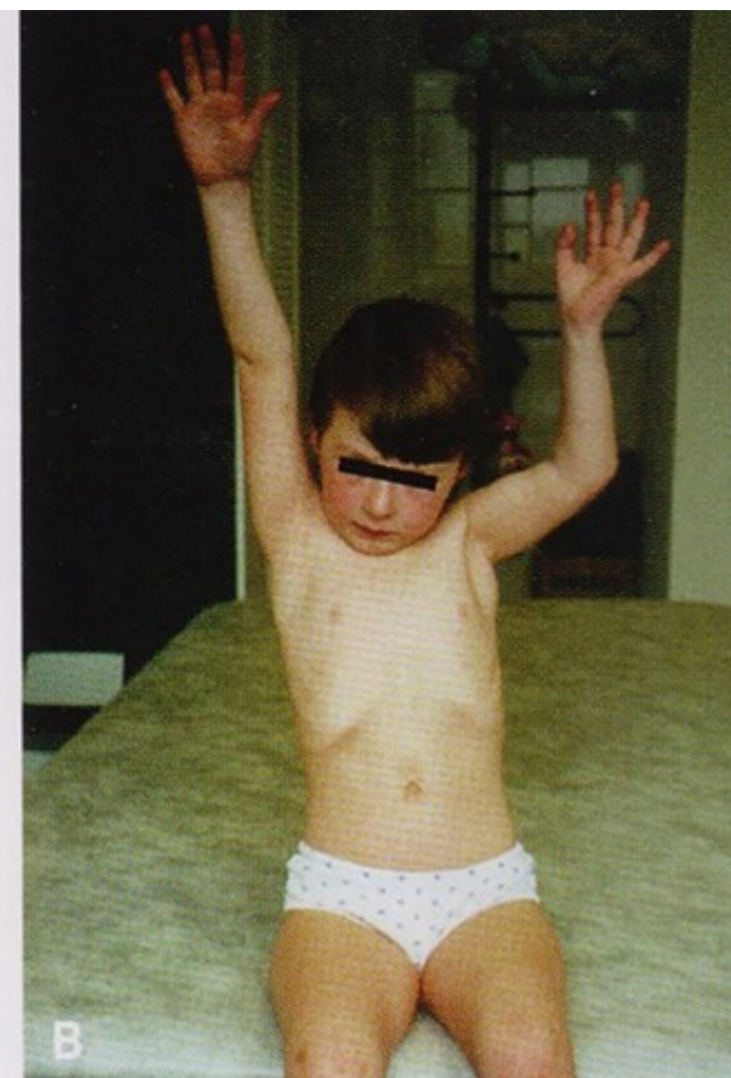
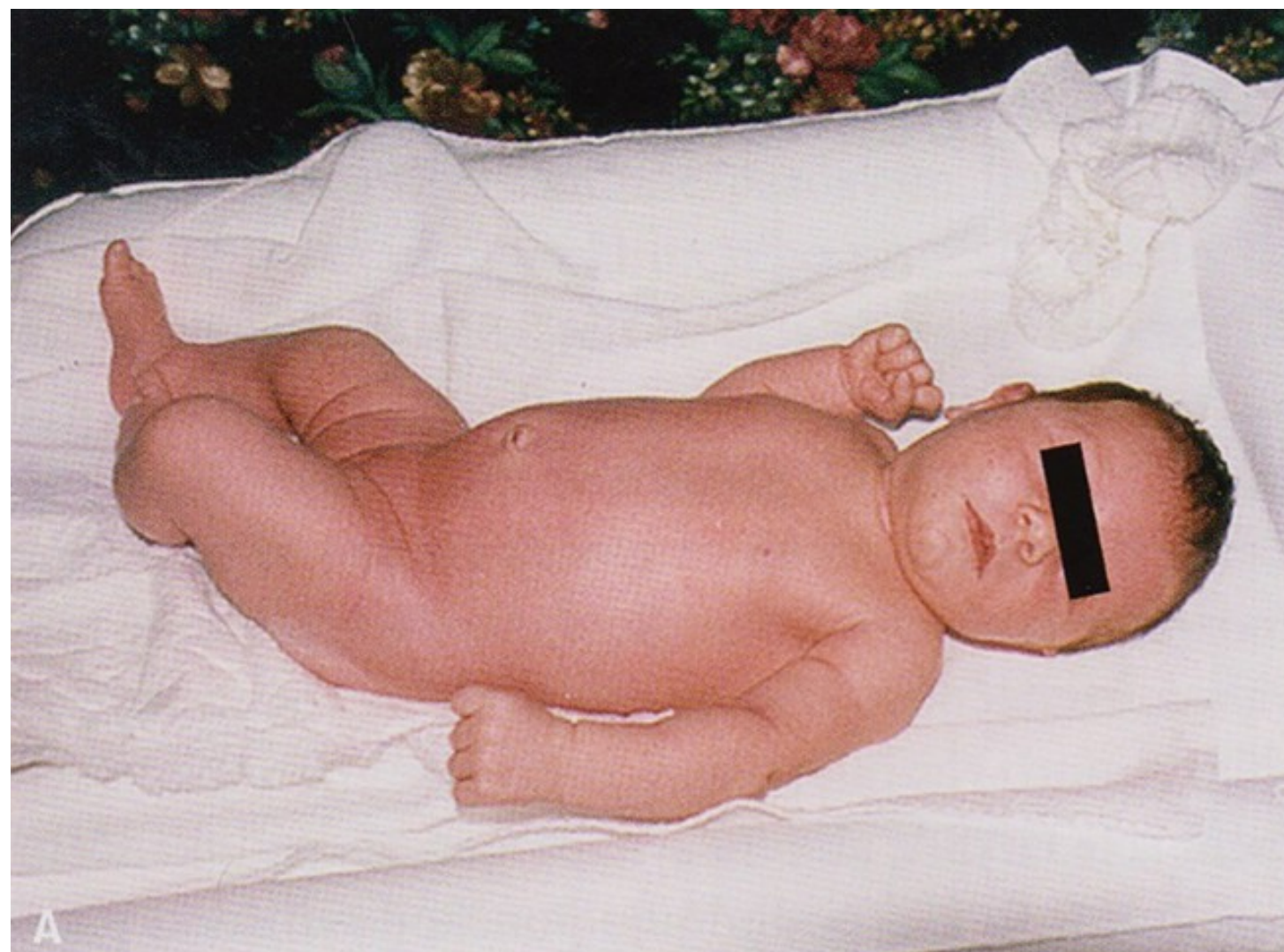
brachiálního plexu







[Nevšimalová S., Dětská neurologie, Galén 2021, ISBN 978-80-7492-557-3, str 111, obr.3-16](#)



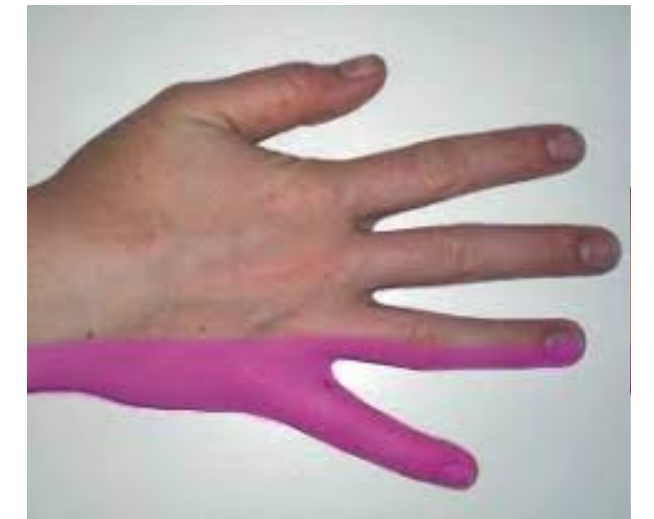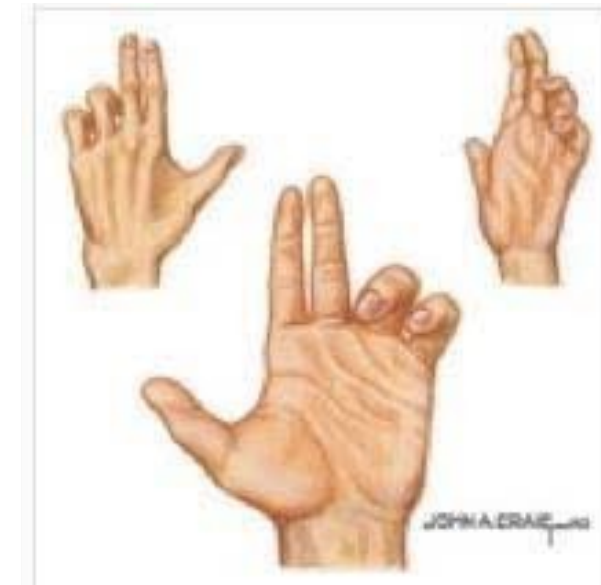


brachiálního plexu



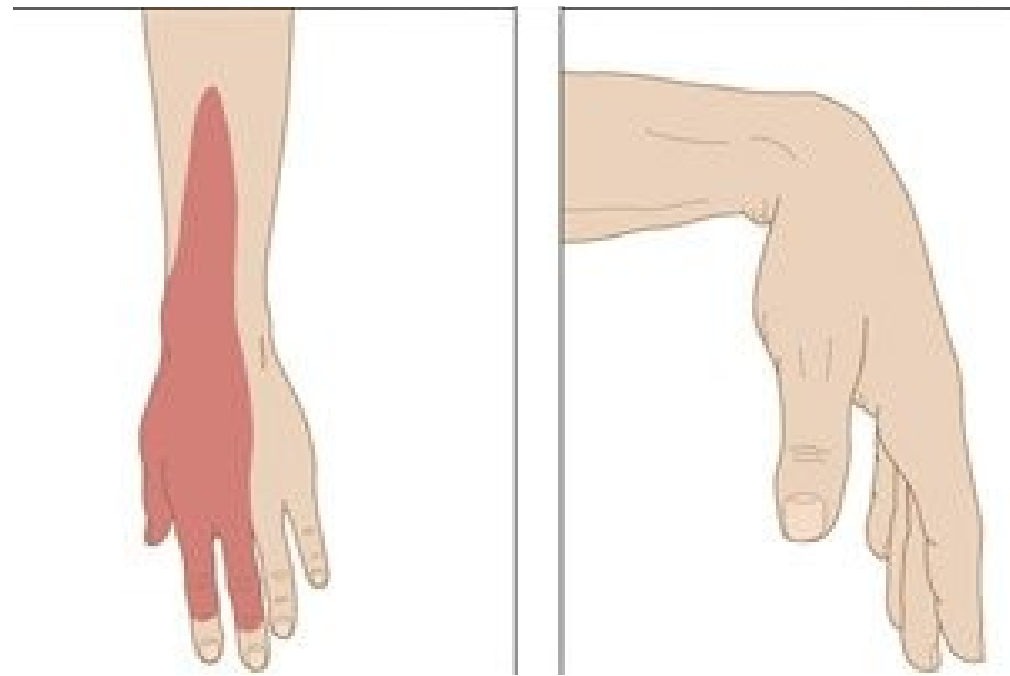


n. ulnaris

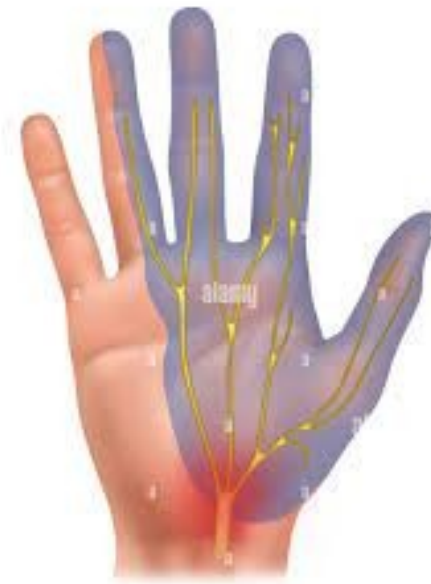



n. radialis



n. medianus C5-8, Th1



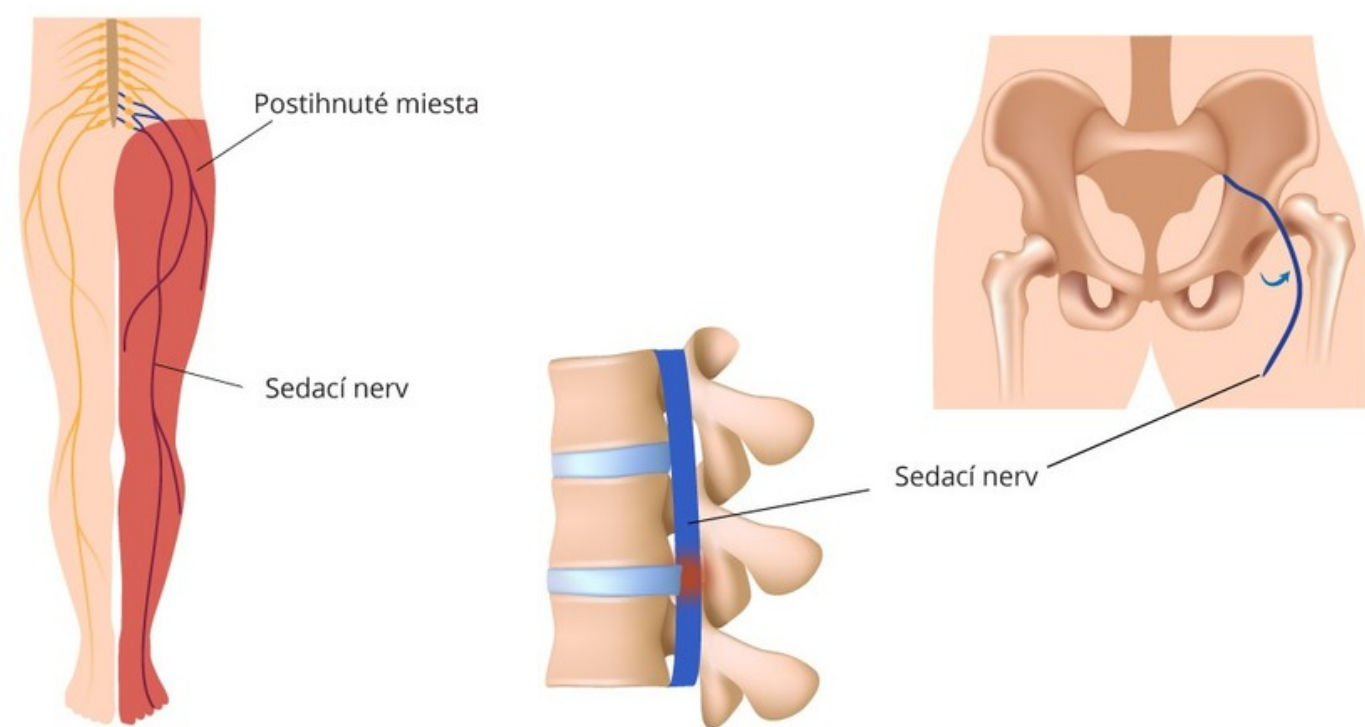
alamy



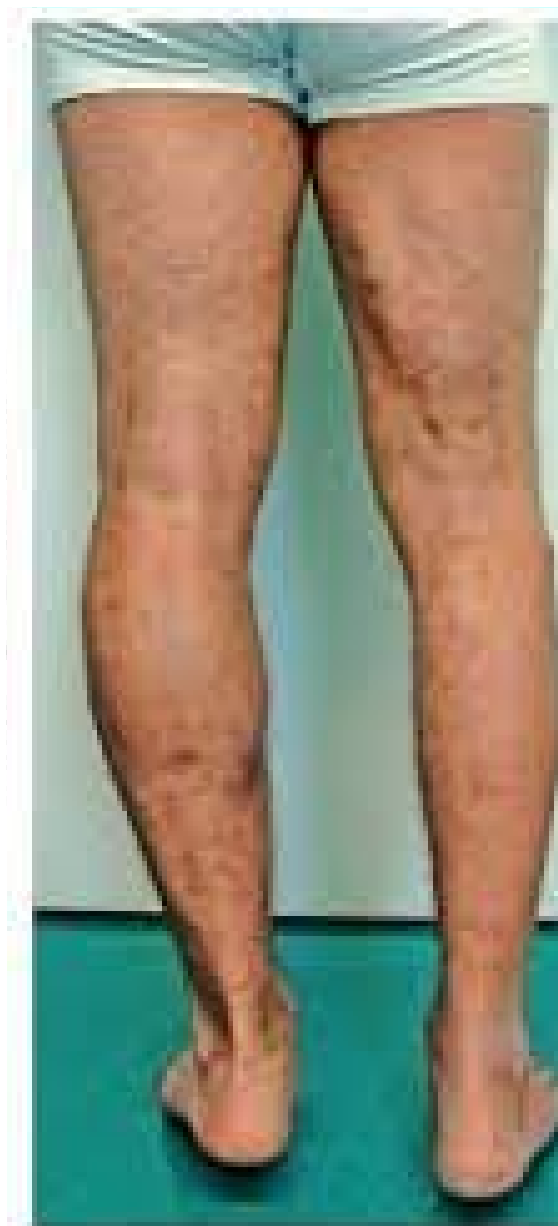

Špatná volba místa pro injekci do hýždě, porod KP, nehody

Zápal sedacieho nervu - ischias



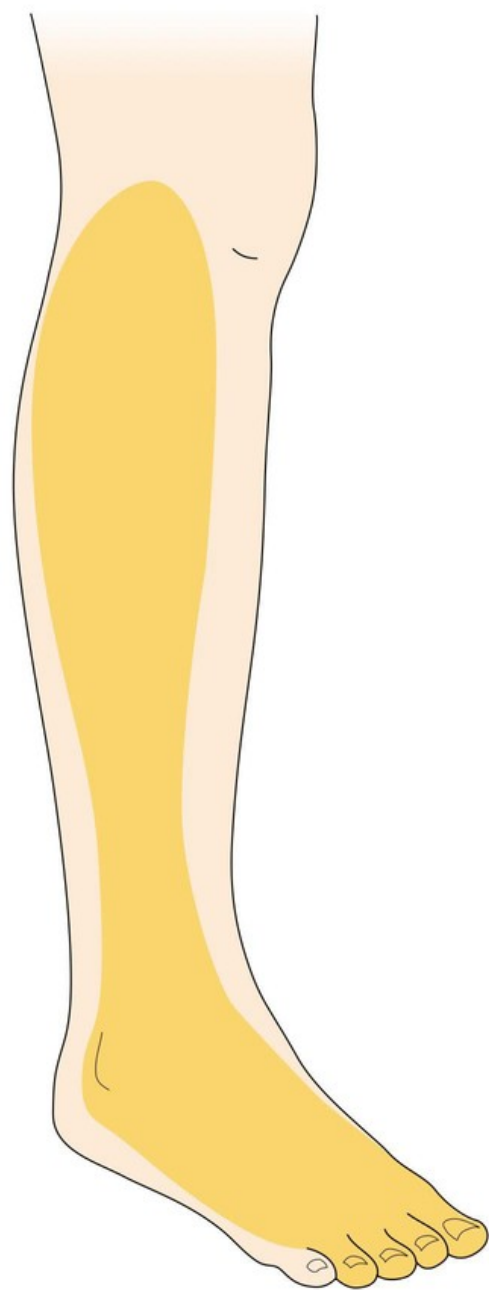
symptomy.sk



Obra 1. Pacient z kazuistiky 33 mesiaci po rekonstrukcii NI sprava v úrovni stehna. Pravy bicep hypotroficky, tonus svalstva zachovaný, postaví sa na špičku. Jazyk po revízií patrná na stehne, na oboch lýtkách drobné jazyky po odberoch na nervoch.



Trauma nervu u hlavičky fibuly , ortopedické výkony v oblasti kolene, inverze nohy v kotníku



© Birgitte Lerche-Barlach 2012

