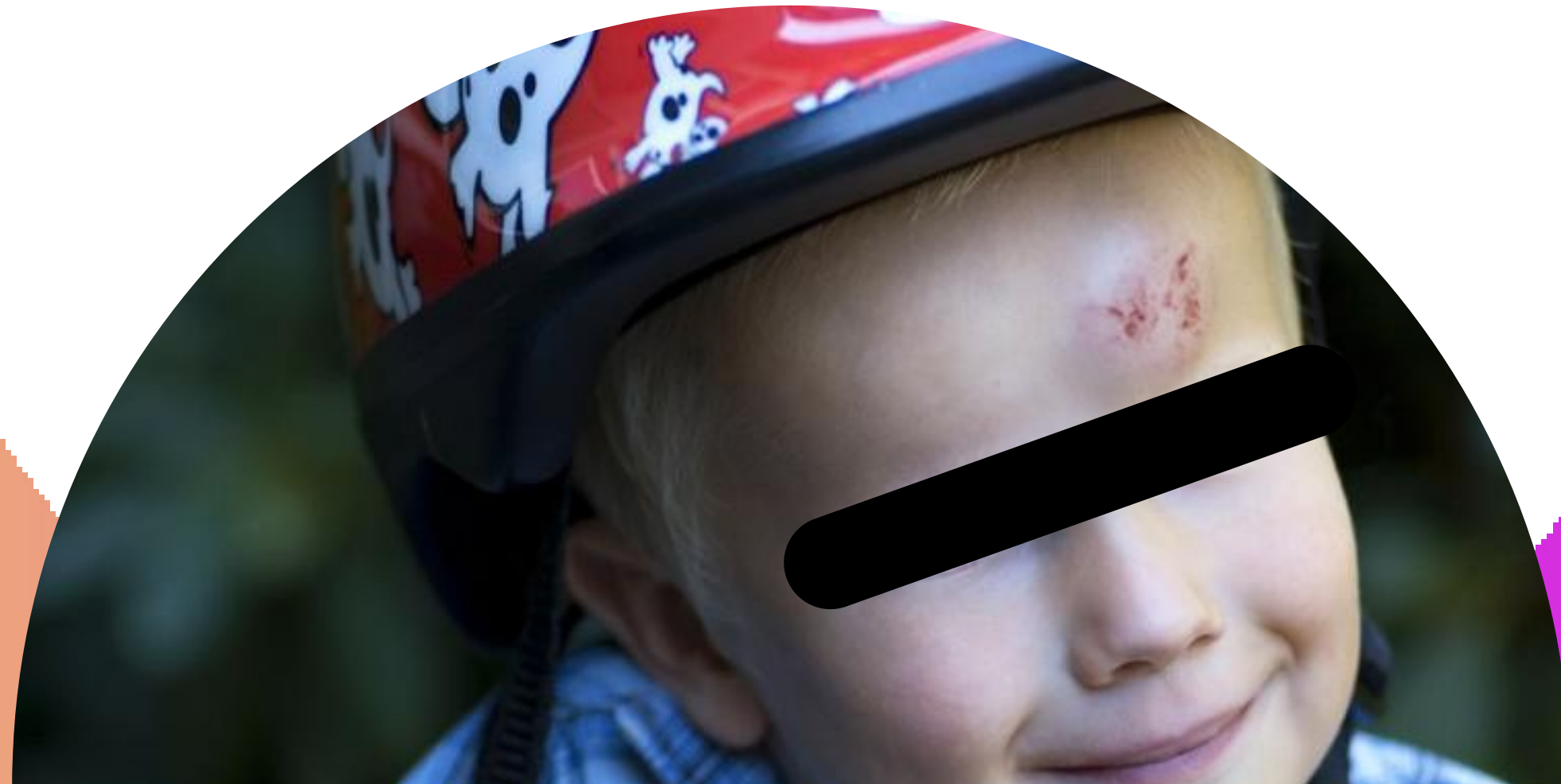



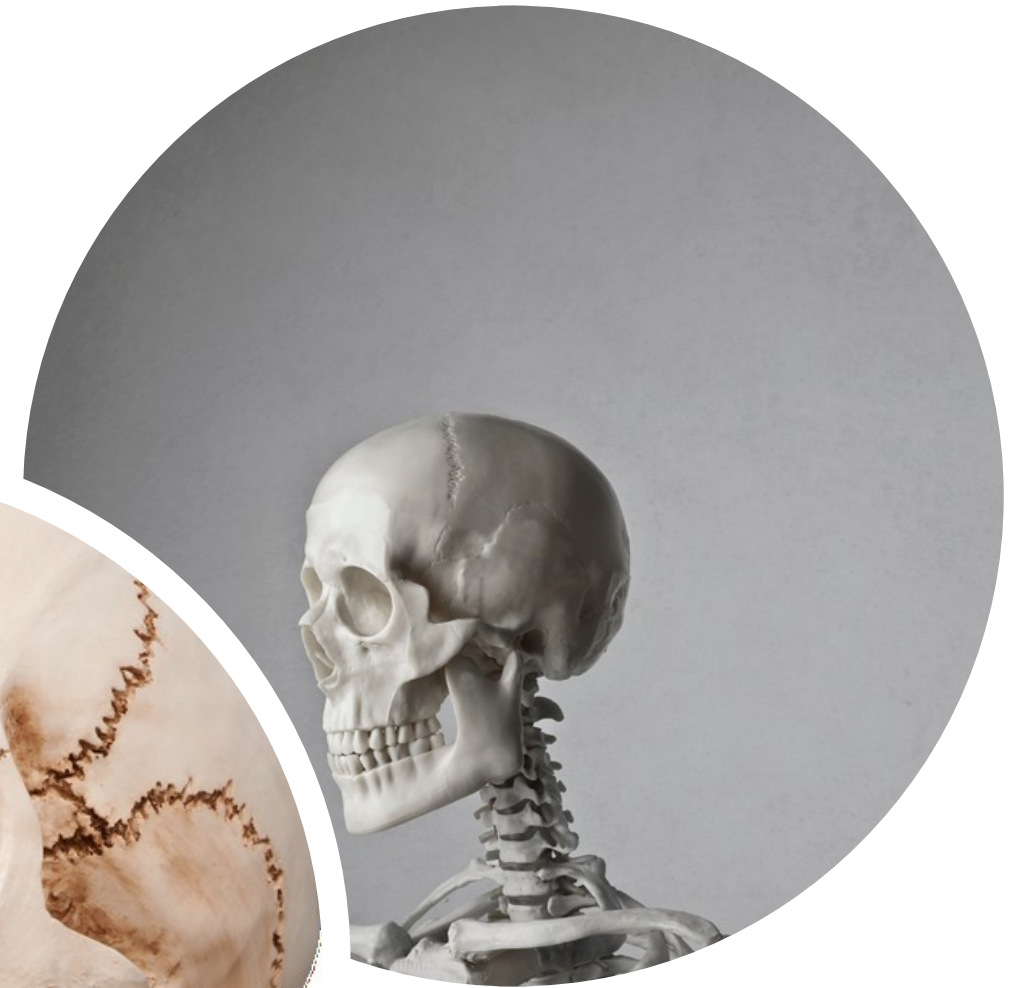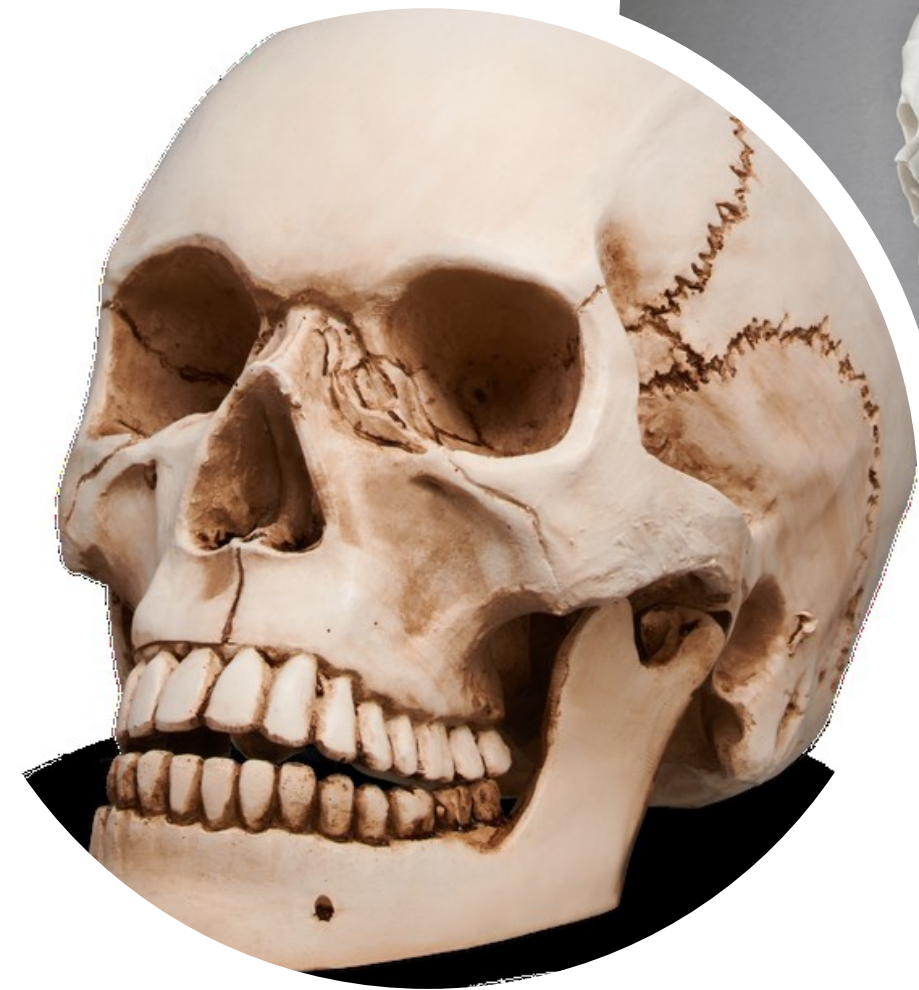KCP

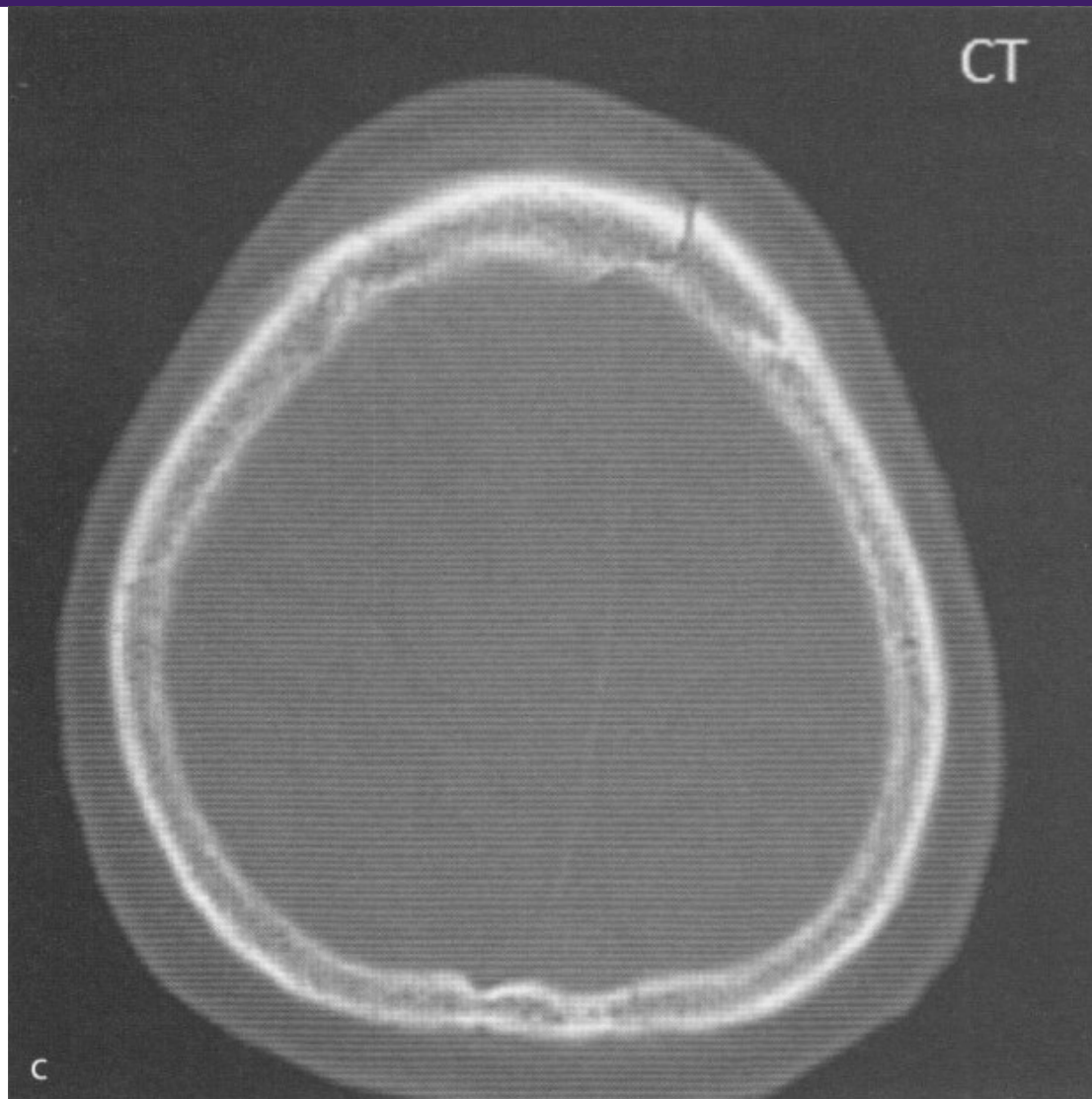




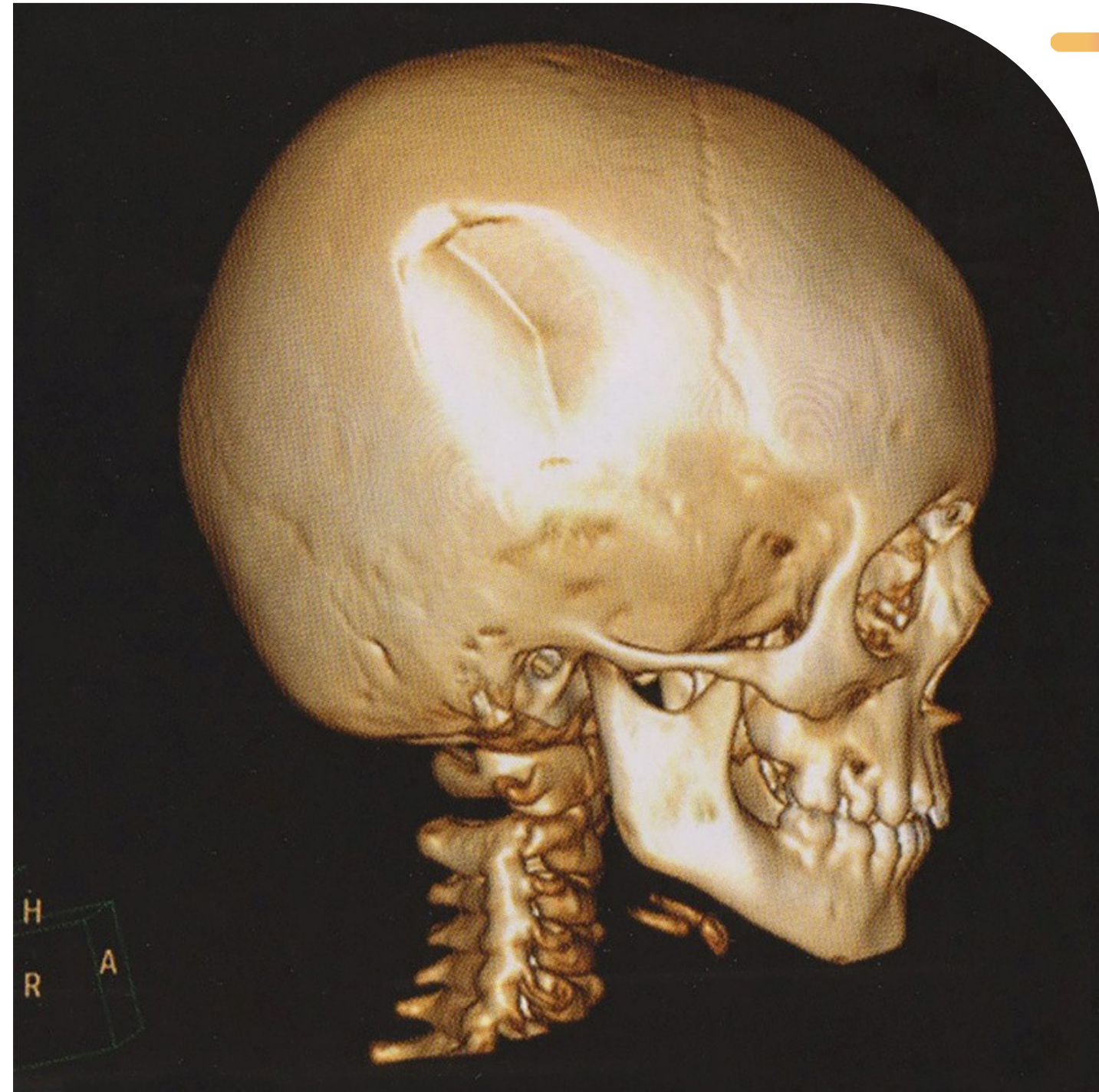
# poranění









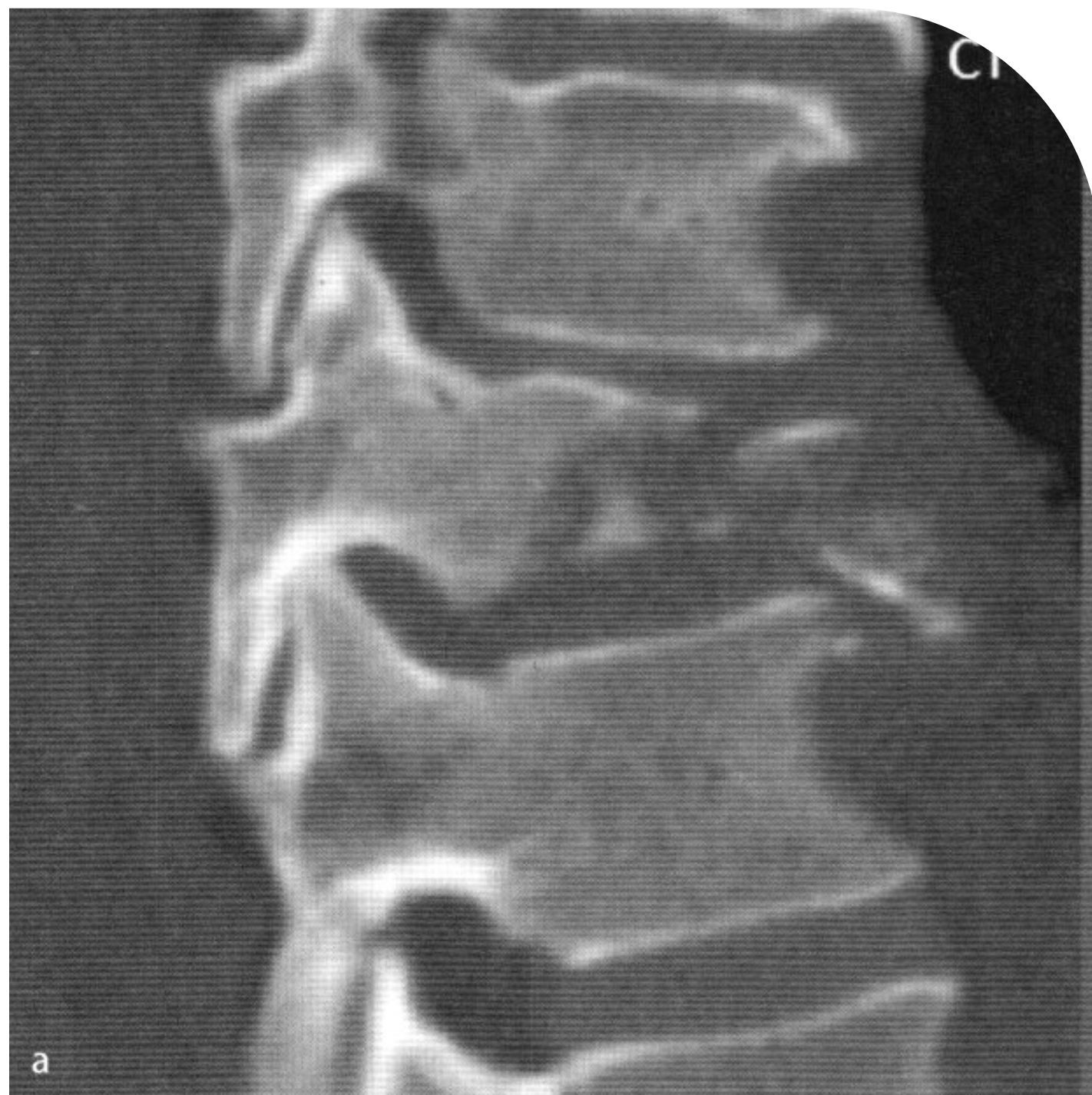
**Fraktura lebky**



Ibi- 3DCT



**tříštivá**

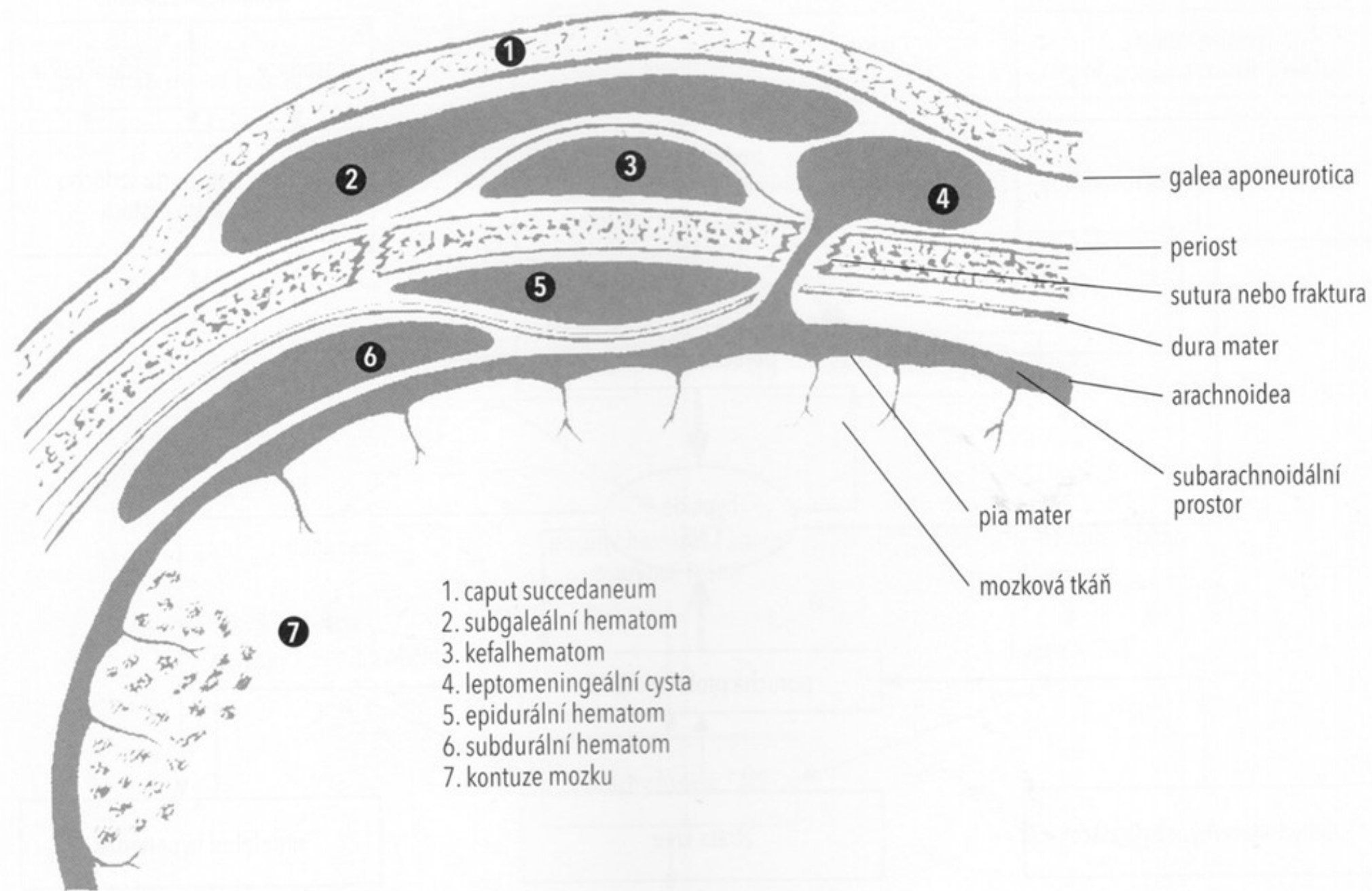




hematoma







1. caput succedaneum
2. subgaleální hematom
3. kefalhematom
4. leptomeningeální cysta
5. epidurální hematom
6. subdurální hematom
7. kontuze mozku

galea aponeurotica

periost

sutura nebo fraktura

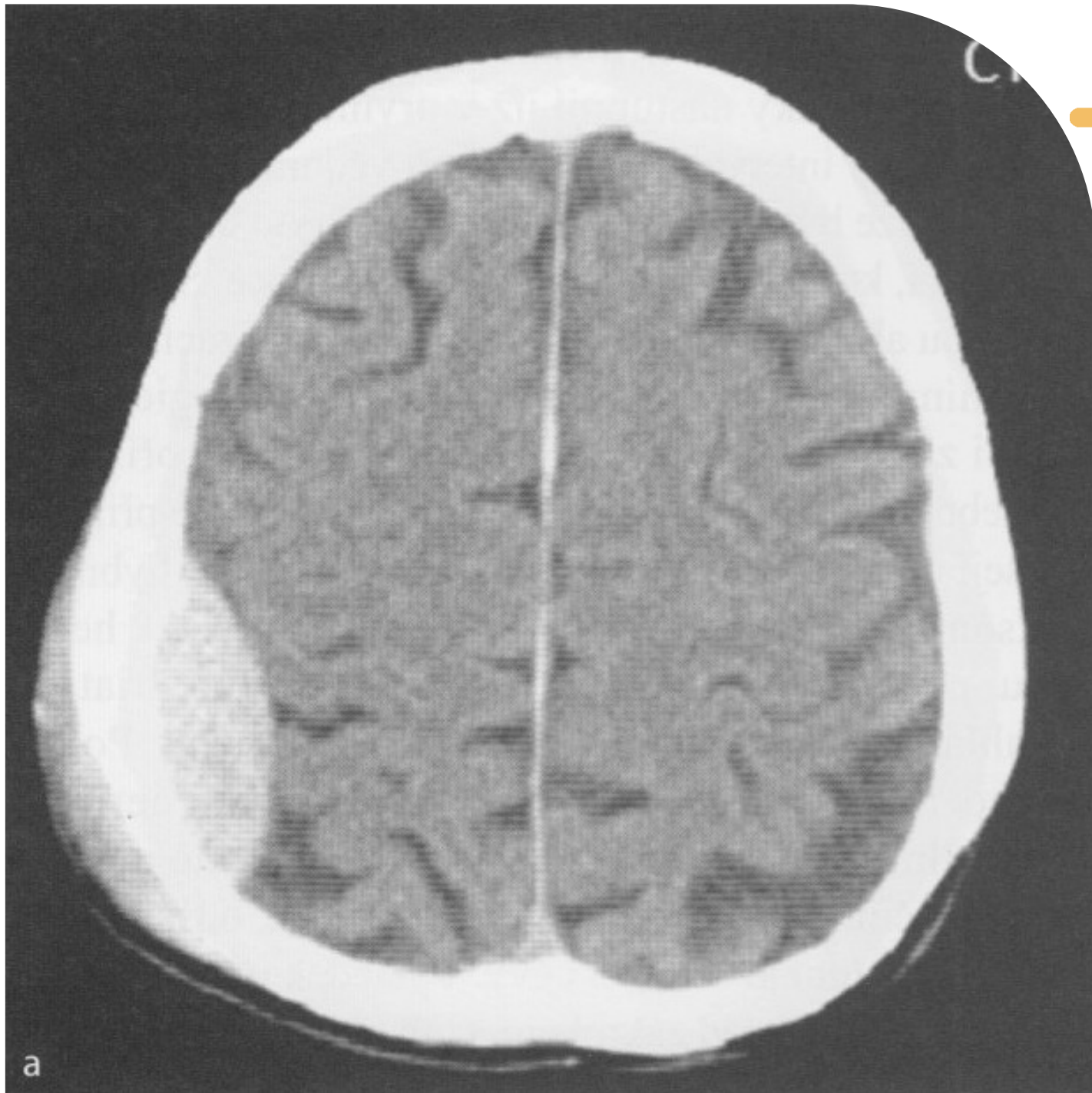dura mater

arachnoidea


subarachnoidální prostor

pia mater

mozková tkáň



hematom

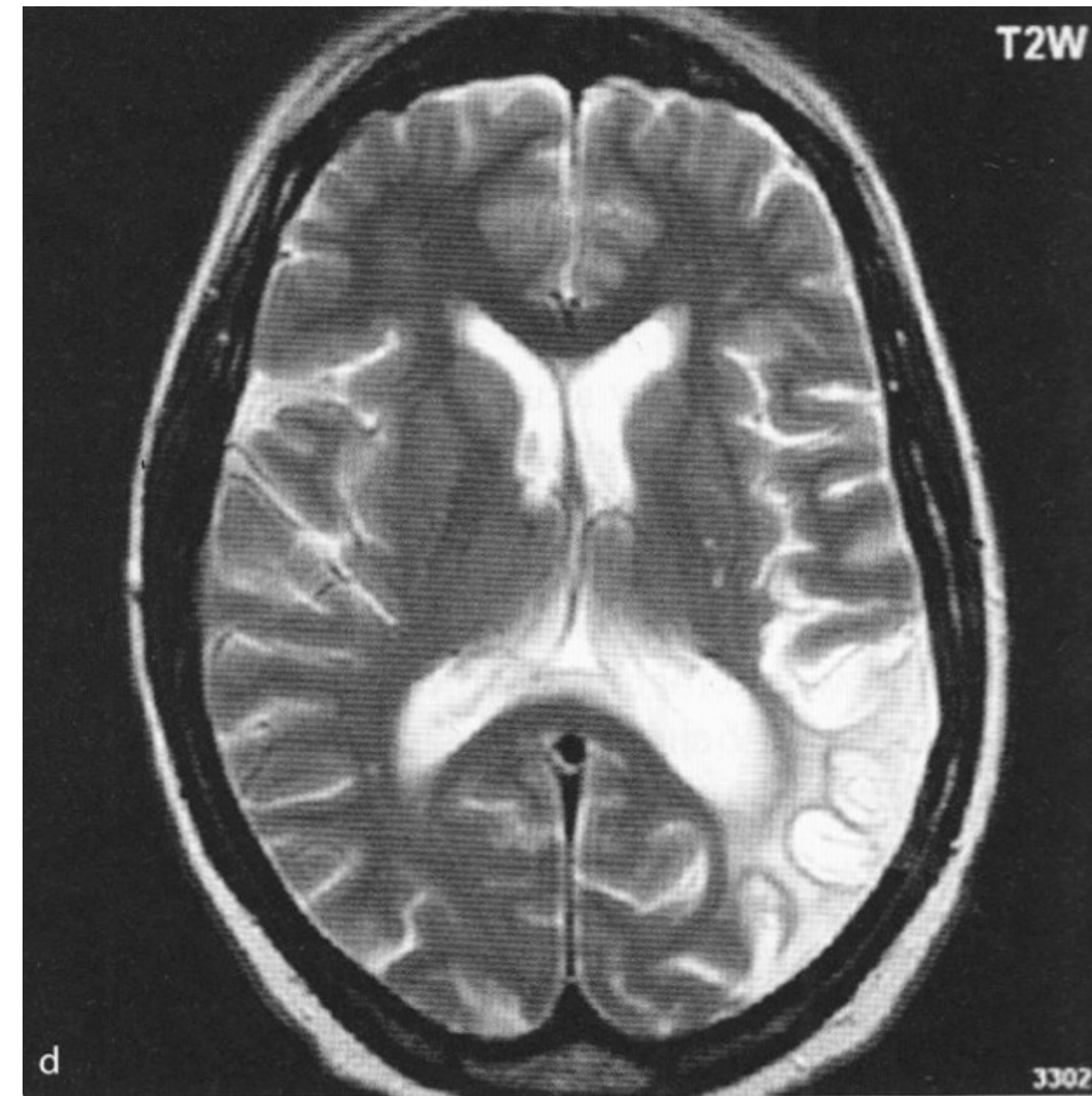
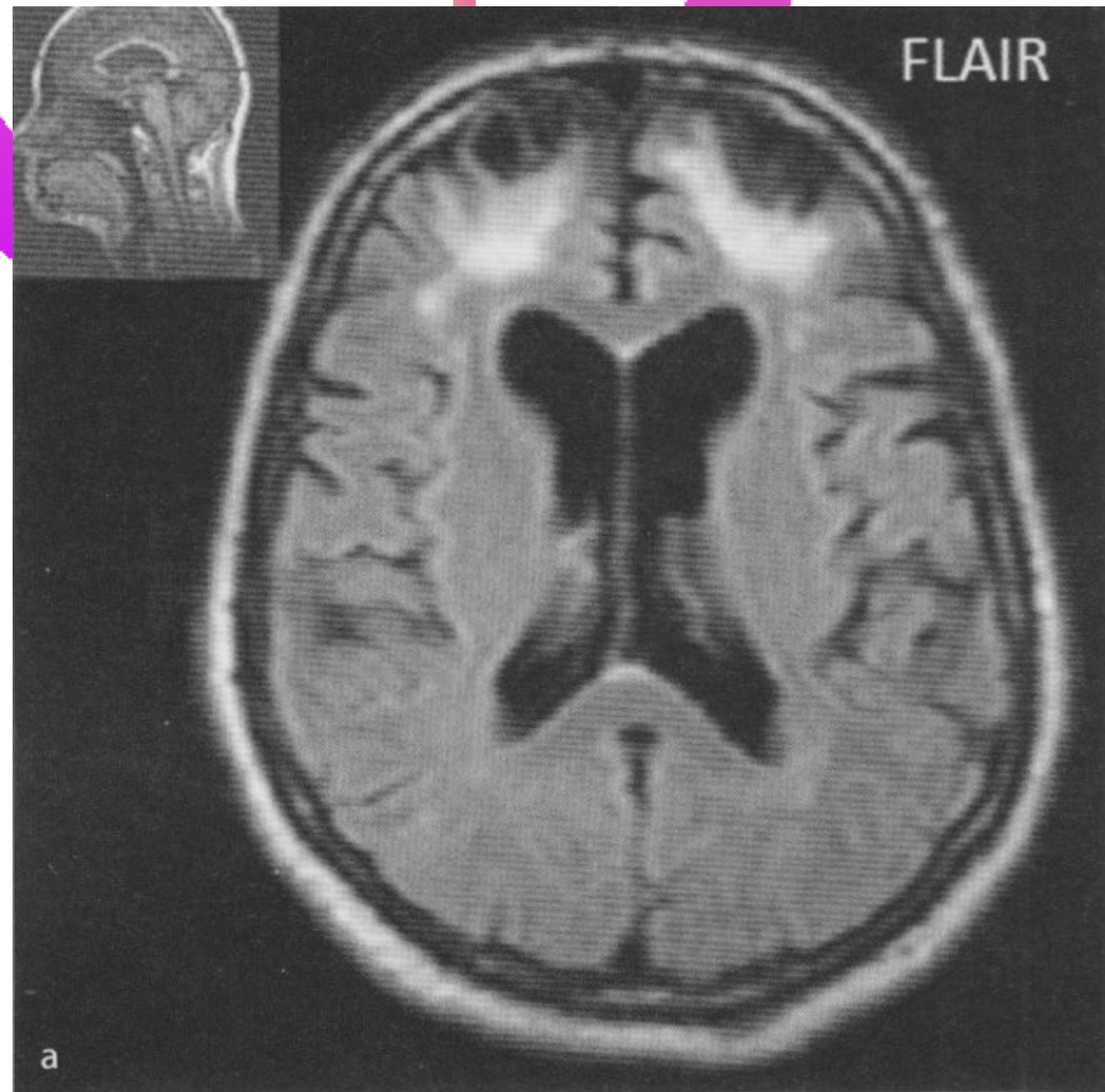
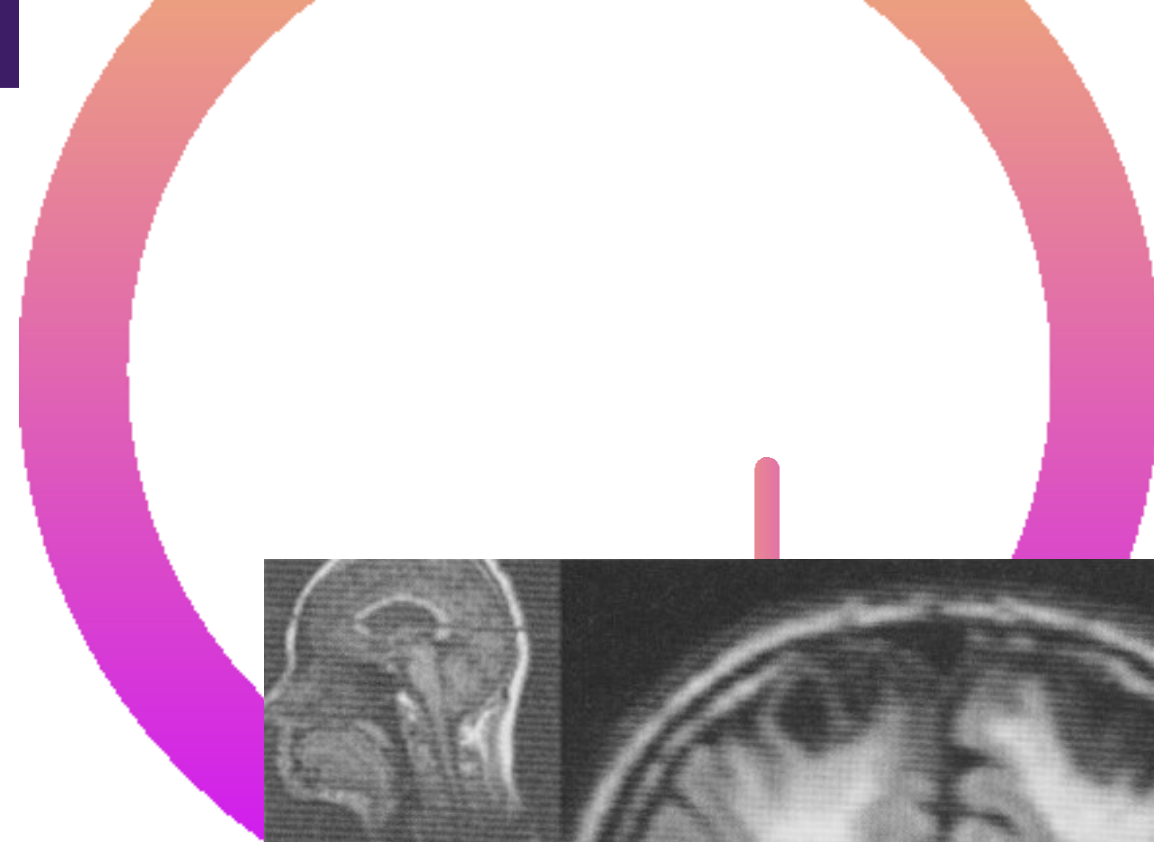


**mozková**



mozku

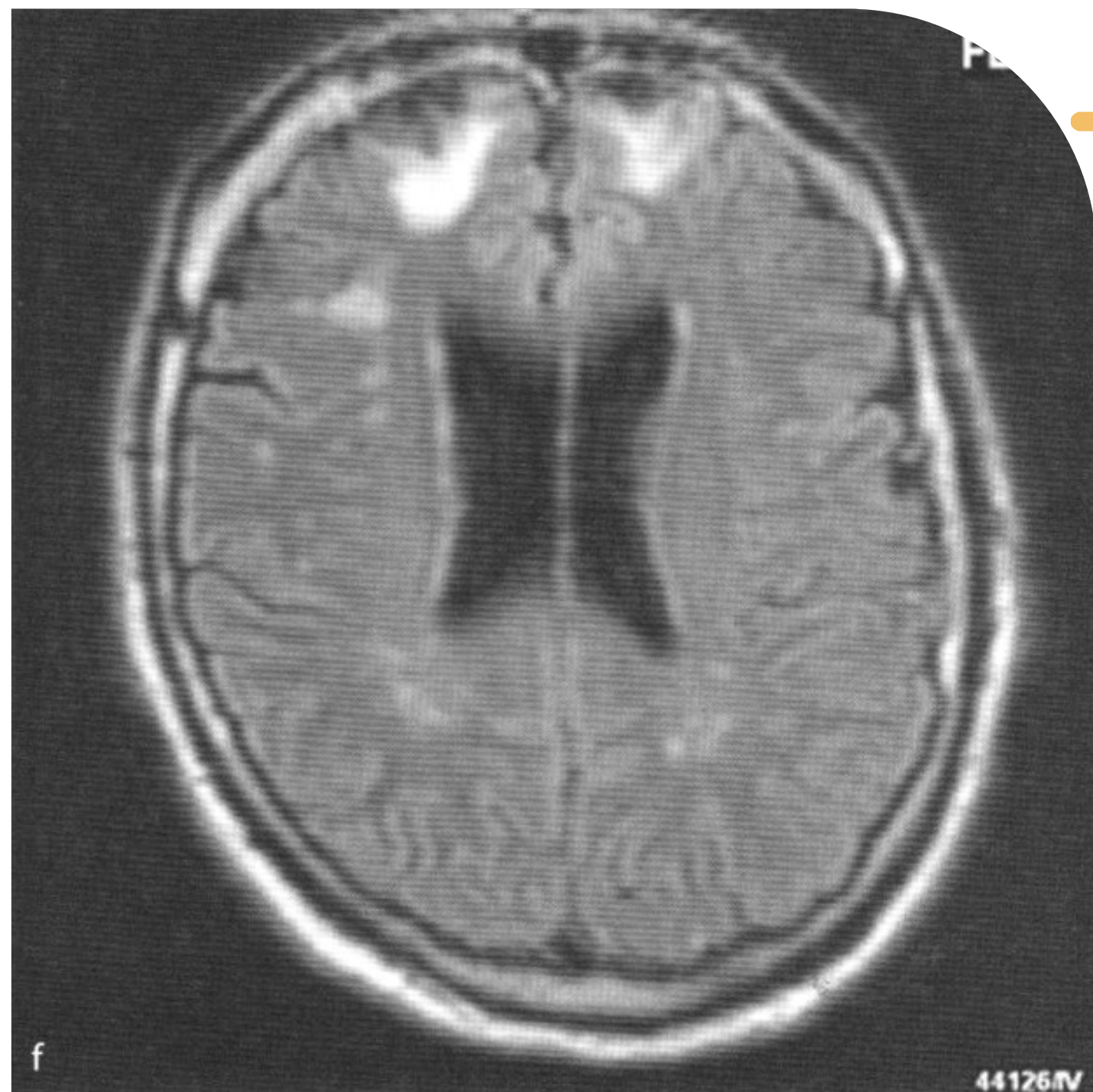




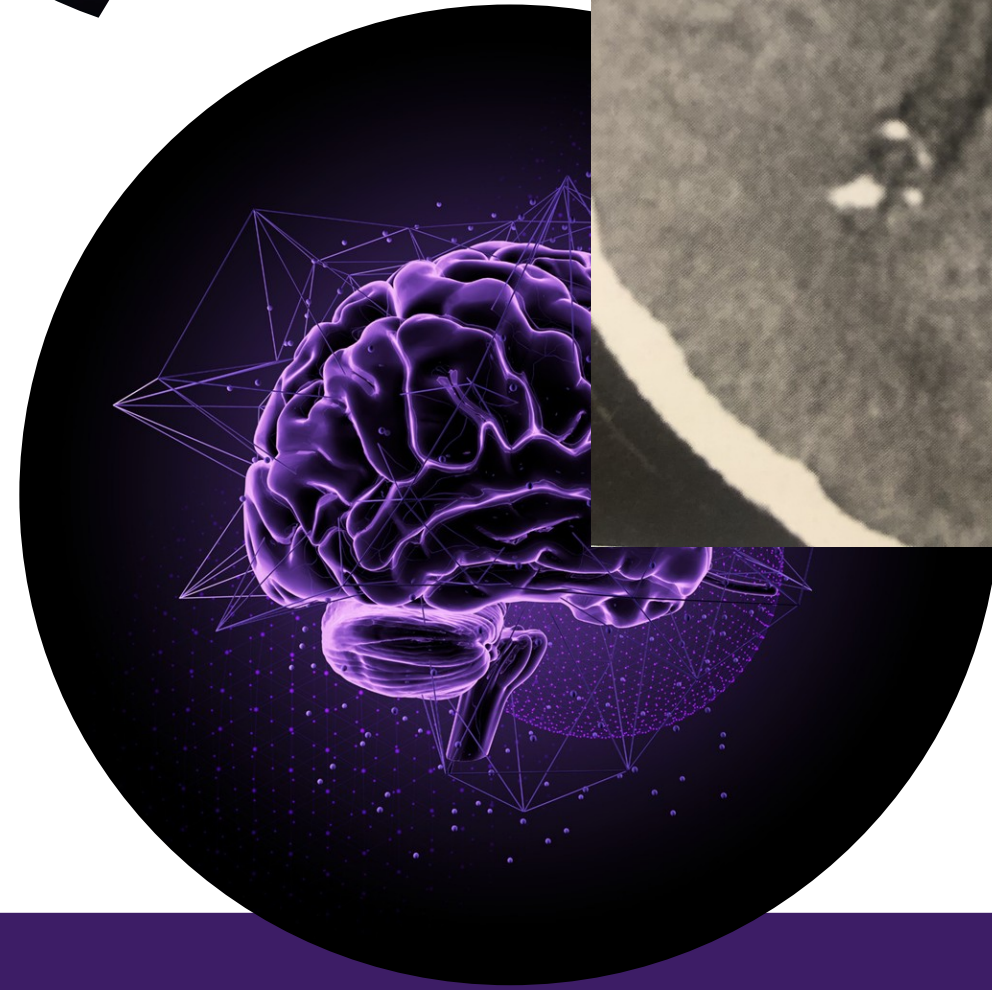
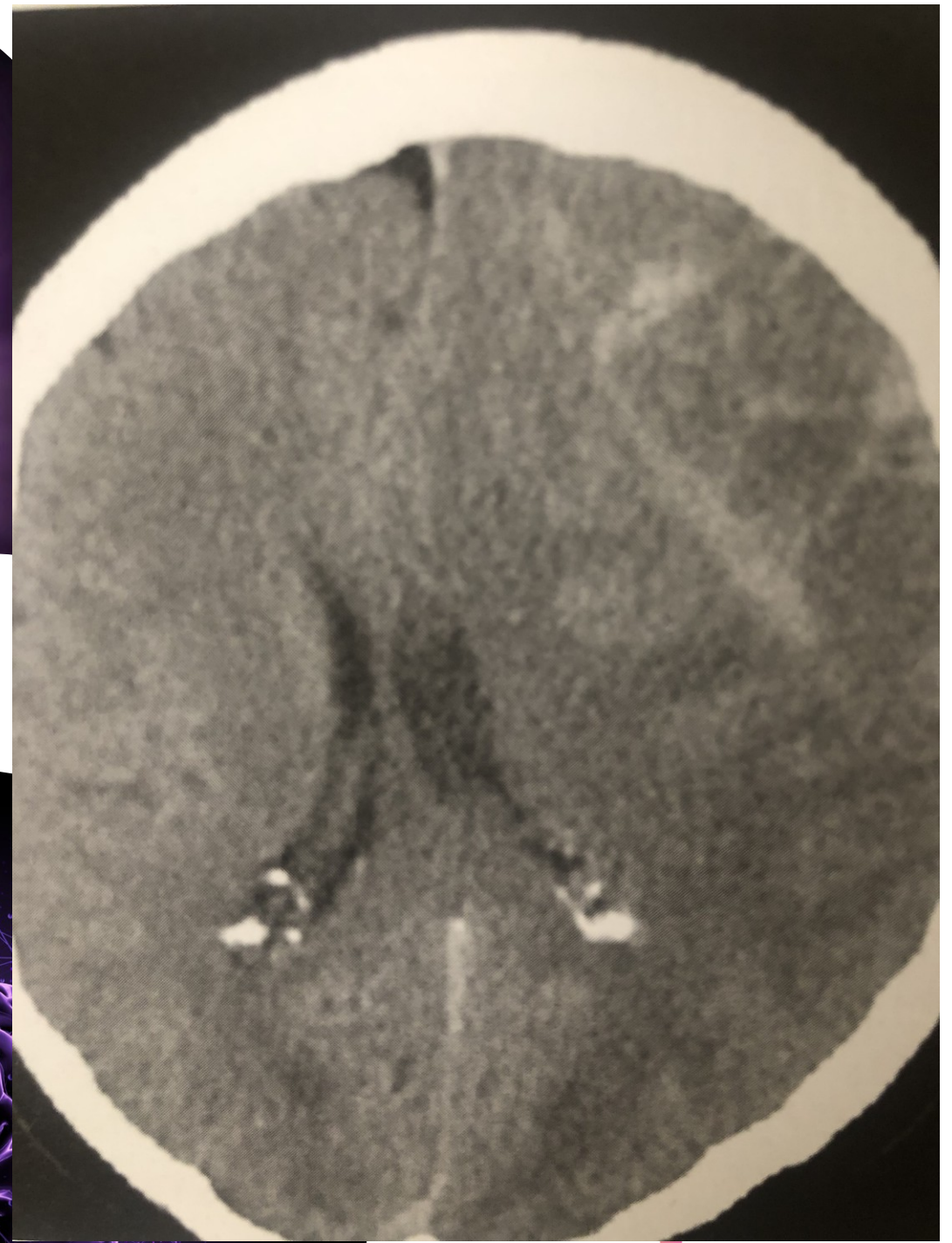


**axonální poranění**





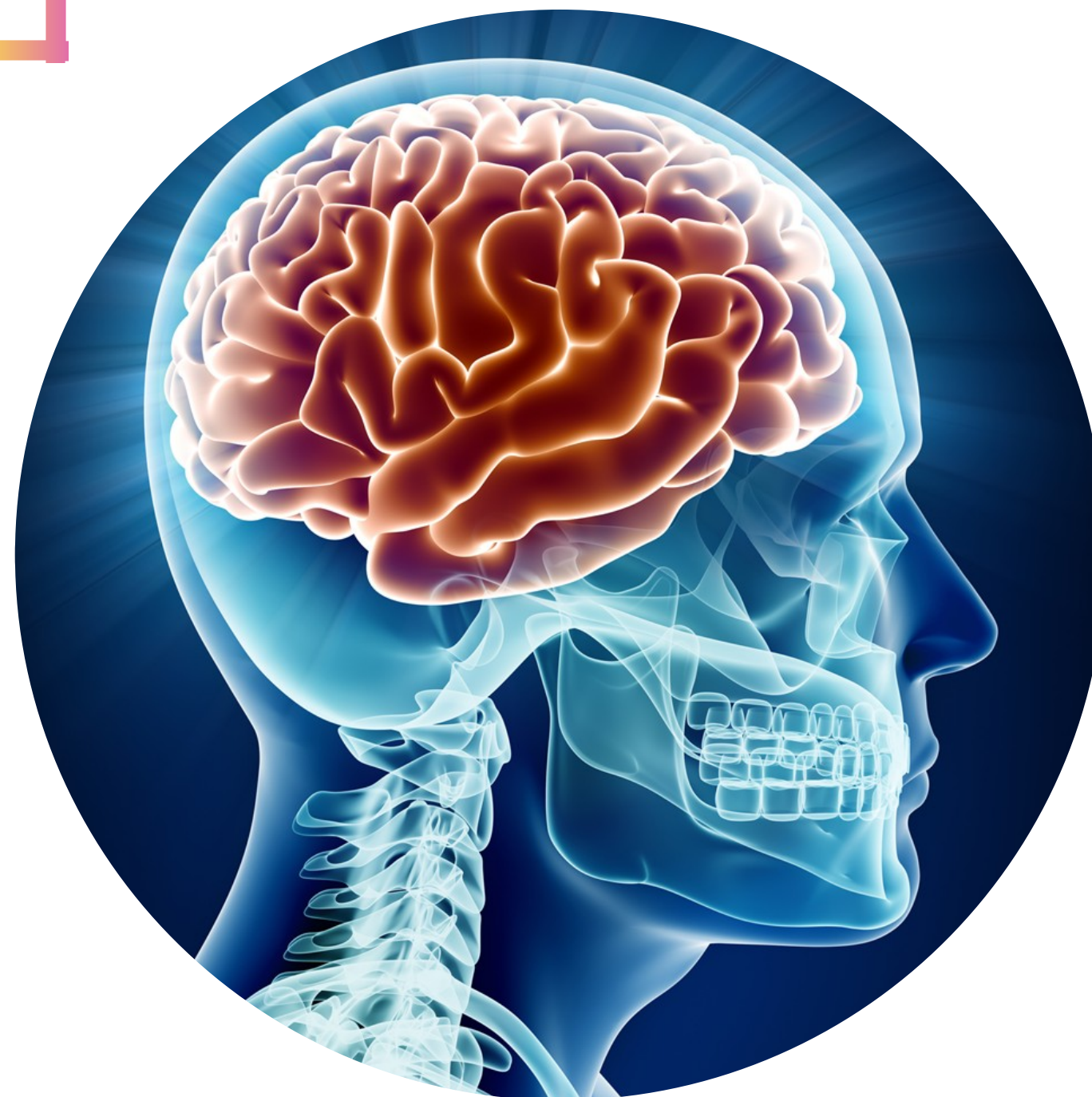**axonální poranění**








# poranění





# týraného dítěte

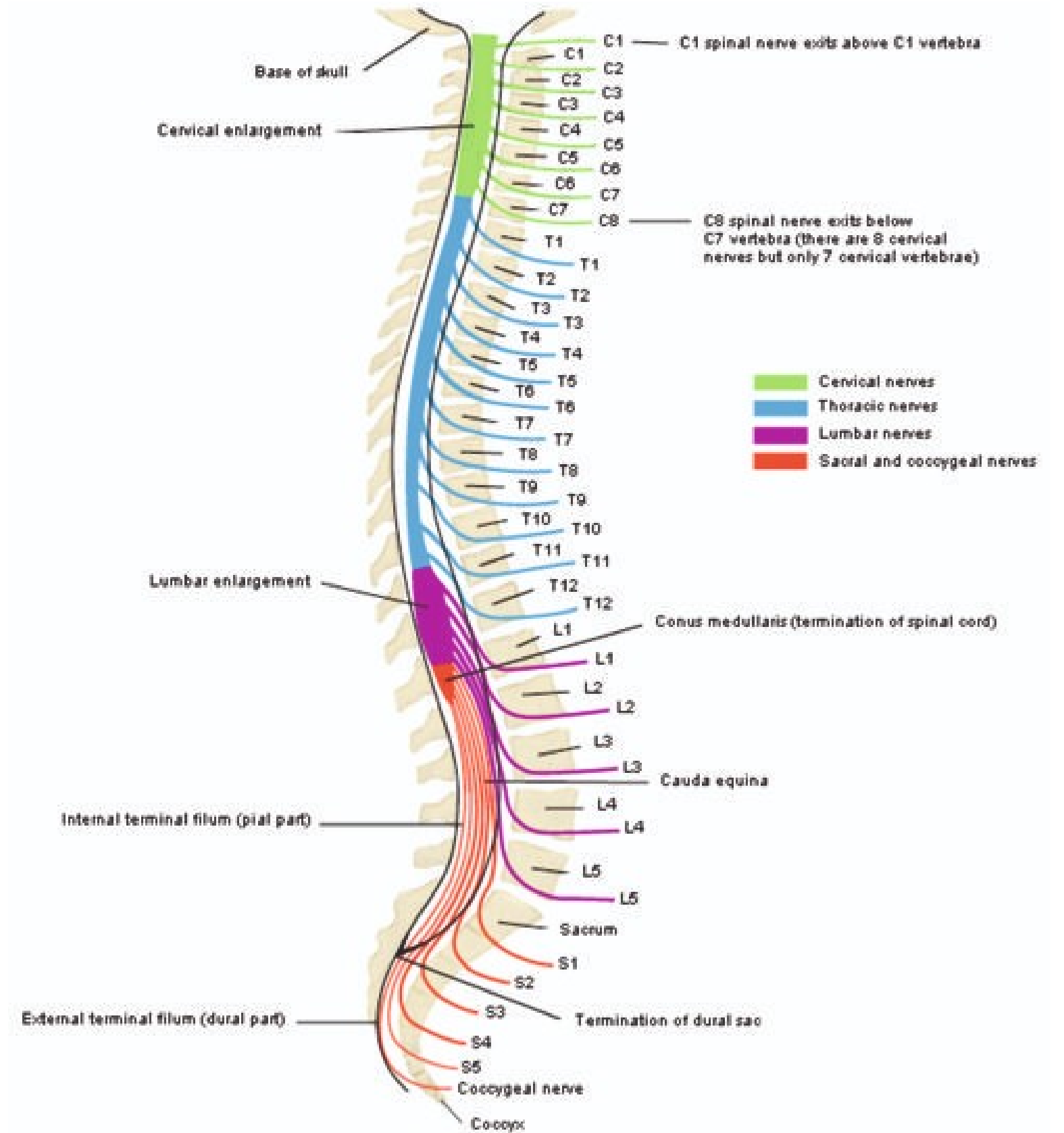


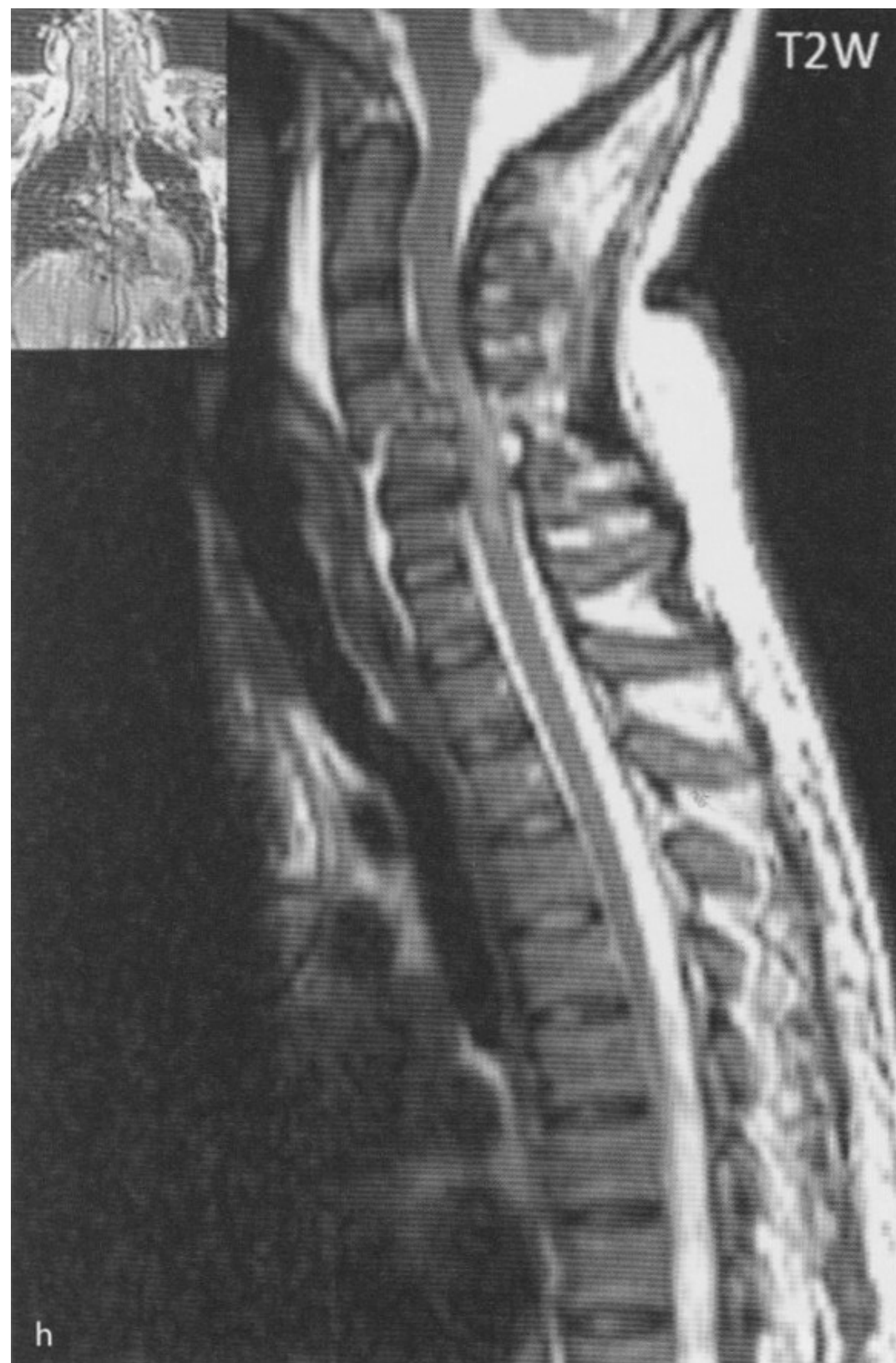


**míchy**



[Seidl Z., Diagnostická radiologie, Grada Publishing, 2014, ISBN 978-80-247-4546-6, str408, obr, II.4.2a](#)



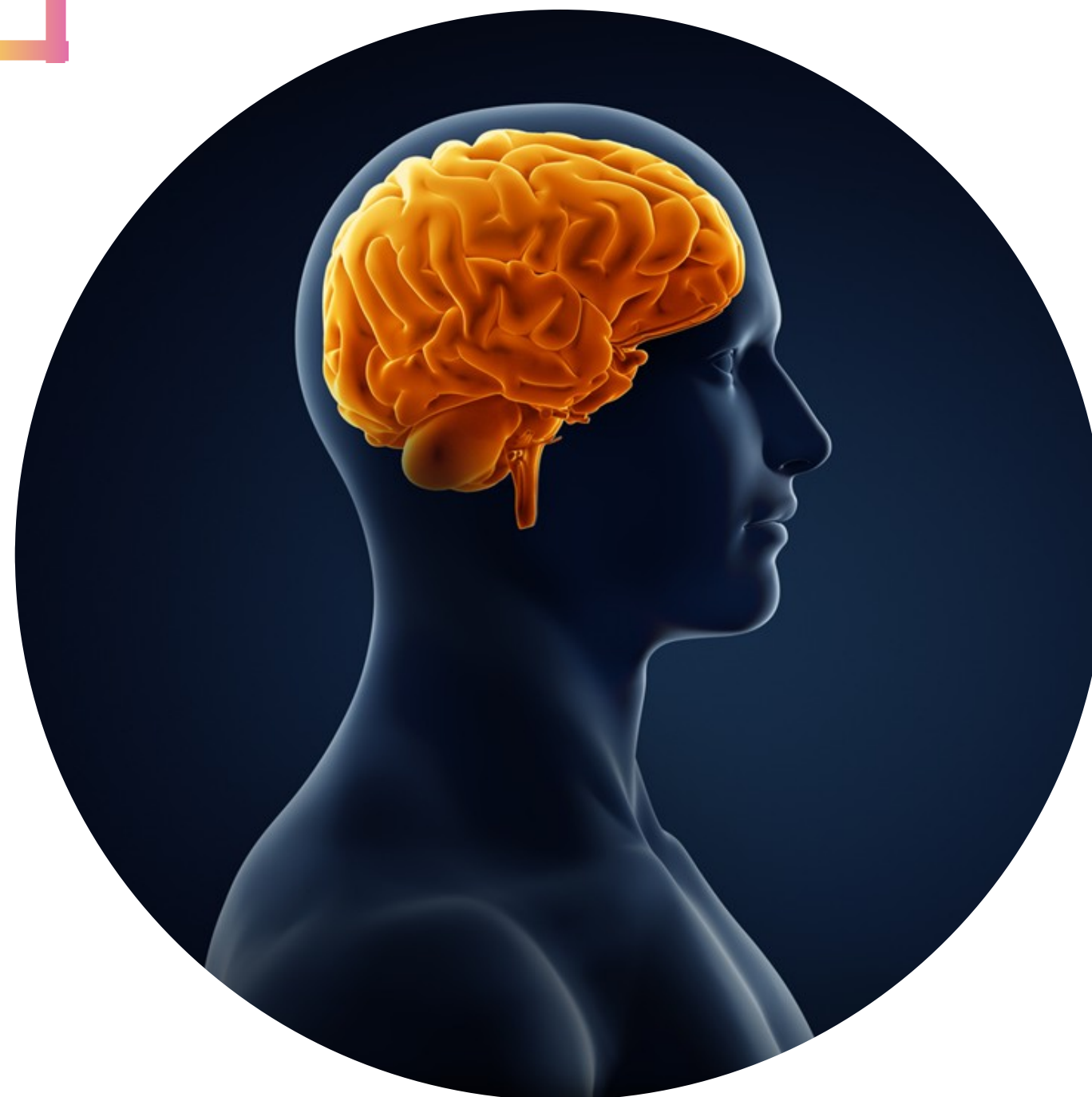


[Seidl Z., Diagnostická radiologie, Grada Publishing, 2014, ISBN 978-80-247-4546-6, str410, obr, II.4.2h](#)





# míšní léze





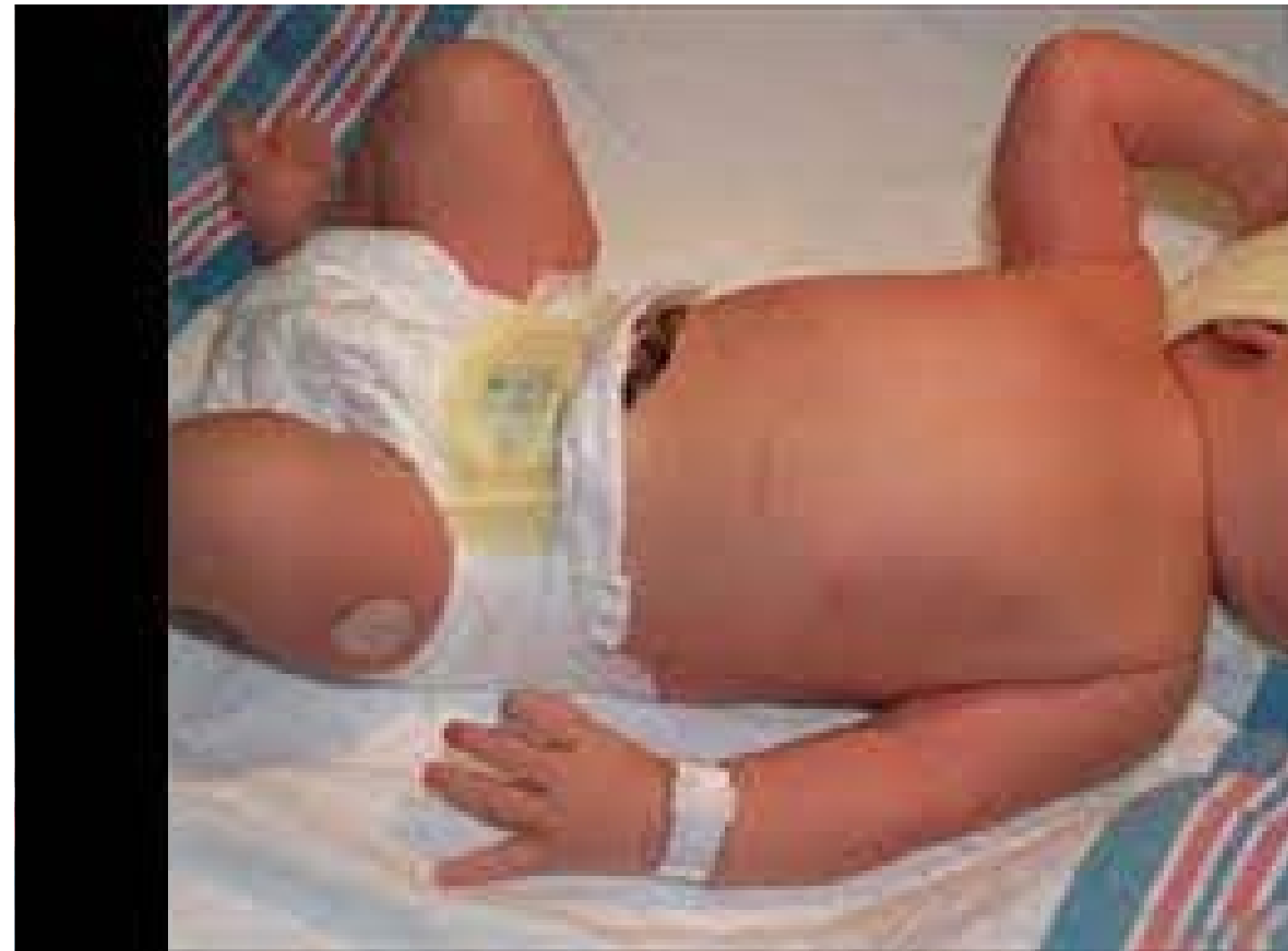
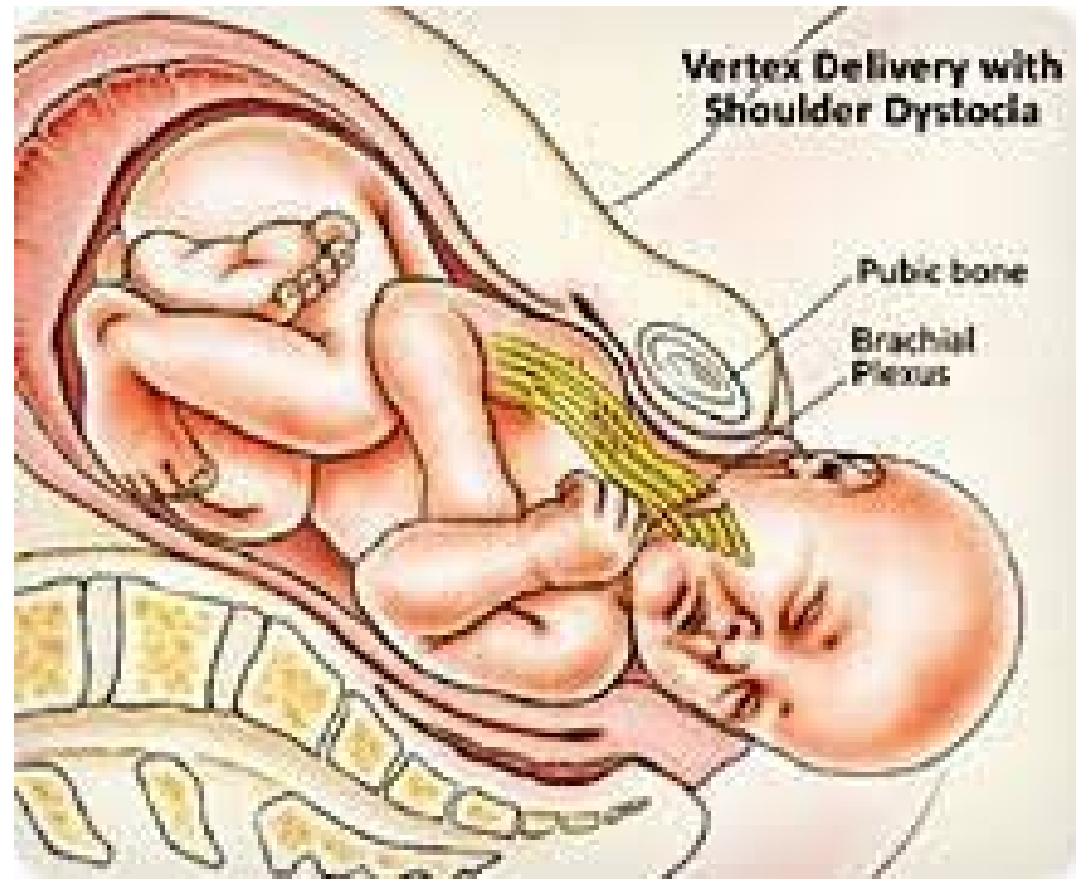






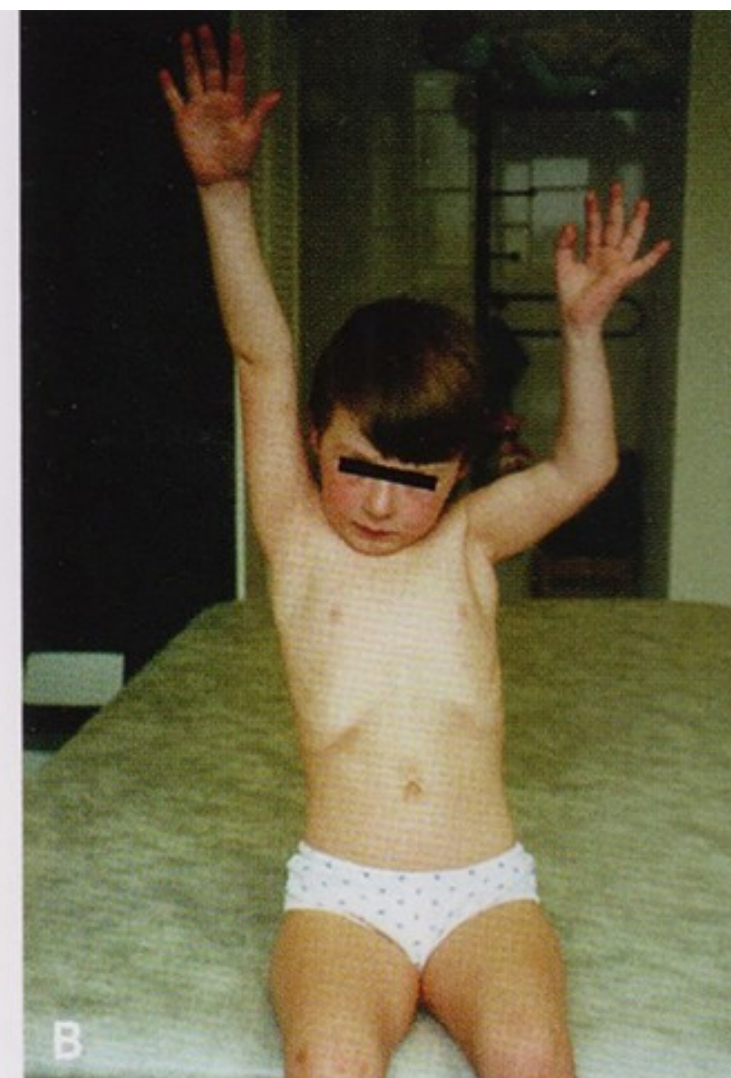
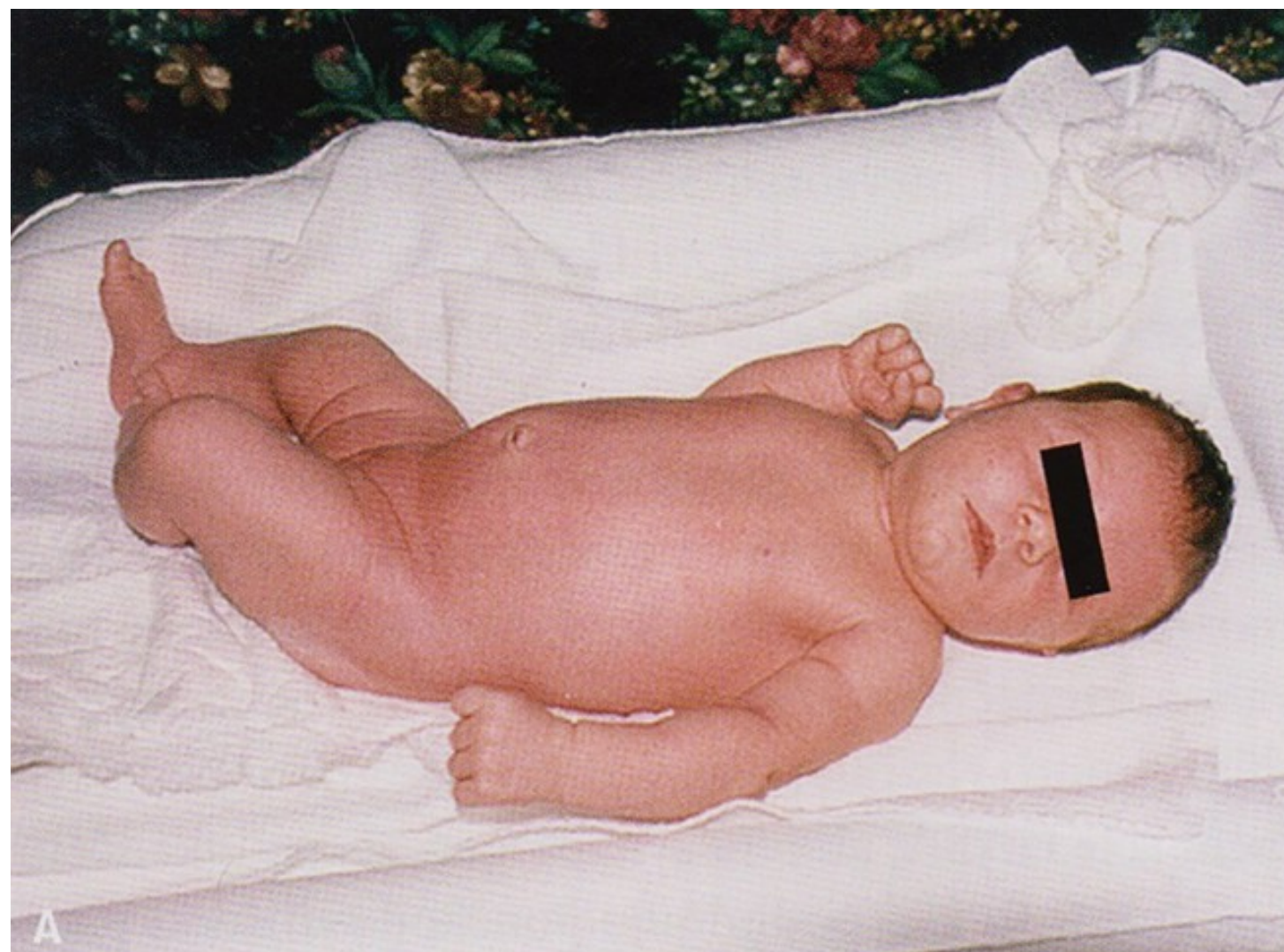**brachiálního plexu**







[Nevšimalová S., Dětská neurologie, Galén 2021, ISBN 978-80-7492-557-3, str 111, obr.3-16](#)



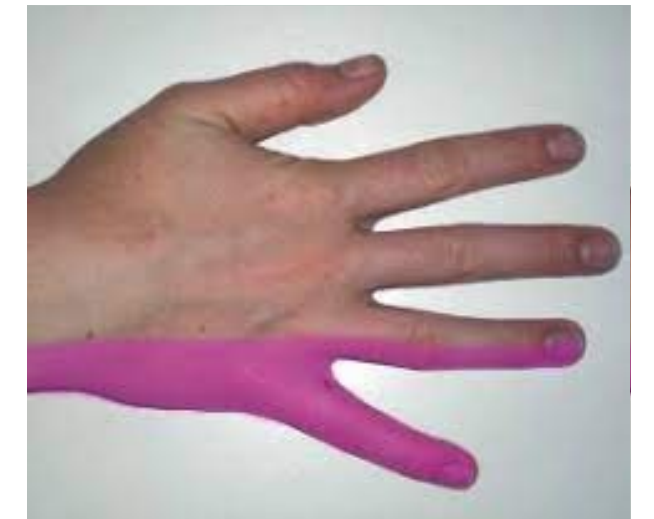
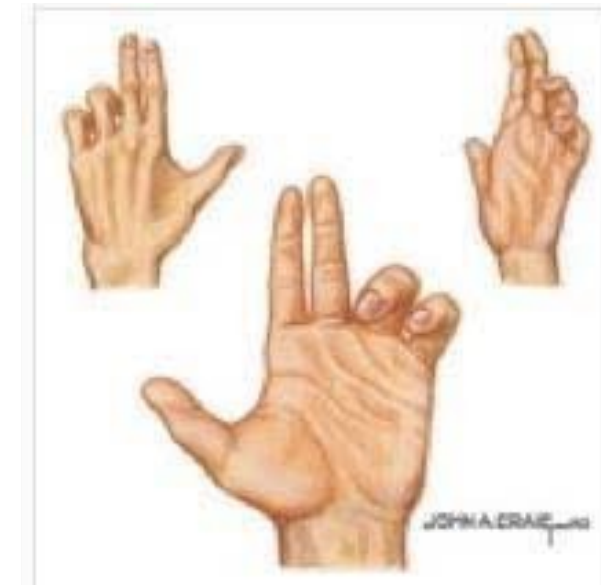
# brachiálního plexu



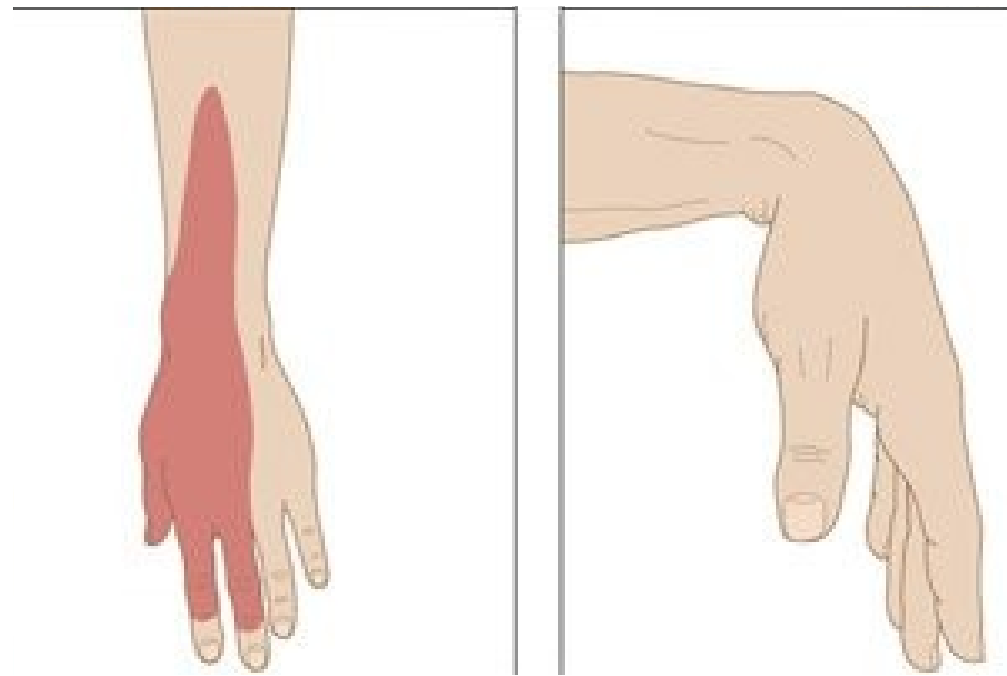


**n. ulnaris**

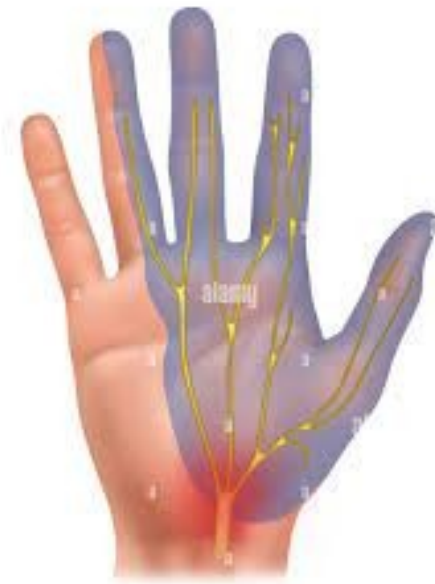



# n. radialis



# n. medianus C5-8, Th1



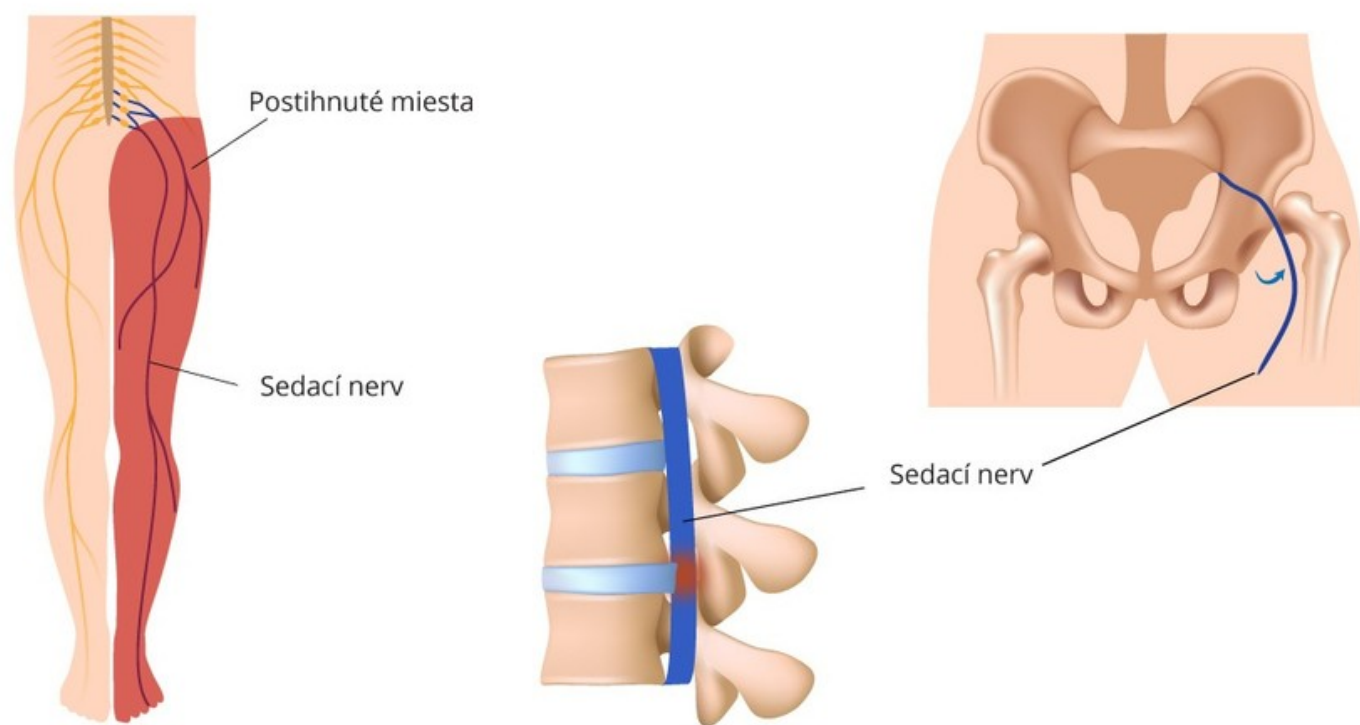
alamy



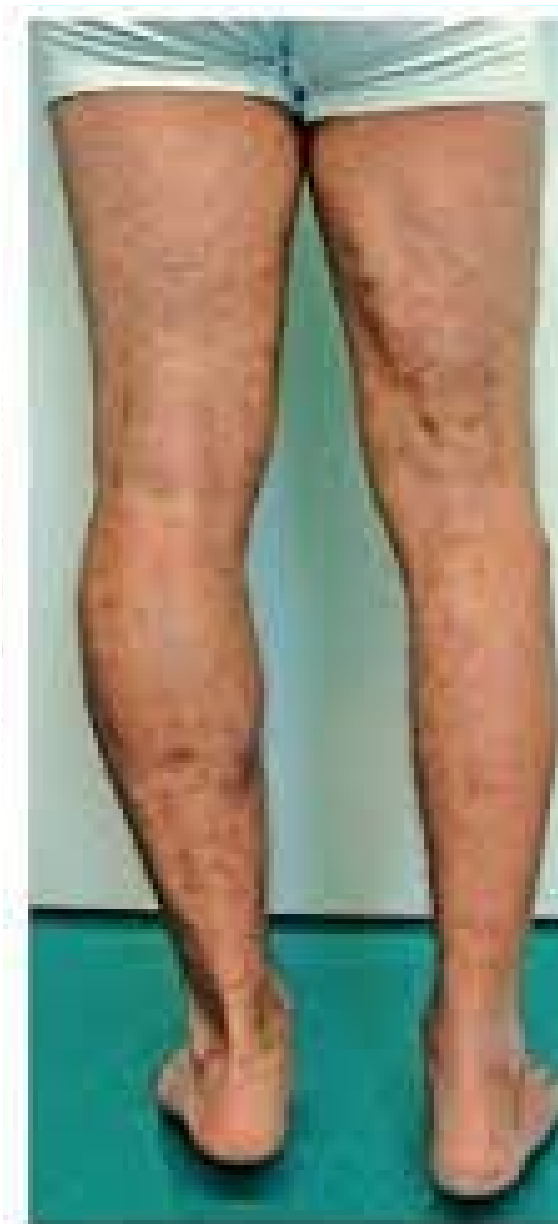

## Špatná volba místa pro injekci do hýždě, porod KP, nehody

### Zápal sedacieho nervu - ischias



symptomy.sk

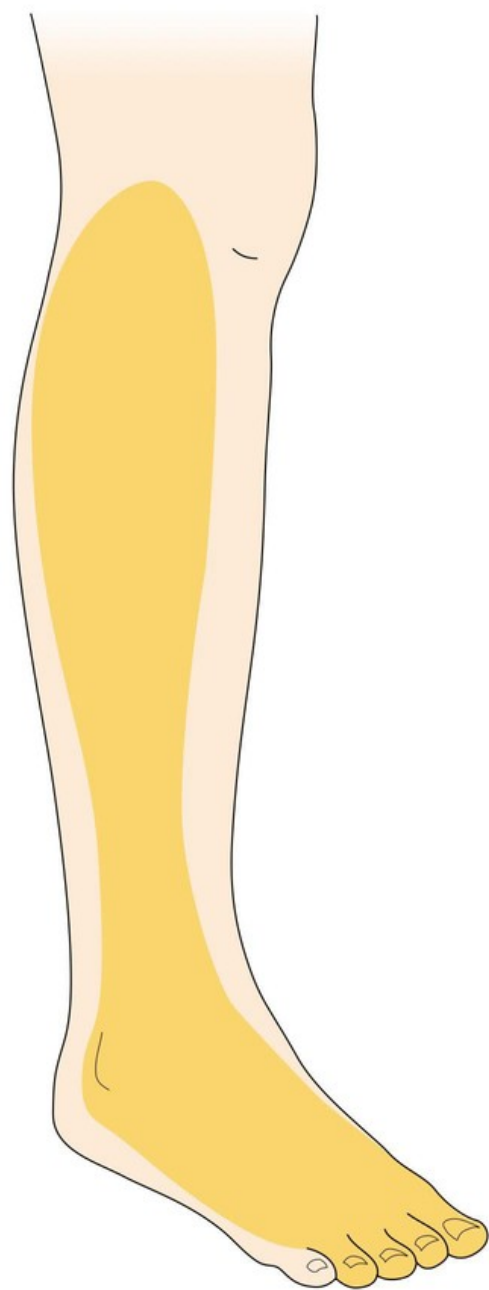


*Obra 1. Pacient z kazuistiky 33 mesiaci po rekonstrukcii NI sprava v úrovni stehna. Pravy bicep hypotrofický, tonus svalstva zachovaný, postaví sa na špičku. Jazyk po revízi patrná na stehne, na oboch lýtkách drobné jazyky po odberoch na nervoch.*





Trauma nervu u hlavičky fibuly , ortopedické výkony v oblasti kolene, inverze nohy v kotníku



© Birgitte Lerche-Barlach 2012

